



# Laparoscopic Partial Nephrectomy

Ender Özden, Hasan Çetin

Ondokuz Mayıs University Faculty of Medicine, Department of Urology, Samsun, Turkey

## ABSTRACT

Patients with renal tumors <7 cm and those at risk for a significant loss of renal function should be managed with a partial nephrectomy if it is technically feasible. Partial nephrectomy (PN) results in similar oncologic outcomes with radical nephrectomy. With advent of the technology and increase utilization of laparoscopic surgery, laparoscopic approach is considered as one of the option for partial nephrectomy. However laparoscopic partial nephrectomy is technically very difficult procedure and should be performed only by physicians with extensive experience using this approach. In this section, we aimed to present the technical steps of laparoscopic partial nephrectomy.

## Key Words

Renal mass, laparoscopy, partial nephrectomy technique

## ÖZET

Yedi cm'den küçük böbrek tümörlerinin tedavisinde, teknik olarak uygunsa, parsiyel nefrektomi tercih edilen cerrahi yaklaşım olarak kabul edilmektedir. Onkolojik sonuçları parsiyel nefrektomi ile radikal nefrektominin benzerdir. Laparoskopik parsiyel nefrektomi, deneyimli ellerde açık parsiyel nefrektomi ile benzer onkolojik sonuçlara sahiptir ancak teknik olarak "çok zor" kabul edilen bir yaklaşımdır. Bu bölümde, uyguladığımız laparoskopik parsiyel nefrektomi tekniğinin aşamalarını paylaşmayı hedefledik.

## Anahtar Kelimeler

Böbrekte kitle, laparoskopi, parsiyel nefrektomi teknik

## Laparoscopic Partial Nephrectomy

Patients with tumors <7 cm and those at risk for a significant loss of renal function should be managed with a partial nephrectomy if it is technically feasible. Partial nephrectomy (PN) results in similar oncologic outcomes compared to radical nephrectomy.

Presuming adequate laparoscopic expertise, Laparoscopic PN (LPN) can provide equivalent oncologic outcome as for open PN albeit with higher urologic complications rate and longer warm ischemia time (WIT). In experienced hands, there is no significant difference in the 5-year survival rate between LPN and OPN (1,2).

In this section of Journal of Urological Surgery, it is aimed to give the technical details of LPN.

## Approach

Both the transperitoneal and retroperitoneal approaches have been used safely and efficiently in LPN. The key factors affecting the choice of approach are the tumor location, history of previous abdominal surgery, and surgeon preference and experience. For the anterior and anterolaterally located tumor, upper pole tumor, transperitoneal approach is preferred whereas retroperitoneal approach will be more appropriate for tumor in the posterolateral or posteromedial aspect of kidney. We usually prefer the transperitoneal approach since it allows us more space and landmarks for orientation.

## Patient Position and Trocar Setup

We use a four-port configuration with the patient in a modified lateral position with a roller under the shoulder and hips. Placing the patient in the lateral decubitus position greatly aids in the dissection by allowing the bowels to fall away from the kidney.

Optic port is usually located to the pararectal area or umbilicus according to patient's body habitus. Twelve mm working port, allows the passage of bulldog clamps, is placed lateral to the rectus abdominis muscle in the midclavicular line, and a 5-mm trocar in the midline between the xyphoid process and the umbilicus on both side, Extra 5 mm port placed to lift the liver up or help in retraction during hilar dissection (Figure 1).

The line of Toldt is incised along a relatively avascular plane to mobilize the bowel. Thermal injury to the bowel is avoided with a dissection at least 1 cm away from the bowel (Figure 2). As the colon is reflected, the plane between anterior Gerota's fascia and the posterior mesocolon is developed (Figure 3). At this position, we see tail of pancreas, vessels of spleen on the left side (Figure 4a), duodenum and vena cava inferior on the right side (Figure 4b). Next, we identify the psoas muscle, along with the overlying ureter, which can be elevated with the lower pole of the kidney. Care should be given to gonadal vein since it can be easily ruptured during retraction (Figure 5).

## Correspondence

Ender Özden MD, Ondokuz Mayıs University Faculty of Medicine, Department of Urology, Samsun, Turkey  
E-mail: ozdemme@yahoo.com

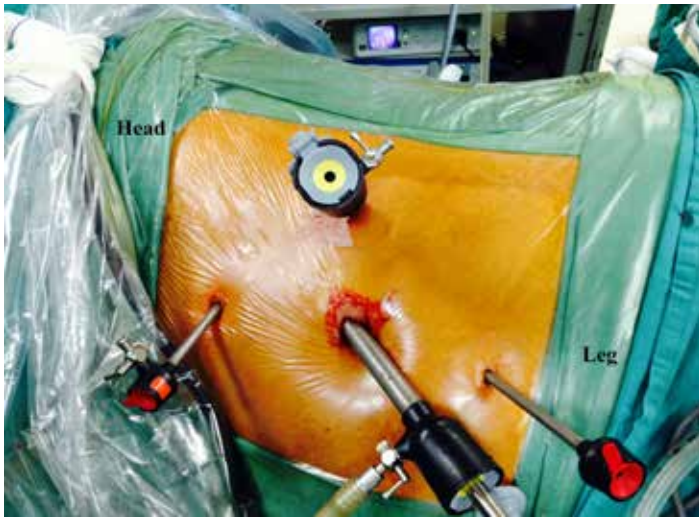


Figure 1. Port configuration for the left-sided partial nephrectomy

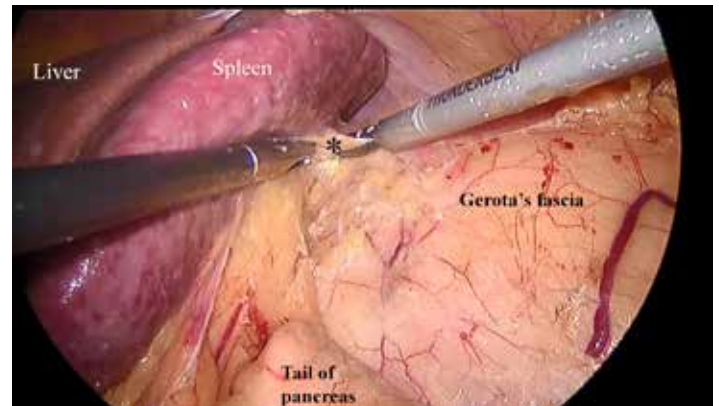


Figure 4A. Dissection plane between Gerota's fascia and spleen and tail of pancreas on the left side. \*: Lienorenal ligament

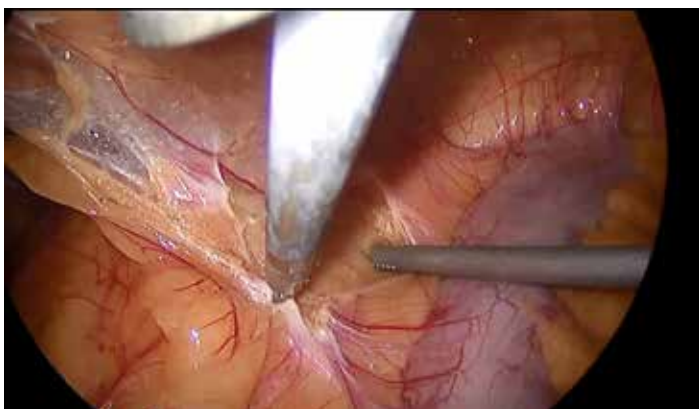

Figure 2. Incision of the line of Toldt

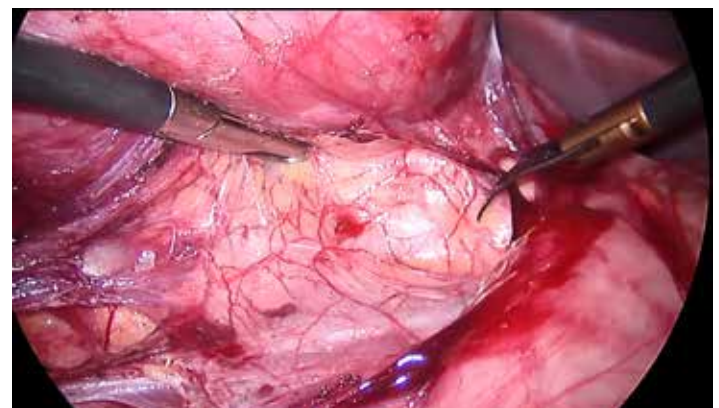


Figure 4B. Duodenum is medialized and inferior vena cava is exposed on the right side

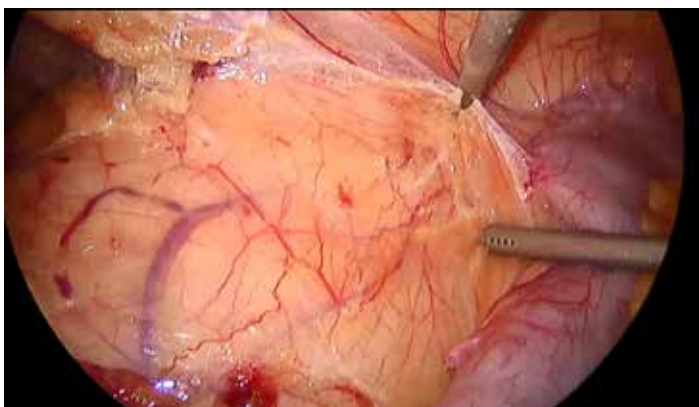


Figure 3. Dissection between Gerota's fascia and mesocolon

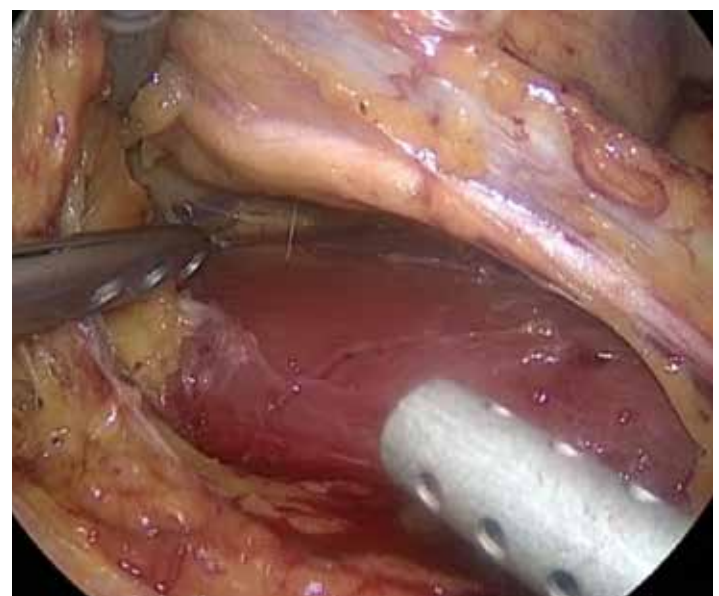


Figure 5. Psoas muscle and elevated ureter and gonadal vein on the left side

Renal artery and vein are dissected and secured with vascular tape to the extent that a bulldog clamp can be placed easily when needed (Figure 6a). At this point, we give 12.5 grams of mannitol to patient, in order to create an osmotic diuresis to minimize reperfusion injury and acute tubular necrosis. Especially in cases with central mass, segmental branches of artery and vein can be dissected and clamped to avoid the global renal ischemia (Figure 6b).

We do not obtain CT angiography before LPN routinely, but rather rely on the contrast enhanced CT or MRI in both axial and coronal reconstruction views to assess renal artery and vein (Figure 7).



Release of Gerota's fascia is then carried out to isolate the renal mass. If the patient has a posterior mass, then the entire kidney is mobilized in order to gain exposure and optimize visualization for subsequent reconstruction.

Actually release of Gerota's fascia is the key step that determines the surgical time. Because in some instances, "sticky fat" or "bad fat" has been encountered and dissection of perinephric fat tissue can be really a big problem to deal with. Use of laparoscopic ultrasound probe may facilitate the proper location of mass and plane of parenchymal dissection, preventing violation of the tumor capsule and delineation of margins (Figure 8).

Margin of the tumor is scored by hook cautery. Scoring of the renal capsule creates a groove circumferentially to cut the capsule and parenchyma by cold scissor (Figure 9).

After scoring of mass, sutures are placed into abdominal cavity and bulldog clamps are placed. We usually place clamps on both artery and vein (Figure 10). WIT should be kept to the minimum. Ideally WIT should be less than 20 minutes (3).

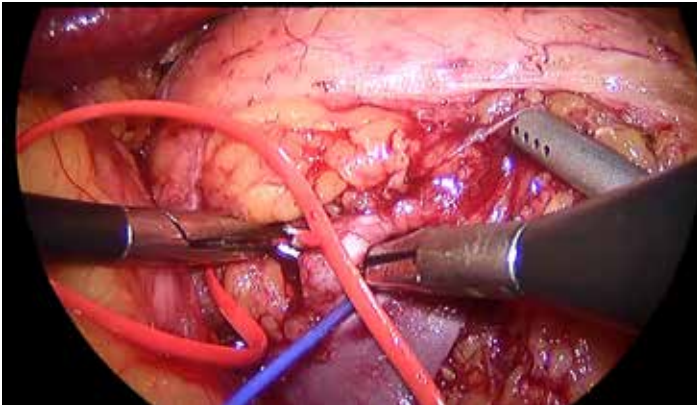


Figure 6A. Renal artery and vein released from the surrounding tissues

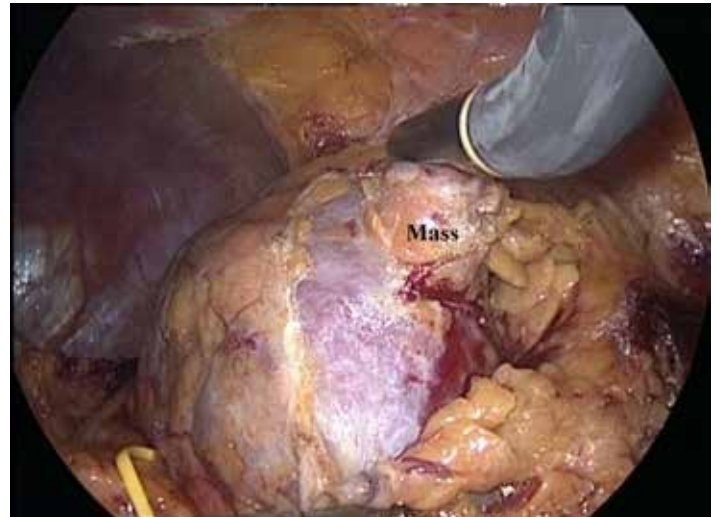

Figure 8. Intraoperative US for the detection of mass and safe surgical margin

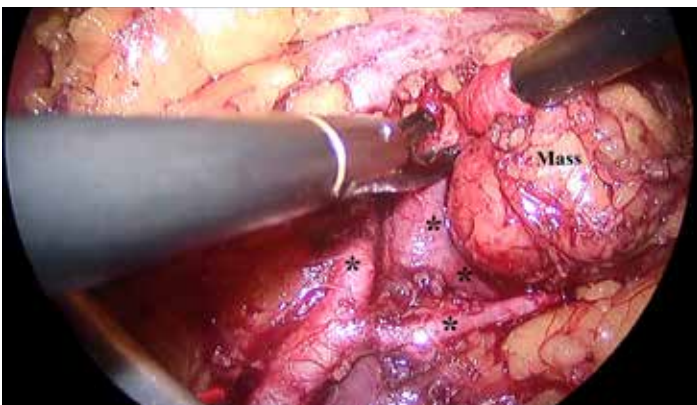


Figure 6B. Dissection of segmental branches of renal vein\* and artery\*.

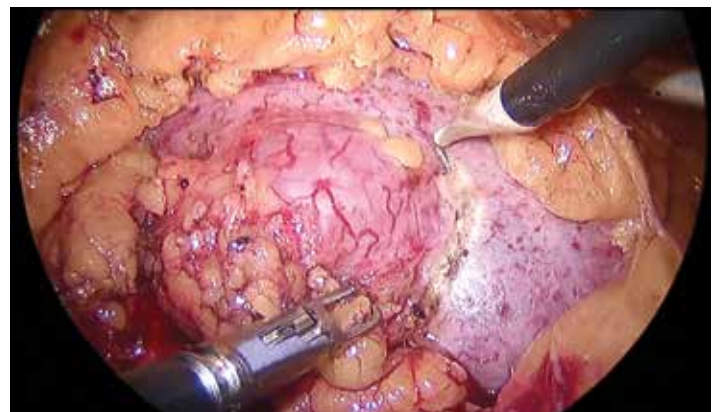


Figure 9. Scoring of the surgical margin with hook cautery

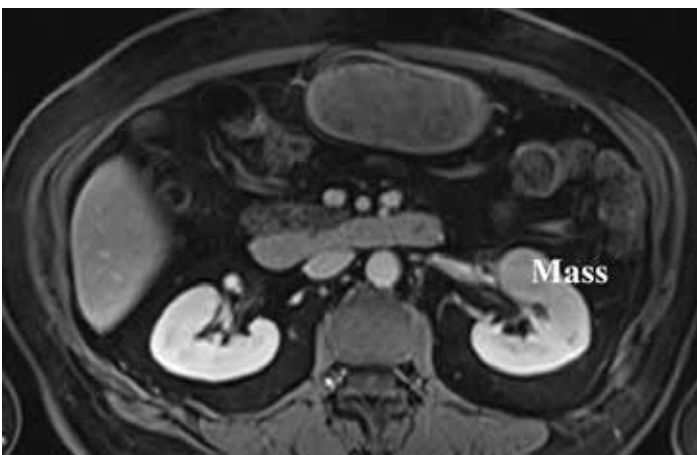


Figure 7. Magnetic resonance image of left renal mass

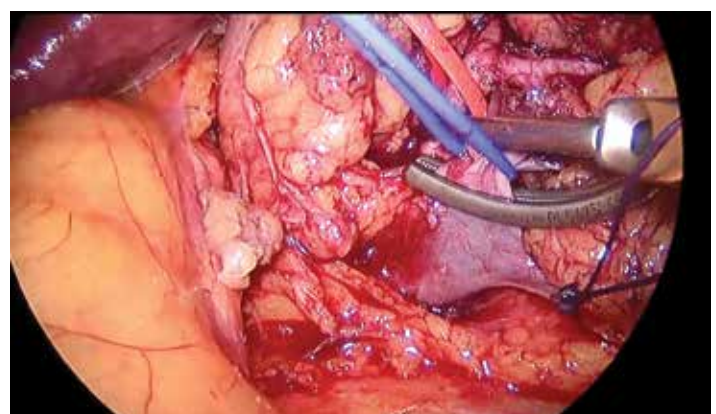


Figure 10. Placement of bulldog clamp on renal artery and vein



The tumor is resected with cold scissors, tips pointed outward, in order to avoid from tumor capsule and to develop the groove circumferentially. The surgeon utilizes the suction to give counter traction on the edge of the resection margin and to keep the resection field bloodless (Figure 11). At the same time, assistant creates space between mass and renal parenchyma by lifting up the mass or pushing down the lower pole of kidney. In the procedure, the cold scissor tips are turned away from the mass during resection. We do not take tissue sample from the resection site for frozen section.

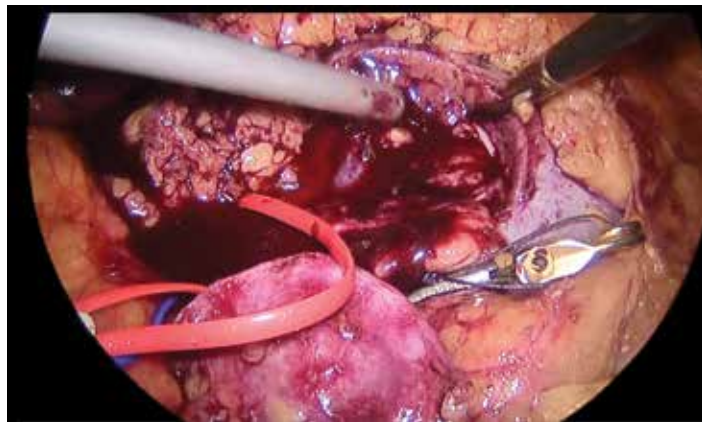

Figure 11. Resection of tumor with cold scissors

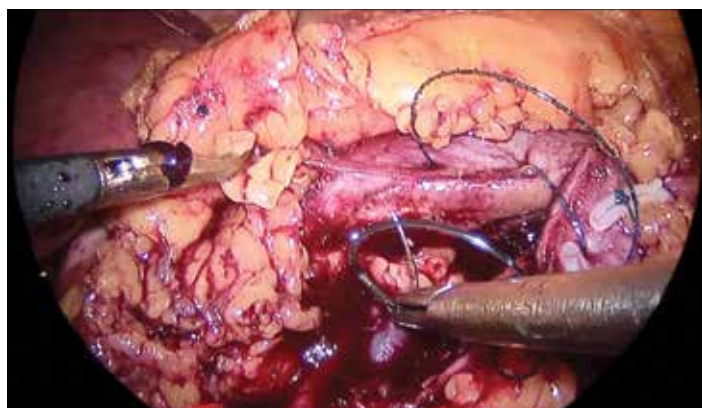

Figure 12. Closure of defect with v-Loc suture

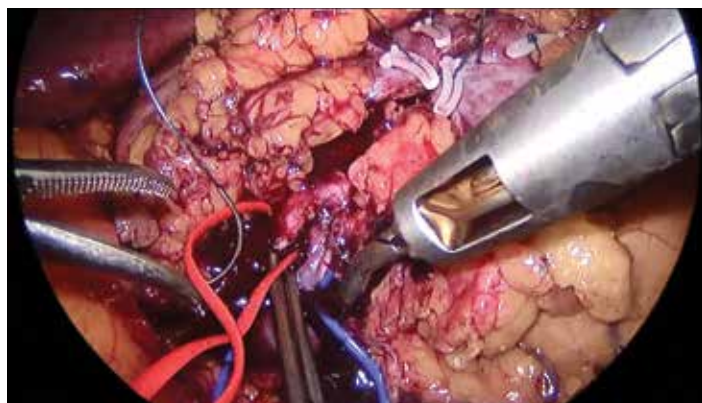

Figure 13. Removal of bulldog clamps

## Closure of Collecting System and Base of Resection Site

After resection of the mass, the collecting system is closed with a running 2-0 V-Loc suture with a Hem-o-lok clip on the end. This step also aids in initial hemostasis by addressing the segmental renal artery branches and helps minimize development of pseudoaneurysm postoperatively. We do not use bolster or hemostatic agent over the resection site (Figure 12).

Once adequate hemostasis is obtained, the lower pole of the kidney is retracted and the bulldog clamps are released by aligning the base of the clamps with the bulldog remover (Figure 13). Visual inspection of the resection site is carried out for adequate hemostasis, as well as checking with the anesthesiologist that the blood pressure has returned to preoperative levels.

Finally, Gerota's fascia is closed over the resection area (Figure 14), and the specimen is placed within an entrapment bag. Drain is placed to the surgical field (Figure 15).

The main advantage of laparoscopic approach is to provide a faster recovery, less blood loss, less postoperative pain, and shorter hospital stay compared with open surgery.

However laparoscopic partial nephrectomy is technically very difficult procedure and should be performed only by physicians with extensive experience using this approach. Careful selection and experience have the utmost importance for LPN.

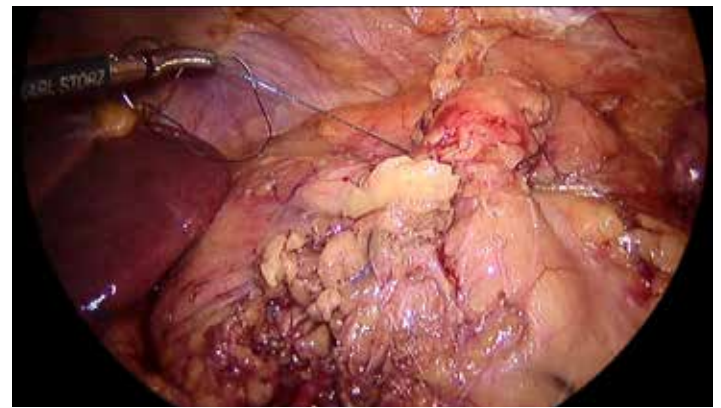


Figure 14. Closure of Gerota's fascia over resected area

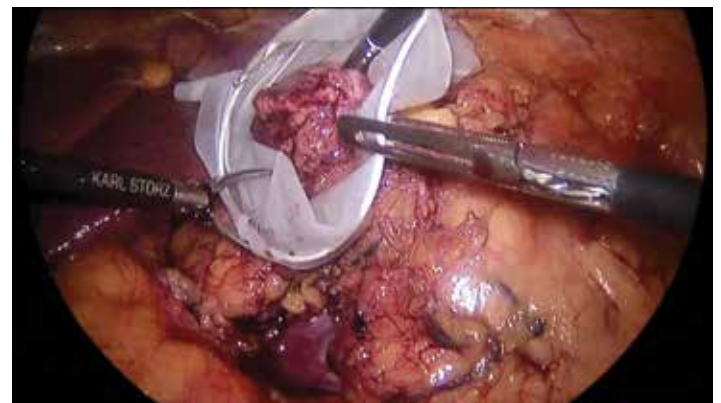


Figure 15. Placement of specimen into the endobag

## References

1. Permpongkosol S, Bagga HS, Romero FR, Sroka M, Jarrett TW, Kavoussi LR. Laparoscopic versus open partial nephrectomy for the treatment of pathologic T1N0M0 renal cell carcinoma: A 5-year survival rate. *J Urol* 2006;176:1984-1988; discussion 1988-1989.
2. Marszalek M, Meixl H, Polajnar M, Rauchenwald M, Jeschke K, Madersbacher S. Laparoscopic and open partial nephrectomy: A matched-pair comparison of 200 patients. *Eur Urol* 2009;55:1171-1178.
3. Thompson RH, Lane BR, Lohse CM, Leibovich BC, Fergany A, Frank I, Gill IS, Blute ML, Campbell SC. Every minute counts when the renal hilum is clamped during partial nephrectomy. *Eur Urol* 2010;58:340-345.