



Giant Macular Hole Formation After Scleral Buckling and Vitrectomy Surgery

Skleral Çevreleme ve Vitrektomi Cerrahisi Sonrası Dev Makula Deliği Gelişimi

Mehmet Özgür Zengin, Esat Çınar, Cem Küçükerdönmez
İzmir University Faculty of Medicine, Department of Ophthalmology, İzmir, Turkey

Summary

Macular holes can develop secondary to pars plana vitrectomy (PPV). We report a case with giant macular hole formation after PPV and scleral buckling. A 66-year-old woman with a history of vitrectomy and scleral buckling due to rhegmatogenous retinal detachment (RRD) in her right eye 5 years ago complained of decrease in visual acuity ever since. Clinical photographs, fluorescein angiography and optic coherent tomography images revealed a very large macular hole of approximately 2465 µm in diameter. This case is an uncommonly large variant of a macular hole secondary to retinal detachment surgery. (Turk J Ophthalmol 2015; 45: 79-80)

Key Words: Rhegmatogenous retinal detachment, giant macular hole, decreased vision

Özet

Makula delikleri pars plana vitrektomi (PPV) sonrasında gelişebilmektedir. Bu yazıda skleral çevreleme ile birlikte PPV yapılan bir olguda cerrahi sonrası dev makula deliği gelişimi irdelenmiştir. Altmış altı yaşındaki bayan hasta sağ gözünden beş yıl önce yırtıklı retina dekolmanı nedeniyle skleral çevreleme ve PPV operasyonu geçirmiştir. O tarihten itibaren görme azlığı tariflemektedir. Klinik fotoğraflar, flöresein anjiyografi ve optik koherens tomografi görüntülerinde çapı 2465 mikron olan dev makula deliği izlenmektedir. Bu olgu, retina dekolman cerrahisi sonucu nadir görülen bir dev makula deliği olgusudur. (Turk J Ophthalmol 2015; 45: 79-80)

Anahtar Kelimeler: Yırtıklı retina dekolmanı, dev makula deliği, görme azlığı

Introduction

Idiopathic macular holes (MH) are caused by tangential traction as well as anterior posterior traction of the posterior hyaloids on the parafovea.^{1,2} The size of these holes may vary, although those that exceed 1.500 µm in diameter are very rare.³ This has been supported by histopathological studies and optical coherence tomography (OCT) images.^{4,5} However, even after pars plana vitrectomy (PPV) with removal of all tractions, MH can develop in several diseases.⁶ Giant MH can occur in Alport syndrome and Best's disease.^{7,8} We hereby report the case of a patient in whom giant MH developed after PPV and scleral buckling for rhegmatogenous retinal detachment (RRD) repair.

Case Report

A 66-year-old female patient had a 5-year history of scleral buckling and PPV due to RRD in her right eye. No other intercurrent systemic or chronic ocular disease was reported by

the patient. The best-corrected visual acuity was 5/400 in the right eye and 10/20 in the left eye. The intraocular pressure was 16 mmHg in both eyes. The right eye was pseudophakic, and the left eye had grade II nuclear sclerosis. In the posterior pole of the right eye, a MH that was larger than one disc diameter was documented (Figure 1). OCT showed the presence of a full-thickness MH approximately 2465 µm in diameter (Figure 2).

Discussion

MH secondary to trauma may occur at any age. It is most often seen in male patients between the 2nd and 4th decade of life. The development of a MH after RRD repair is a rare occurrence with a prevalence of between 0.5 and 2.0% in the literature.^{9,10,11} MH develops most often in eyes that had undergone scleral buckling for the RRD.^{9,11,12} Our case underwent scleral buckling and PPV at the same session and developed a MH. Glial migration and proliferation followed by the contraction

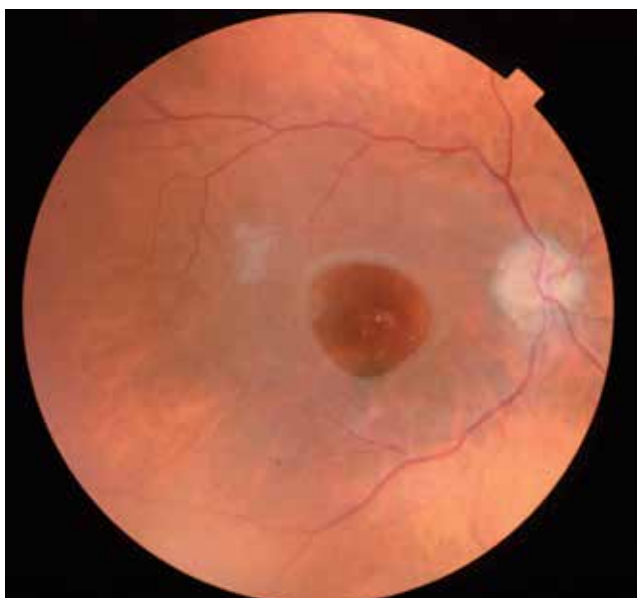


Figure 1. Clinical picture of the macular hole

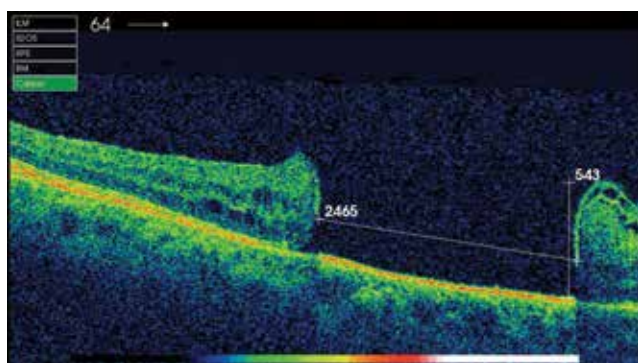


Figure 2. OCT linear scan image showing the size (2465 and 956;μm) and full thickness of the macular hole

of glial plaques or secondary membrane formation surrounding the MH is associated with the development of a MH after PPV.⁶ Surgical procedures to remove the ILM can eliminate the glial plaques or secondary membrane formation. The formation of a MH by the contraction of this plaques or membrane probably requires a longer time without vitreomacular traction. During this period, the atrophic changes of the macula may proceed.

The diameter of most holes tends to be between 400 and 750 μm in stage 4 macular holes, but Sjaarda and Thompson³ have reported extreme diameters of 300-1500 μm.

Macular holes larger than 1500 μm are very rare and might be referred to as giant macular holes. These larger macular holes are more often attributed to blunt trauma than to other clinical entities, but associations with other conditions, e.g. Alport's disease,⁸ have been reported.

In our patient, the decision not to operate was based on the long duration of the hole's presence, the extensive atrophy of the retinal pigment epithelium (extending even beyond the edges), and the large size of the hole. These factors indicated a low likelihood of successful closure.¹³ In addition, the patient declined to undergo surgery because of the poor outlook for anatomical and functional improvement.

To the best of our knowledge, in the literature, this is the largest macular hole which developed secondary to surgery without any systemic or ocular disease association.

Conflict of Interest: The authors reported no conflict of interest related to this article.

References

- Gass JD. Idiopathic senile macular hole. Its early stages and pathogenesis. *Arch Ophthalmol.* 1988;106:629-639.
- Johnson RN, Gass JD. Idiopathic macular holes. Observation, stages of formation, and implications for surgical intervention. *Ophthalmology.* 1988;95:917-924.
- Sjaarda RN, Thompson JT. Macular hole; in Wilkinson CP (ed): *Ryan's Retina.* St. Louis, Mosby-Elsevier; 2006: 2527-2544.
- Guyon DR, Green WR, de Bustros S, Fine SL. Histopathologic features of idiopathic macular holes and cysts. *Ophthalmology.* 1990;97:1045-1051.
- Altaweel M, Ip mM. Macular hole: improved understanding of pathogenesis, staging, and management based on optical coherence tomography. *Sem Ophthalmol.* 2003;18:58-66.
- Lipham WJ, Smiddy WE. Idiopathic macular hole following vitrectomy: implications for pathogenesis. *Ophthalmic Surg Lasers Imaging.* 1997;28:633-639.
- Mandal S, Basu S. Giant macular hole with Best's disease in a young boy. *Clin Exp Optom.* 2012;95:643-645.
- Shah SN, Weinberg DV. Giant macular hole in Alport syndrome. *Ophthalmic Genet.* 2010;31:94-97.
- Moshfeghi AA, Salam GA, Deramo VA, Shakin EP, Ferrone PJ, Shakin JL, Fastenberg DM. Management of macular holes that develop after retinal detachment repair. *Am J Ophthalmol.* 2003;136:895-899.
- Campo RV, Sipperley JO, Sneed SR, Park DW, Dugel PU, Jacobsen J, Flindall RJ. Pars plana vitrectomy without scleral buckle for pseudophakic retinal detachments. *Ophthalmology.* 1999;106:1811-1815.
- Benzerroug M, Genevois O, Siahmed K, Nasser Z, Muraine M, Brasseur G. Results of surgery on macular holes that develop after rhegmatogenous retinal detachment. *Br J Ophthalmol.* 2008;92:217-219.
- Smiddy WE. Atypical presentations of macular holes. *Arch Ophthalmol.* 1993;111:626-631.
- Susini A, Gastaud P. Macular holes that should not be operated. *J Fr Ophtalmol.* 2008;31:214-220.