

Frequency of Human Papillomavirus in Larynx Squamous Cell Carcinoma and Clinicopathological Correlation of P53 and Ki-67 Expression

Larinks Primer Skuamöz Hücreli Karsinomlarında Human Papillomavirüs Sıklığı, P53 ve Ki-67 Ekspresyonlarının Klinikopatolojik Korelasyonu

Mevlüt Çetin¹, Nesibe Kahraman Çetin², Sevin Kırdar³, M.Gökhan Erpek⁴, İbrahim Meteoğlu⁵

¹Department of Otorhinolaryngology, Yozgat State Hospital, Yozgat

²Pathology Laboratory, Yozgat State Hospital, Yozgat

³Department of Medical Microbiology, Adnan Menderes University Faculty of Medicine, Aydın

⁴Department of Otorhinolaryngology, Adnan Menderes University Faculty of Medicine, Aydın

⁵Department of Pathology, Adnan Menderes University Faculty of Medicine, Aydın

Abstract

OBJECTIVE: Human papillomavirus (HPV) infections have been discussed with regard to laryngeal carcinogenesis in recent years. This study investigated the presence of HPV in larynx squamous cell carcinomas (SCC) via immunohistochemistry and polymerase chain reaction (PCR) array hybridization method and the relationship between p53 and Ki-67 expression with HPV presence and clinicopathological parameters.

MATERIALS AND METHODS: A total of 47 patients who had been operated on for larynx SCC were retrospectively included in the study. PanHPV, HPV-16, HPV-18, p53, and Ki-67 immunohistochemical stains were applied to cross-sections obtained from wax blocks by means of an avidin-biotin complex system. DNA was isolated from the cross-sections. The presence of HPV was investigated via the HybriBio HPV GenoArray diagnostic kit.

RESULTS: Polyclonal HPV positivity was detected only in 15 (31.9%) cases by means of PCR array hybridization method. Contrary to the literature, HPV-68 was found in two cases. In HPV (PCR)-positive cases, Ki-67 staining was found at high grade (p=0.01). The expression of p53 (p=0.041) increased as differentiation decreased in tumors. When comparing Ki-67, panHPV (p=0.004), and HPV-16 (p=0.002) staining, the expression of Ki-67 was higher than others in positive cases.

CONCLUSION: Formalin-fixed paraffin-embedded tissues can be used to indicate the presence of HPV. The use of the HybriBio HPV GenoArray test was much more straightforward than other methods and is useful in detecting HPV DNA. In the literature, no HPV-68 virus was detected in larynx SCCs until recently. The expression of Ki-67 and p53 could be central to the prognosis in larynx SCCs.

KEYWORDS: Human papillomavirus, larynx, PCR, p53, Ki-67, immunohistochemistry

Özet

AMAÇ: Larinks kanseri gelişiminde son yıllarda Human Papillomavirüs (HPV) enfeksiyonları üzerinde durulmaktadır. Bu çalışmada larinks skuamöz hücreli karsinom (SHK)'larında HPV varlığının immünohistokimyasal ve Polimeraz zincir reaksiyonu (PZR) dizisi hibridasyon yöntemiyle araştırılması, ayrıca p53, Ki-67 ekspresyonunun HPV varlığı ve klinikopatolojik parametrelerle ilişkisinin ortaya konması amaçlanmıştır.

GEREÇ VE YÖNTEMLER: Larinks SHK nedeniyle opere edilen 47 olgu retrospektif olarak çalışmaya alındı. Parafinli bloklardan hazırlanan kesitlere Avidin-Biyotin kompleks sistemiyle panHPV, HPV-16, HPV-18, p53 ve Ki-67 immünohistokimyasal boyaları uygulandı. Parafin bloklardan hazırlanan kesitlerden DNA izolasyonu yapıldı. Sonrasında HPV varlığı HybriBio HPV Genoarray Test ile araştırıldı.

BULGULAR: PZR-array hibridasyon yöntemi ile olguların 15'inde (%31,9) poliklonal HPV pozitifliği saptanmıştır. İki olguda literatürden farklı olarak HPV 68 bulunmuştur. HPV (PZR) pozitif bulunan olgularda anlamlı düzeyde yüksek Ki-67 boyanması (p=0,01) saptanmıştır. Tümörlerde diferansiyasyon azaldıkça p53 (p=0,041) ekspresyonunun arttığı görülmüştür. Ki-67 ile panHPV (p=0,004) ve HPV-16 (p=0,002) boyanması karşılaştırıldığında, pozitif olgularda Ki-67 ekspresyonunun yüksek olduğu gözlenmiştir.

SONUÇ: Formalin fikse parafine gömülü dokular HPV varlığının gösterilmesinde kullanılabilir. HybriBio HPV Genoarray test metodu diğer metodlara göre kullanımı oldukça basittir ve HPV-DNA saptanmasında kıymetli bir araç olabilir. Literatür araştırıldığında şimdiye kadar HPV 68 virüsünün larinks SHK'larında saptanmadığı görülmüştür. Ki-67 ve p53 ekspresyonları larinks SHK'larında iyi veya kötü prognoz açısından yol gösterici olabilir.

ANAHTAR KELİMELELER: Human papillomavirüs, larinks, PZR, p53, Ki-67, immünohistokimya

Çalışmanın Mikrobiyoloji kısmı 7. Ulusal Moleküler ve Tanısal Mikrobiyoloji Kongresi'nde poster olarak sunulmuştur.

Correspondence to / Yazışma adresi: Dr. Mevlüt Çetin, Department of Otorhinolaryngology, Yozgat State Hospital, Yozgat, Turkey

Phone / Tel. : +90 354 212 12 70 e.mail / e.posta : mevlutcetin01@gmail.com

Received / Geliş Tarihi: 28.09.2014 • Accepted / Kabul Tarihi: 10.04.2014

©Telif Hakkı 2014 Adnan Menderes Üniversitesi Tıp Fakültesi - Makale metnine www.adutfd.org web sayfasından ulaşılabilir. / ©Copyright 2014 by Adnan Menderes University Faculty of Medicine - Available online at www.adutfd.org



Introduction

Laryngeal cancer is the most common form of cancer in the head and neck area and constitutes 2% of all cancers in adults (1). The incidence varies between different countries and has shown an increasing trend in many studies (2). Ninety percent of tumor cases are squamous cell carcinomas (SCCs), and the main predisposing factors are smoking and alcohol. Viral infections, malnutrition, and local dietary habits are also factors in the etiology of laryngeal cancer (3).

Human papillomavirus (HPV) is a small DNA virus of the family Papovaviridae, which generally infects squamous cells. More than 100 types of HPV have been defined (4). Biomolecular studies reveal that specific mechanisms play roles in HPV-based carcinogenesis, and it is assumed that there is a relationship between HPV infection and cancers of the head and neck. Many studies of the frequency of HPV in head and neck cancers reported 34.5% as a positive result (5). However, the localization of a certain tumor group varies widely, between 7% and 59%, according to method or patient characteristic (6).

In HPV detection and typing, there is increasing interest in the use of nucleic acid amplification tests for formalin-fixed paraffin-embedded tissues. The detection of viral nucleic acids in formalin-fixed paraffin-embedded tissues can be complicated, as a result of excessive fixation and long-term secondary viral DNA/RNA degradation. However, such specimens are useful for HPV detection when fresh or frozen tissue can not be obtained and because most surgical pathology specimens are formalin-fixed paraffin-embedded tissues (7). Today, HPV detection in formalin-fixed paraffin-embedded tissues is based on immunohistochemistry, primarily replacing protein markers and in situ hybridization (ISH) for HPV DNA. Immunohistochemical methods have high sensitivity but low specificity. On the other hand, ISH methods are specific but have low sensitivity, and thus, the findings can be difficult to assess. Compared to immunohistochemistry and ISH, the use of nucleic acid amplification tests provides increased analytic sensitivity and specificity and thus can supplement these techniques (8).

The key factor in apoptosis integration with the cell cycle is p-53 protein, which is a tumor-suppressing gene product (9). Many studies reported mutant p53 protein in larynx SCCs. However, it is controversial whether this is an indicator of poor prognosis or not. Some studies indicate that the index of tumor suppressor gene protein is related to a poor prognosis, whereas others suggest the opposite (10-12).

There is a good correlation between the amount of mitosis in tumor tissue and nuclear immunoreactivity of Ki-67, which indicates cell proliferation (12). The prognostic importance of cell proliferation is controversial in larynx SCCs. The literature includes articles reporting that high Ki-67 proliferation index is a bad prognostic indicator (13). On the other hand, some studies report no relationship to patient survival (11).

This study investigated the presence of HPV in larynx SCCs via an immunohistochemical method and the HPV GenoArray test, which is a commercial polymerase chain reaction (PCR) array hybridization method. In addition, this study presents p53 and Ki-67 expression, revealing the relationship of these indicators with the presence of HPV and clinicopathological parameters.

Materials and Methods

Patients

This study retrospectively included 47 cases that were operated on for larynx SCC at the Otorhinolaryngology Clinic of Adnan Menderes University, Turkey. Paraffin block samples obtained from patients were chosen from the archive of the Pathology Department, and cross-sections of these blocks were tested for immunohistochemistry and PCR. Clinical data of the patients were recorded.

Immunohistochemical staining

Hematoxylin and eosin (H&E)-stained preparates of cases were re-examined. Cross-sections were chosen from blocks that were necrosis-free or those containing minimum necrosis. Immunohistochemical stains were applied to new cross-sections obtained from the blocks, including: panHPV [human papilloma virus (HPV) Ab-3 Thermo MS-1826-R7 (RTU), Type: 6, 11, 16, 18, 31, 33, 42, 51, 52, 56, 58], HPV-16 [anti-papillomavirus tube 16 (HPV-16) (CamVir-1) Biogenex AM362-5M (RTU)], HPV-18 [human papilloma virus 18 E7 (HPV-18) (Clone 718-15) Thermo MA1-23076], p53 [rabbit anti-human p53 monoclonal antibody (clone SP5) Spiring MS3056 (RTU)] and Ki-67 [rabbit anti-human Ki-67 monoclonal antibody (clone SP6) Spiring MS3066 (RTU)]. Immunohistochemical staining was via the avidin-biotin complex system. Pursuant to staining, cross-sections were examined under an optical microscope (Olympus BX51, Tokyo, Japan) at 4x, 10x, 20x, and 40x magnification. Nuclear staining was assessed for all immunohistochemical stains. In the most intensely stained area, at least 200 cells were found. For Ki-67 and p53, the staining percentages were scored as follows: less than 5%: 0; 5-10%: +; 11-20%: ++; and more than 20%: +++. For panHPV, HPV-16, and HPV-18, semi-quantitative scores were "0" for no staining, "+" for focal staining, and "++" for extensive staining.

HybriBio HPV genoarray test

For PCR and genotyping, between 10 and 20 leaf cross-sections, 5-10 microns in thickness, were obtained from paraffin blocks. Specimens were tested with a HybriBio HPV GenoArray diagnostic kit (GenoArray, HybriBio Ltd., Hong Kong). This test kit combines PCR and hybridization methods and can qualitatively detect 21 types of HPV. The test offers a macro-array format, through which HPV genotype-specific oligonucleotide probes are immobilized on a plastic membrane (14). The sensitivity of the method is 4-89 genome copies/ μ l and varies by HPV genotype. It is also reported that there is no cross-reactivity between different HPV types during hybridization (15). A commercial NucleoSpin Tissue mini column (Macherey-Nagel, Duren, Germany) isolation kit was used for the removal of paraffin from tissue and for DNA isolation. Following DNA isolation, HPV typing was conducted at three stages: increase of DNA via PCR, hybridization, and assessment of the results. For the increase of HPV DNA with PCR, 23.24 μ l PCR mix, 0.75 μ l DNA Taq polymerase, and 1 μ l isolated DNA were added to PCR tubes for each specimen, in line with the manufacturer's instructions. PCR tubes that were prepared for the 47 specimens were placed in an Eppendorf- brand thermal cycler device for the amplification stage. The amplification process consisted of denaturation at 95°C for 9 min with a thermal cycler; then, a program comprising 40 cycles at 95°C for 20 sec, at 55°C for 30 sec, and at 72°C for 30 sec; and a final extension for 5 min at 72°C.

For the hybridization process, square-shaped hybridization membranes were placed in a HybriMax device. A mixture of 0.5 μ l heated

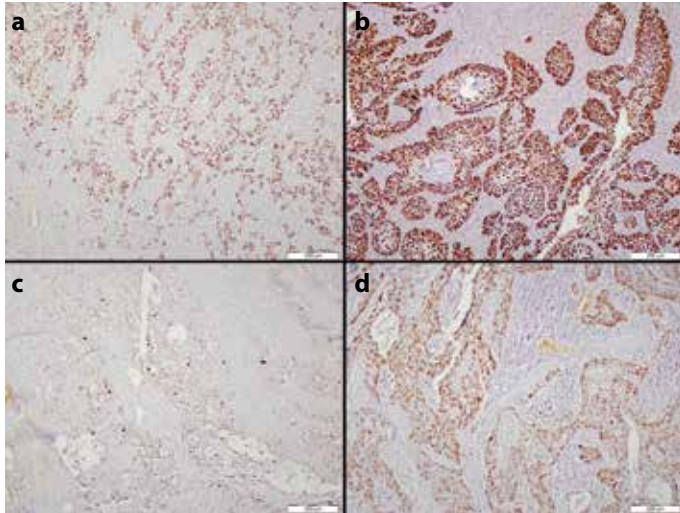


Figure 1. a-d. Low- (a) and high-grade (b) immunohistochemical staining with p53; low- (c) and high-grade (d) immunohistochemical staining with Ki-67

hybridization buffer and 20 µl PCR products was added to each specimen. Following processes conducted in accordance with the method, wet membranes were left to dry, and the place of purple dots on the membranes was assessed by eye. The accuracy of the test was assessed by the presence of amplification points in the first well of the membrane and the dot in the well below, indicating that the hybridization process was completed. A negative result was determined via the presence of amplification and hybridization dots combined with a lack of dots on the membranes in the wells. A positive result was indicated by the presence of amplification and hybridization dots, combined with the occurrence of dot/s according to the localization of 21 HPV types (the kit includes high-risk group: HPV-16, 18, 31, 33, 35, 39, 45, 51, 52, 56, 58, 59, 66, 68 and low-risk group: 6, 11, 42, 43, 44, 53, and CP8304).

Statistical analysis

In the test for Ki-67 and p53, staining between 0% and 10% was considered low grade, and >10% was considered high-grade staining. In the examination of PanHPV, HPV-16, and HPV-18, focal and extensive staining was considered positive; those without staining were considered negative.

Statistical analysis was conducted with Statistical Package for the Social Sciences (SPSS Inc., Chicago, IL, USA), version 14.0 for Windows. Definitive statistics used number and percentages; intergroup comparisons used chi-square and Fisher's exact test, and comparisons between dependent groups used the McNemar test. A p-value <0.05 was considered to be significant.

Results

Clinical and pathologic data of the cases are presented in Table 1.

In the p53 staining via the immunohistochemical method, low-grade staining was detected in 22 (46.8%) cases, and high-grade staining was detected in 25 (53.2%) cases. No significant difference was found between p53 and smoking ($p=0.611$), tumor localization ($p=0.927$), neck metastasis ($p=0.790$), T phase ($p=0.381$), panHPV staining ($p=0.053$), HPV-16 staining ($p=0.163$), and Ki-67 staining ($p=0.210$).

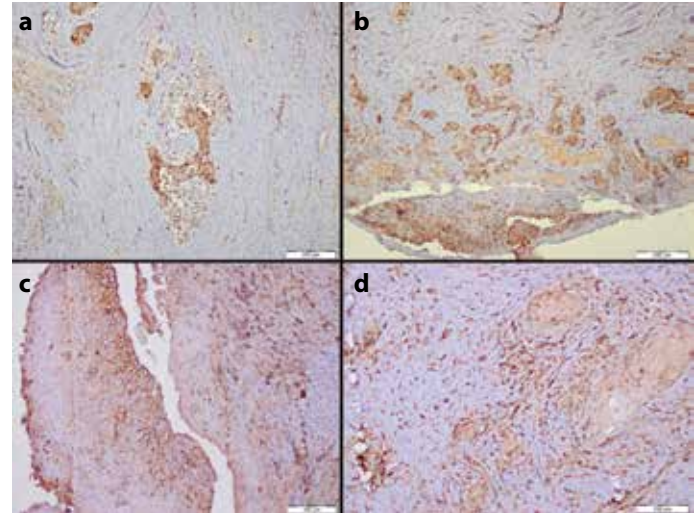


Figure 2. a-d. Immunohistochemical staining with panHPV: focal (a) and extensive (b); immunohistochemical staining with HPV-16: focal (c) and extensive (d)

Histological grade showed that as differentiation decreased, p53 expression increased ($p=0.041$).

In the immunohistochemical Ki-67 staining, low-grade staining was detected in 19 (40.4%) cases, and high-grade staining was detected in 28 (59.6%) cases. No significant difference was found between Ki-67 and smoking ($p=0.137$), tumor localization ($p=0.990$), neck metastasis ($p=1.00$), histological grade ($p=0.439$), and T phase ($p=1.000$). When comparing Ki-67 and panHPV ($p=0.004$) and HPV-16 ($p=0.002$) staining, the expression of Ki-67 was higher in positive cases (Figure 1).

In panHPV staining via the immunohistochemical method, negative staining was detected in 25 (53.2%) cases, and positive staining was detected in 22 (46.8%) cases. In the HPV-16 staining, negative staining was detected in 27 (57.4%) cases, and positive staining was detected in 20 (42.6%) cases. None of the patients showed positive

Table 1. Clinical and pathologic data of cases

Gender	1 Female (2.1%)
	46 Males (97.9%)
Smoking	43 smokers (91.5%)
	4 non-smokers (8.5%)
Histological grade	20 good differential (42.6%)
	22 medium differential (46.8%)
	5 low differential (10.6%)
Tumor localization	7 supraglottic (14.9%)
	20 transglottic (42.6%)
	20 glottic (42.6%)
TNM staging	15 T1 (31.9%)
	11 T2 (23.4%)
	5 T3 (10.6%)
	16 T4 (34%)
Lymph node involvement	12 metastases (25.5%)

Table 2. Rate of HPV in cases

panHPV (immunohistochemistry)	22 positive (46.8%) 25 negative (53.2)
HPV-16 (immunohistochemistry)	20 positive (42.6%) 27 negative (57.4%)
HPV (PCR)	15 polyclonal HPV positivity (31.9%) 32 negative (68.1%)
HPV (PCR) Distribution	5 HPV-16 (10.6%) 1 HPV-31 (2.1%) 1 HPV-52 (2.1%) 5 HPV-53 (10.6%) 1 HPV-16 and HPV-52 (2.1%) 2 HPV-16 and HP-68 (4.3%)

HPV: human papillomavirus; PCR: polymerase chain reaction

HPV-18 staining via the immunohistochemical method. In the pan-HPV and HPV-16 staining, no significant relationship was detected between smoking ($p=0.894$, $p=0.458$), tumor localization ($p=0.620$, $p=0.587$), neck metastasis ($p=0.797$, $p=0.517$), histological grade ($p=0.666$, $p=0.761$), and T phase ($p=0.491$, $p=0.528$). A significant difference was detected between panHPV and HPV-16 staining; all cases stained with HPV-16 were also stained with panHPV (Figure 2).

Polyclonal HPV positivity was detected in 15 (31.9%) cases via the PCR array hybridization method. HPV-16 was detected in 5 (10.6%) cases, HPV-31 was detected in 1 (2.1%), HPV-52 was detected in 1 (2.1%) case, HPV-53 was detected in 5 (10.6%) cases, HPV16 and HPV-5 were detected in 1 (2.1%) case, and HPV-16 and HPV-68 were detected in 2 (4.3%) cases (Figure 3). No significant difference was found between HPV PCR positivity and smoking ($p=1.000$), tumor localization ($p=0.318$), neck metastasis ($p=0.725$), histological grade ($p=0.453$), and T phase ($p=0.414$). Contrary to the literature, HPV-68 was found in two cases (Table 2).

There was no significant difference between the immunohistochemical panHPV results and HPV (PCR) methods ($p=0.143$). When comparing the HPV16 (PCR) results with immunohistochemical HPV-16 positivity, a significant difference ($p=0.000$) was found, and immunohistochemical positivity was observed in cases with HPV-16. HPV-18 was not detected with these two methods. In HPV (PCR)-positive cases, no significant relationship was detected with p53 ($p=0.989$); on the other hand, a statistically significant relationship was detected with Ki-67 ($p=0.01$) staining.

Discussion

Most laryngeal cancers are SCCs (16). In the literature, it is reported that 60% of larynx cancers are glottic, 40% is supraglottic, and only 1% or fewer are subglottic (17). In this study, glottic tumor localization (42.6%) was most common.

Smoking and alcohol consumption are the most important etiologic factors in laryngeal cancer (18, 19). Smoking is the most common environmental factor, both as an initiator and progressor (20). The prevalence of smoking is lower among women than men. It is assumed that passive smokers bear the same risk, although this has not yet

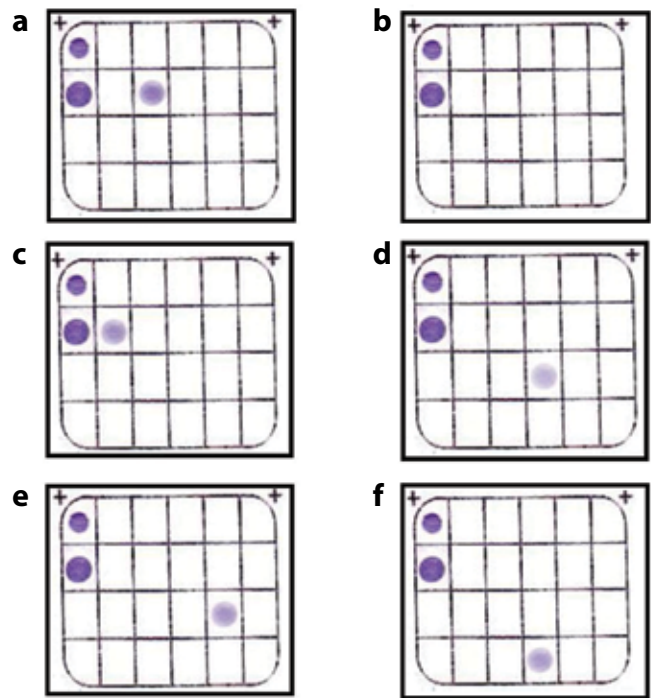


Figure 3. a-f. HybriBio HPV GenoArray test kit, positive (a) and negative (b) controls. Hybridization membrane HPV type 16 (c), type 52 (d), type 53 (e), and type 68 (f) samples

been demonstrated (19). Low socio-economic status, laryngeal papillomatosis, and family history are other etiologic factors (18). In this study, 91.5% of cases were smokers.

p53 gene is a tumor suppressor gene that weighs 53 kDa and is located on the short arm (17p13.1) of chromosome 17. It controls DNA replication, cell proliferation, and cell death (21). Various human tumors mutate in the p53 gene. This situation leads to increased stability of this protein and increased immune staining. However, HPV-related cancers generally do not mutate in p53. It is revealed that the E6 protein of HPV bonds to p53 and its degradation. Cells that express HPV E6 protein can not accumulate significant levels of p53 protein pursuant to DNA damage. Therefore, p53 loss of function can be related to mutation, similar to HPV-negative head/neck cancers, or can be related to rapid degradation, as in HPV-related cervical cancers (22). p53 mutation is reported in 39%-80% of head and neck SCCs (9). It is reported that excessive p53 expression is related to precancerous and proliferative activity in malignant larynx lesions. In addition, it is reported that some groups are diagnosed with p53 protein at relatively high frequency in precancerous lesions of the larynx (23). These findings suggest there are some disconformities in precancerous lesions of the larynx to indicate the importance of p53. Kazkayası et al. (24) reported no significant relationship between p53 expression and patient age, tumor location, clinical phase, histopathologic grading of tumor, alcohol, and clinical progress; they found a significant relationship between excessive p53 expression and lymph node metastasis. Jacob et al. (25) reported a relationship between HPV infection and increased p53 expression in larynx SCCs. In this study, no relationship was observed between the presence of HPV and p53 staining; however, a significant difference was detected in high-grade tumors ($p=0.041$).

Ki-67 is a nuclear non-histone protein located on chromosome 10. It consists of two molecules, weighing 345 kDa and 395 kDa. G1 and G2 of the cell cycle out of G0 are expressed in the M and S phases (26). The importance of cell proliferation in larynx SCCs in the prognosis is controversial, because previous studies obtained contradictory results. Açıklın et al. (13) found a significant correlation between high Ki-67 index and age, T phase, lymph node metastasis, increased recurrence, and short survival period. In the same study, no significant relationship was observed between Ki-67 and tumor localization or histopathologic grade (13). Liu et al. (27) reported that high Ki-67 index correlated with T phase and tumor differentiation and was inversely proportional to disease-free survival. In the same study, no significant relationship was detected between p53 expression and clinicopathologic data, and it was reported that p53 expression had no prognostic value. Lera et al. (28) found no relationship between clinicopathologic features and the expression of Ki-67 and p53 in larynx SCC cases; however, they reported that survival was shorter in cases with high Ki-67 index and that p53 does not influence survival. In the present study, no significant difference was detected between Ki-67 expression and clinicopathologic parameters, and no correlation was found with p53 expression ($p=0.210$).

The relationship between HPV and upper-airway pathologies has been known for approximately 1 century (29). However, in the last 3 decades, viral oncogenic effects have been better revealed in the literature (30). It has been found that among forms of head and neck cancer, HPV is particularly related to tonsil and oropharyngeal cancers (31). The cause-and-effect relationship between HPV and SCCs suggests the presence of virus as a risk indicator. The high-risk sub-types of HPV are basically HPV16, 18, 31, 33, 39, 45, 52, 58, 68, and 69. These types play a role in cervical and other anogenital cancers. HPV-6 and HPV-11 are "low-risk" types and are rarely found in malignant lesions (16).

Immunohistochemistry is performed using a commercially available monoclonal rat antibody. The test can be used for HPV detection during histopathological diagnosis (3). Dönmez et al. (32) detected HPV in 37.5% of cases using the immunohistochemical method and concluded that the staining was technically difficult. In the present study, HPV-16 and HPV-18 antibodies that occurred in the high-risk group and panHPV were detected via the immunohistochemical method. The resulting positive staining rates were 53.2% with pan-HPV and 57.4% with HPV-16. No specific staining was detected with HPV-18. A significant correlation ($p=0.000$) was detected between panHPV and HPV-16. Immunohistochemistry is a cheaper and easier method of determining the presence of HPV; however, it should be remembered that erroneous staining outcomes may occur due to technical reasons.

In the detection of HPV infections, the prevalent approach involves the display of viral nucleic acids due to non-advantageous virus isolation or serologic tests (15). Virological tests consist of ISH, Southern blot hybridization, dot-blot hybridization, PCR, and real-time PCR. However, the detection power of ISH is low. In addition, PCR and real-time PCR require specific expensive equipment, such as a thermal cycler, and these methods are not yet common in hospital laboratories (33). The HybriBio GenoArray test used in this study is a commercial kit that has recently increased in popularity. At the present time, it is used in China, and there are studies supporting its value in high-risk HPV detection (4).

The argument in HPV typing methods results from the lack of a confirmed method for HPV genotyping in formalin-fixed paraffin-embedded tissues. Some methods require special instruments and may not be easily applied in molecular pathology and molecular virology laboratories (34). Recently, various methods have been developed to present HPV types in wide panels. To date, these methods have only been used in studies in the USA, and it is seen that they have primary benefits for epidemiological studies of HPV infection (8).

Morshed et al. (35) used the PCR method to investigate HPV DNA in paraffin and fresh-frozen tissues in 54 larynx SCCs. They found that paraffin tissues can be used for HPV DNA detection in retrospective studies (35). Gorgoulis et al. (36) detected HPV positivity in 20 (13%) of 154 larynx SCC cases. They detected HPV-6 (1.1%) in 1 case, HPV-16 (16.2%) in 12 cases, HPV-18 (2.2%) in 2 cases, and HPV-33 (1.1%) in 1 case. In the present study, HPV DNA isolation of paraffin tissues was made, and typing was conducted with the GenoArray hybridization method. Using the PCR method, polyclonal HPV positivity was detected only in 15 (31.9%) cases. HPV-16 was detected in 5 (10.6%) cases, HPV-31 was detected in 1 (2.1%) case, HPV-52 was detected in 1 (2.1%) case, HPV-53 was detected in 5 (10.6%) cases, HPV-16 and HPV-52 were detected in 1 (2.1%) case, and HPV-16 and HPV-68 were detected in 2 (4.3%) cases. Having previously been categorized as medium-risk, HPV-68 has been reclassified in the high-risk group in recent years. Within the literature, no HPV-68 virus was detected in larynx SCCs until recently.

Morshed found a 35.5% prevalence of HPV DNA with PCR in 93 laryngeal SCC cases, and staining was 27.7% with immunohistochemistry in 130 cases. In HPV detection, no correlation was found between the PCR method and immunohistochemical technique. PCR was recommended as the most sensitive method of HPV detection (3). In the present study, no significant difference was found between panHPV staining and the PCR results. However, a correlation ($p=0.000$) was detected between HPV-16 presence that was detected with PCR and HPV16 positivity detected immunohistochemically. Deilson et al. (16) detected high-risk HPV in 37.3% of 110 larynx SCC cases, HPV-16 in 37% of cases, and HPV-18 in 44% of cases. In the same study, p53 positivity was found in 78.2% of cases. It is remarkable that these cases had a high grade and high Ki-67 index (16). In the present study, high-grade Ki-67 staining was observed in cases with panHPV ($p=0.004$) and HPV-16 ($p=0.002$) positivity. In addition, Ki-67 staining was significantly high in cases with HPV (PCR) positivity ($p=0.01$).

The relationship between HPV and larynx cancer has not yet been clarified. Challenges in HPV detection and typing may result from temporary infections, patched involvement, and the various methods used in studies on the presence of HPV and from the differing sensitivities of these methods. Immunohistochemical detection of HPV is a cheap and easy method that can utilize tumor tissues. Although it has some weaknesses, such as subjective assessment and potentially erroneous results due to technical conditions, it remains a good supplementary test for the presence of HPV. For HPV detection, the gold standard method is to study HPV DNA with PCR on fresh tissue; however, paraffin-embedded tissues can also be used to indicate the presence of HPV. The use of the HybriBio HPV GenoArray test has increased in recent years; it is much simpler than other methods and can be a valuable tool to detect HPV-DNA.

It is hoped that further HPV studies on larger datasets using standard methods will give more definitive results. Identifying the presence of HPV will shed light on the prevention of laryngeal cancers and assist in HPV vaccination activities.

In the literature, it is not clear how the expression of p53 and Ki-67 affects the prognosis in larynx carcinoma. In the present study, it is assumed that the relationship between high grade and high-grade p53 expression can be an indicator of the poor prognosis of p53 expression. In HPV-positive cases, Ki-67 staining was significantly high-grade. The expression of Ki-67 and p53 could be central to a good or poor prognosis in laryngeal SCCs. Further studies are required to better understand the importance of these parameters for the treatment and follow-up of laryngeal SCCs.

Ethics Committee Approval: Due to the retrospective design of the study, the ethics committee approval is not required.

Informed Consent: Informed consent was not necessary because the study was a retrospective study.

Peer-review: Externally peer-reviewed.

Author contributions: Concept - M.Ç., M.G.E.; Design - M.Ç., N.K.Ç.; Supervision - M.G.E., İ.M.; Resource - İ.M., S.K.; Materials - ADÜ BAP TPF-10007; Data Collection&/or Processing - H.T., F.A.; Analysis&/or Interpretation - H.T., F.A.; Literature Search - M.Ç., N.K.Ç.; Writing - M.Ç., N.K.Ç.; Critical Reviews - M.G.E., İ.M., S.K.

Conflict of Interest: No conflict of interest was declared by the authors.

Financial Disclosure: This study was supported financially by Adnan Menderes University Scientific Research Commission by number of TPF-10007.

Etik Kurul Onayı: Yapılan çalışma retrospektif bir arşiv çalışması olduğundan etik kurul onayına gerek görülmemiştir.

Hasta Onamı: Yapılan çalışma retrospektif bir arşiv çalışması olduğundan hasta onamına gerek görülmemiştir.

Hakem değerlendirmesi: Dış bağımsız.

Yazar Katkıları: Fikir - M.Ç., M.G.E.; Tasarım - M.Ç., N.K.Ç.; Denetleme - M.G.E., İ.M.; Kaynaklar - İ.M., S.K.; Malzemeler - ADÜ BAP TPF-10007; Veri toplanması ve/veya işleme - M.Ç., N.K.Ç.; Analiz ve/veya yorum - M.G.E., İ.M., S.K.; Literatür taraması - M.Ç., N.K.Ç.; Yazıyı yazan - M.Ç., N.K.Ç.; Eleştirel inceleme - M.G.E., İ.M., S.K.

Çıkar Çatışması: Yazarlar çıkar çatışması bildirmemişlerdir.

Finansal Destek: Bu çalışma Adnan Menderes Üniversitesi Bilimsel Araştırma Komisyonu tarafından TPF-10007 no ile finansal olarak desteklenmiştir.

References

- Lazaris AC, Lendari I, Kavantzias N, Kandiloros D, Adamopoulos G, Davaris P. Correlation of tumor markers p53, bcl-2 and cathepsin-D with clinicopathologic features and disease-free survival in laryngeal squamous cell carcinoma. *Pathol Int* 2000;50:717-24. [\[CrossRef\]](#)
- Robin PE, Reid A, Powell DJ, McConkey CC. The incidence of cancer of the larynx. *Clin Otolaryngol Allied Sci* 1991;16:198-201. [\[CrossRef\]](#)
- Morshed K. Difference between human papillomavirus infection and laryngeal squamous cell carcinoma. *J Med Virol* 2010;82:1017-23. [\[CrossRef\]](#)
- Du J, Lu X, Liang J, Yang Y, Lin J, Zhu X, Xu J. Detection and typing of human papillomavirus (HPV) in Condyloma acuminatum and bowenoid papulosis. *HybridBio HPV GenoArray testkit, real time polymerase chain reaction (PCR) and sequencing. Afr J Pharm Pharmacol* 2013;7:73-7. [\[CrossRef\]](#)
- Öktem F, Aydın S, Öz F, Toprak M, Ada M. Baş-boyun kanserlerinde Human papilloma virus enfeksiyonunun rolü. *K.B.B. ve Baş Boyun Cerrahisi Dergisi* 2000; 8:51-7.
- Brandwein MS, Nuovo GJ, Biller H. Analysis of prevalence of human papillomavirus in laryngeal carcinomas. Study of 40 cases using polymerase chain reaction and consensus primers. *Ann Otol Rhinol Laryngol* 1993;102:309-13. [\[CrossRef\]](#)
- Kong CS, Welton ML, Longacre TA. Role of human papillomavirus in squamous cell metaplasia-dysplasia-carcinoma of the rectum. *Am J Surg Pathol* 2007;31:919-25. [\[CrossRef\]](#)
- Mills A, Balasubramaniam R, Longacre TA, Kong CS, Pinsky BA. Laboratory-developed L1 sequencing and type-specific, real time polymerase chain reaction for the detection and typing of human papillomaviruses in formalin-fixed, paraffin-embedded tissues. *Arch Pathol Lab med* 2013;137: 50-4. [\[CrossRef\]](#)
- Nakashima T, Wang XF, Masuda M, Inokuchi A, Komiyama S. Overexpression of p53 nuclear protein in premalignant and malignant laryngeal lesions. *Eur Arch Otorhinolaryngol* 1999;256:56-9. [\[CrossRef\]](#)
- Rodriguez Tojo MJ, Garcia Cano FJ, Infante Sanchez JC, Velaquez fernandez E, Aquirre Urizar JM. Immunexpression of p53, Ki-67 and E-cadherin in basaloid squamous cell carcinoma of the larynx. *Clin Transl Oncol* 2005;7:110-4. [\[CrossRef\]](#)
- Calli C, Calli A, Pinar E, Oncel S, Demirtaşoğlu F. Expression of Ki-67 and p53 in laryngeal squamous cell carcinomas. *Kulak Burun Bogaz İhtis Derg* 2005;15:9-13.
- Rosai J. Larynx. In: Rosai J. Rosai and Ackerman's Surgical Pathology. 9th ed. New York, New York, USA: Mosby Inc; 2004. pp. 335-48.
- Acikalin MF, Oner U, Tel N, Paşaoğlu O, Cakli H, Colak E. Prognostic significance of Ki-67 expression for patients with laryngeal squamous cell carcinoma primarily treated by total laryngectomy. *Eur Arch Otorhinolaryngol* 2004;261:376-80. [\[CrossRef\]](#)
- Grisaru D, Avidor B, Niv J, Marmor S, Almog B, Leibowitz C, et al. Pilot study of prevalence of high-risk human papillomavirus genotypes in Israeli Jewish women referred for colposcopic examination. *J Clin Microbiol* 2008;46:1602-5. [\[CrossRef\]](#)
- Ergünay K, Mısırlıoğlu M, Firat P, Tuncer ZS, Tuncer S, Yıldız I, et al. Detection and typing of human papilloma virus by polymerase chain reaction and hybridization assay in cervical samples with cytological abnormalities. *Mikrobiyol Bül* 2008;42:273-82.
- De Oliveira DE, Bacchi MM, Macarenco RS, Taqliarini JV, Cordeir RC, Bacchi CE. Human Papillomavirus and Epstein-Barr Virus Infection, p53 Expression, and Cellular Proliferation in laryngeal Carcinoma. *Am J Clin Pathol* 2006;126:284-93. [\[CrossRef\]](#)
- Vielba R, Bilbao J, Ispizua A, Zabalza I, Alfaro J, Rezola R, Moreno E, Ello-riaga J, Alonso I, Baroja A, de la Hoz C. p53 and Cyclin D1 as prognostic factors in Squamous cell carcinoma of the larynx. *Laryngoscope* 2003; 113:167-72. [\[CrossRef\]](#)
- Sas-Korczynska B, Korzeniowski S, Skolyszewski J. Cancer of the larynx in females. *Cancer Radiother* 2003;7:380-5. [\[CrossRef\]](#)
- Leon X, Rinaldo A, Saffiotti U, Ferlito A. Laryngeal cancer in non-smoking and nondrinking patients. *Acta Otolaryngol* 2004;124:664-9. [\[CrossRef\]](#)
- Kaufman JA, Burke AJ. The etiology and pathogenesis of laryngeal carcinoma. *Otolaryngol Clin North Am* 1997;30:1-19.
- Ribeiro-Silva A, Zambelli Ramalho LN, Britto Garcia S, Zucoloto S. The relationship between p63 and p53 expression in normal and neoplastic breast tissue. *Arch Pathol Lab Med* 2003;127:336-40.
- Rabah R, Sakr W, Thomas R, Lancaster WD, Gregoire L. Human papillomavirus type, proliferative activity, and p53: potential markers of aggressive papillomatosis. *Arch Pathol Lab Med* 2000;124:721-4.
- Hofseth LJ, Hussain SP, Harris CC. p53: 25 years after its discovery. *Trends Pharmacol Sci* 2004;25:177-81. [\[CrossRef\]](#)
- Kazkayasi M, Hücümenoğlu S, Siriner Gİ, Hücümenoğlu M. Over-expression of p53 and c-erbB2 oncoproteins in laryngeal carcinoma. *Eur Arch Otorhinolaryngol* 2001;258:329-35. [\[CrossRef\]](#)
- Jacob SE, Sreevidya S, Chacko E, Pillai MR. Cellular manifestations of human papillomavirus infection in laryngeal tissues. *J Surg Oncol* 2002;79:142-50. [\[CrossRef\]](#)
- Hirai T, Hayashi K, Takumida M, Ueda T, Hirakawa K, Yajin K. Reduced expression of p27 is correlated with progression in precancerous lesions of the larynx. *Auris Nasus Larynx* 2003;30:163-8. [\[CrossRef\]](#)

27. Liu M, Lawson G, Delos M, Jamart J, Chatelain B, Remacle M, Marbaix E. Prognostic value of cell proliferation markers, tumour suppressor proteins and cell adhesion molecules in primary squamous cell carcinoma of the larynx and hypopharynx. *Eur Arch Otorhinolaryngol* 2003;260:28-34.
28. Lera J, Lara PC, Perez S, Cabrera JL, Santana C. Tumor proliferation, p53 expression, and apoptosis in laryngeal carcinoma: relation to the results of radiotherapy. *Cancer* 1998; 83: 2493-2501. [\[CrossRef\]](#)
29. Ullman EV. On the aetiology of the laryngeal papilloma. *Acta Oto-laryngol* 1923;5:317-34.
30. Adelstein DJ, Ridge JA, Gillison ML, Chaturvedi AK, D'Souza G, Gravitt PE, et al. Head and neck squamous cell cancer and the human papillomavirus: summary of a National Cancer Institute State of the Science Meeting, November 9–10, 2008, Washington, D.C. *Head Neck* 2009;31:1393-422. [\[CrossRef\]](#)
31. Fakhry C, Westra WH, Li S, Cmelak A, Ridge JA, Pinto H, et al. Improved survival of patients with human papillomavirus-positive head and neck squamous cell carcinoma in a prospective clinical trial. *J Natl Cancer Inst* 2008;100:261-9. [\[CrossRef\]](#)
32. Dönmez M, Erdem Huq E, Akdur NC, Gözel S, Bozkurt RE. p16 expression in Laryngeal squamous cell carcinoma and its relationship with Human papillomavirus. *Turkiye Klinikleri J Med Sci* 2012;32:1576-85. [\[CrossRef\]](#)
33. Hagiwara M1, Sasaki H, Matsuo K, Honda M, Kawase M, Nakagawa H. Loop-mediated isothermal amplification method for detection of human papillomavirus type 6, 11, 16 and 18. *J Med Virol* 2007;79:605-15. [\[CrossRef\]](#)
34. Poljak M, Kocjan BJ. Commercially available assays for multiplex detection of alpha human papillomaviruses. *Expert Rev Anti Infect Ther* 2010;8:1139-62. [\[CrossRef\]](#)
35. Morshed K, Polz-Dacewicz M, Szymański M, Smoleń A. Usefulness and efficiency of formalin-fixed paraffin-embedded specimens from laryngeal squamous cell carcinoma in HPV detection by IHC and PCR/DEIA. *Folia Histochem Cytobiol* 2010;48:398-402. [\[CrossRef\]](#)
36. Gorgoulis VG, Zacharatos P, Kotsinas A, Kyroudi A, Rassidakis AN, Ikonomopoulos JA, et al. Human papilloma virus (HPV) is possibly involved in laryngeal but not in lung carcinogenesis. *Hum Pathol* 1999;30:274-83. [\[CrossRef\]](#)