



Florid Diffuse Peritoneal Deciduositis Mimicking Peritoneal Carcinomatosis: A Case Report

Peritoneal Karsinomatozisi Taklit Eden Florid Diffüz Peritoneal Desiduozis: Olgu Sunumu

Nurhan Erzurumluoğlu, Aytül Sargan, Selver Özekinci, Fetin Rüştü Yıldız

Okmeydanı Training and Research Hospital, Clinic of Pathology, İstanbul, Turkey

Abstract

Deciduositis is defined as the presence of decidual tissue in an ectopic site and must be distinguished from the more alarming conditions that it can simulate. Ectopic decidua is observed usually in the uterus, cervix, fallopian tube, and the ovaries. Peritoneal location is rare. It usually involutes within four to six weeks postpartum. We present this case because of its similar clinical and radiological findings with malignancy.

Keywords: Deciduositis, ectopic decidua, peritoneal carcinomatosis

Öz

Desiduozis ektopik bir bölgede desidual dokunun varlığı olarak tanımlanır ve taklit edebileceği daha endişe verici diğer durumlardan ayırt edilmelidir. Ektopik desidua genellikle uterus, serviks, tubalar, overlerde görülür. Peritoneal lokalizasyon daha nadirdir. Genellikle postpartum dört-altı haftalar arasında geriler. Peritoneal desiduozis klinik ve radyolojik bulgularla, maligniteyi taklit edebilmesi nedeniyle bu olguyu sunmak istedik.

Anahtar Sözcükler: Desiduozis, ektopik desidua, peritoneal karsinomatozis

Introduction

Deciduositis is defined as the presence of decidual tissue in an ectopic site and must be distinguished from the more alarming conditions that it can simulate. Ectopic decidua is observed usually in the uterus, cervix, fallopian tube, and ovaries. Peritoneal location is rare (1,2). Other rare sites include the appendix, omentum, diaphragm, liver, spleen, lymph nodes and renal pelvis, etc (2).

It appears to be associated with a physiologic metaplastic response of the subcoelomic mesenchymal cells to the elevated levels of circulating progesterone hormone during pregnancy. Another possible explanation is that the systemic hormonal response affects preexisting foci of endometriosis and that the ectopic endometrial tissue shows an analogous response to that seen in the uterine endometrium. It usually involutes within four to

six weeks postpartum (3). We present this case because of its similar clinical and histopathological findings with malignancy. We recommend keeping in mind peritoneal deciduositis in differential diagnosis of peritoneal carcinomatosis.

Case

This case is about a 31-year-old, nulliparous woman who was in the first pregnancy. There was no specific feature in history. She was taken to caesarean section optionally through a normal pregnancy. During section, extensive grape-like tan-colored multiple nodular lesions were seen in the abdomen. Biopsies were taken with prediagnosis of peritoneal carcinomatosis.

On gross examination, there were five tissue pieces in tan-white color, elastic consistency, two pieces from uterine peritoneum; of the big one was 1x0.7x0.5 cm in diameter, little one was 1x0.6x0.4 cm in diameter, two

Address for Correspondence/Yazışma Adresi: Nurhan Erzurumluoğlu
Okmeydanı Training and Research Hospital, Clinic of Pathology, İstanbul, Turkey
Phone: +90 212 314 55 55 E-mail: nurhanerzurumlu@hotmail.com

Received/Geliş Tarihi: 11 January 2016 **Accepted/Kabul Tarihi:** 15 January 2016

This study was presented in the 24th National Pathology Congress

*The Medical Bulletin of Haseki Training and Research Hospital,
published by Galenos Publishing.*

Haseki Tıp Bülteni,
Galenos Yayınevi tarafından basılmıştır.

pieces from intestinal wall; of the big one was 1.2x0.6x0.5 in diameter, the little one was 0.2 cm in diameter, one piece from intestinal mesentery was 1.5x1x0.6 in diameter.

On histopathological examination, there were patches of lesions in nodular appearance. The lesions were overlaid by mesothelium at above. Decidua-like cells were at below the lesions. There was no muscle or fat tissue infiltration. Some of these lesions composed of decidual cells that had prominent cell borders, large eosinophilic cytoplasm, coarse nuclei and prominent nucleoli and showed pleomorphism. These lesions were also separated to nodules. There was no desmoid reaction in the stroma (Figure 1). In immunohistochemistry, progesterone receptor (PR) was positive (+++/+++ (strong positive staining in 80% of the cells) (Figure 2). Vimentin, *WT1* and *MUC5AC* were positive, *CKPAN* was negative (Figure 3). *CK8*, *CK19*, spinal muscular atrophy, calretinin, desmin, S100, placental alkaline phosphatase, *BerEp4*, *PAX8* were negatively stained. *CD68* was stained positively in inflammatory cells and negatively in decidual cells and ki-67 proliferation index was about 10% (Figure 4).

Discussion

Ectopic decidua, defined as decidual deposits outside the endometrium, was initially described in 1864, during exploration of two abdominal pregnancies (4).

Its occurrence in non-pregnant women is a rare event, and this diagnosis should trigger an active search

for a source of hormone production, such as exogenous administration of progesterone or a hormone-producing tumor (3).

Decidual cells in peritoneum are found as an incidental finding, but florid deciduosis may be seen at the time of cesarean section or tubal ligation. Clinicians define as multiple, gray-white, sometimes hemorrhagic nodules or plaques on the peritoneal surfaces resembling malignant tumor. In the literature, a few cases have been reported with massive, occasionally fatal, intraperitoneal hemorrhage during the third

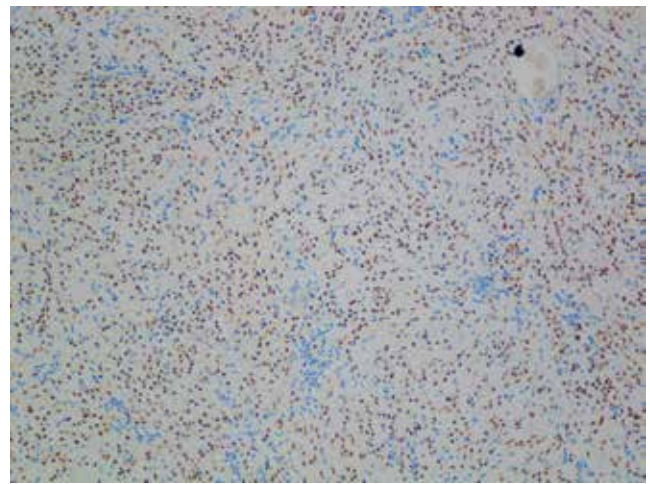


Figure 2. Progesterone receptor positivity in the decidual cells (x100)

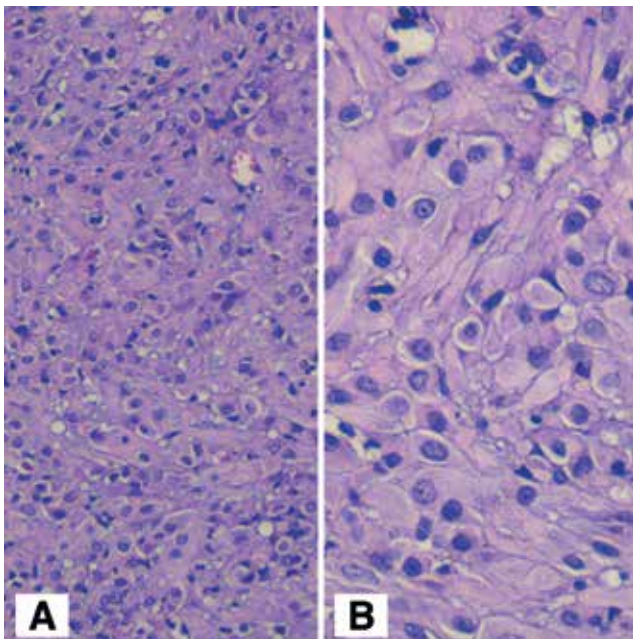


Figure 1. A) Decidual cells that have prominent cell borders, large eosinophilic cytoplasm (H&E, x200), B) Coarse nuclei and prominent nucleoli in the decidual cells (H&E, x400)

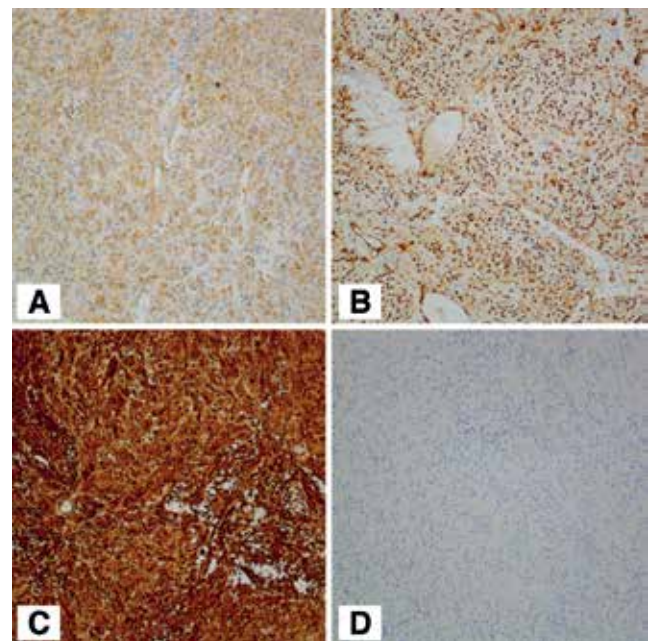


Figure 3. A. *MUC5AC* positivity in the decidual cells B. *WT1* positivity in the decidual cells C. Vimentin positivity in the decidual cells (x100), D. PanCK negative staining in the decidual cells (x100)

trimester. Rarely, abdominal pain, hydronephrosis and hematuria can be seen (5). Our case had a normal pregnancy and the decidual tissue was found in the cesarean section incidentally.

In microscopic examination, decidual cells are usually found under the mesothelial cells in the subcoelomic mesenchymal tissue or in fatty tissue. The lesions are found as small cell nests in the peritoneum in most of the cases, although they are found as widespread florid deciduosis that entirely fills the fatty tissue in 3% of cases (1). Decidua shows features similar to decidualized endometrial stroma, being composed of a well-defined collection of bland-appearing large polygonal cells with distinct cell borders, round, centrally placed nuclei, small nucleoli and abundant eosinophilic cytoplasm (3). Vacuolar degeneration can be seen in decidual cells and is related to the gestational age. A myxoid deposit can be seen in the stroma due to vacuole rupture if the decidual cell cytoplasm vacuolar degeneration is over 50% (1).

The main differential diagnosis for our case was peritoneal carcinomatosis macroscopically and microscopically. Immunohistochemical stains excluded carcinomatosis (negative for pancytokeratin and positive for vimentin). Other differential diagnoses include deciduoid malignant mesothelioma, metastatic malignant melanoma, metastatic signet ring cell carcinoma, and epithelioid leiomyosarcoma.

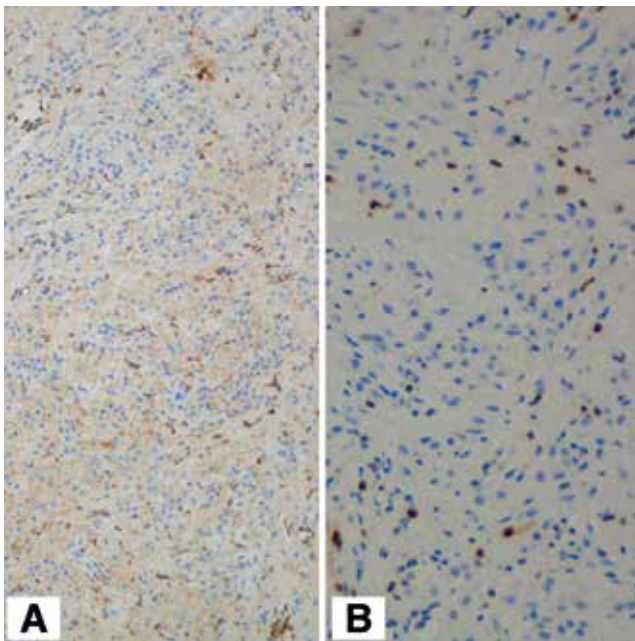


Figure 4. A) CD68 positive in inflammatory cells and negative staining in the decidual cells (x100), B) Ki-67 proliferation index is 10% (x200)

Microscopically, hemorrhagic necrosis, pleomorphism and hyperchromasia in decidual cells may be mistaken for a malignancy such as deciduoid malignant mesothelioma (1,2,5). Clinically absence of malignancy findings, microscopically lack of mitosis in decidual cells and, on immunohistochemical analysis, positive staining with vimentin and PR, negative staining with cytokeratin, calretinin, HBME-1 antibodies support ectopic decidua (1).

Malignant melanoma has been reported on very rare occasions to present as 'peritoneal carcinomatosis' which may typically negative for pancytokeratin and positive for vimentin (6). However, our S100 antibody negativity excluded this possibility.

Signet ring cell carcinomatosis is uncommon carcinoma with several possible primary sites including, but not limited to, gastrointestinal (appendix, stomach) or Müllerian (endocervical) origin. The cells characteristically have eccentrically placed nuclei and a cytoplasm which is filled with mucin. The cells are diffusely infiltrating and can be found as single cells, nests or cords (6). However, in contrast to the cells of the metastatic signet ring cell carcinoma, the vacuoles within the decidual cells contain acid rather than neutral mucin, and their cytoplasm lacks immunoreactivity for cytokeratin (5).

Epithelioid leiomyosarcoma is a rare tumor that is composed of predominantly epithelioid cells rather than spindled smooth muscle cells of the conventional type and has a higher probability of metastatic spread. The cells have a large amount of eosinophilic cytoplasm and can vary in degree of nuclear pleomorphism. Even in the absence of necrosis, increased mitotic activity, nuclear pleomorphism, and vascular invasion microscopically, there is still a risk for metastasis. The tumoral cells are typically positive for smooth muscle markers such as smooth muscle actin and desmin (6).

Conclusion

Ectopic decidua is a benign condition and resolves without any treatment in the postpartum period and must be considered firstly in all incidentally detected peritoneal nodules.

Ethics

Ethics: Need for ethical confirmation was discussed with the Clinical trials Ethics Committee of Okmeydanı Training and Research Hospital verbally and the answers from members was that since the study is a case report and has been done retrospectively from archive slides, no written confirmation from ethics committee is needed. Informed Consent: Since the case report is a retrospective type of study and no new information about the patient

was used or markers were done on biopsy materials, informed consent from the patient wasn't needed.

Peer-review: Internal peer-reviewed.

Authorship Contributions

Surgical and Medical Practices: The paraffin blocks of the case report was a consultation from outer hospital and no information about the surgeon was written on the request forms. Concept: Nurhan Erzurumluoğlu. Design: Nurhan Erzurumluoğlu, Aytül Sargan. Data Collection or Processing: Nurhan Erzurumluoğlu, Fetin Rüştü Yıldız. Analysis or Interpretation: Nurhan Erzurumluoğlu, Selver Özekinci. Literature Search: Nurhan Erzurumluoğlu. Writing: Nurhan Erzurumluoğlu.

Conflict of Interest: No conflict of interest was declared by the authors.

Financial Disclosure: The authors declared that this study received no financial support.

References

1. Bolat F, Canpolat T, Tarım E. Pregnancy-related peritoneal ectopic decudua (Deciduosis): Morphological and clinical evaluation. *Turk Patoloji Derg* 2012;28:56-60.
2. Shukla S, Pujani M, Singh SK. Ectopic decidual reaction mimicking peritoneal tubercles: A report of three cases. *Indian J Pathol. Microbiol* 2008;51:519-20.
3. Nascimento AF, Nucci MR. Disorders of the Peritoneum. In: Crum CP, Nucci MR, Lee KR, editors. *Diagnostic Gynecologic and Obstetric Pathology*. 2nd ed. Philadelphia: Elsevier;2011. p.717-57.
4. Wu DC, Hirschowitz S, Natarajan S. Ectopic decudua of pelvic lymph nodes, a potential diagnostic pitfall. *Arch Pathol Lab Med* 2005;129:117-20.
5. Irving JA, Clement PB. Disease of the Peritoneum. In: Kurman RJ, Hedrick L, Ronnet BM, editors. *Blaustein's Pathology of the Genital Tract*. 6th ed. London: Springer; 2011. p.625-79.
6. Adhikari LJ, Shen R. Florid diffuse peritoneal decuduosis mimicking carcinomatosis in a primigravida patient: A case report and review of the literature. *Int J Clin Exp Pathol* 2013;6:2615-9.