

Fetal pulmonary injury following single high-dose intra-amniotic betamethasone treatment in preterm goat kids

Preterm keçi yavrusunda tek ve yüksek doz intra-amniyotik betametazon tedavisi sonrasında fetal pulmoner zedelenme

Meltem Antalyalı¹, Özlem Özmen², Mehmet Haligür², Mekin Sezik¹

¹Department of Gynecology and Obstetrics, Faculty of Medicine, Süleyman Demirel University, Isparta, Turkey

²Department of Pathology, Faculty of Veterinary Medicine, Mehmet Akif Ersoy University, Burdur, Turkey

Abstract

Objective: Fetal lung maturation is an extremely important process that is necessary for the survival of the neonates. Conventionally, corticosteroids are administered maternally for inducing fetal lung maturation in preterm fetuses. Alternatively, single-dose intra-amniotic (IA) treatment might be speculated to improve lung maturity. In the goat model, we recently showed that high-dose IA betamethasone (BM) was associated with an increased number of stillbirths and emphysematous changes. The aim of the present study is to expand our previous findings and evaluate the histopathological effects of IA injection of a single high-dose of BM 48 h before induced preterm delivery, using our previously collected specimens.

Material and Methods: Five hair goat fetal lungs that had received 8 mg/kg IA BM at gestational day 118 (term, 150 days) and scheduled for preterm delivery by cesarean section at day 120 of gestation were examined pathologically. Specimens were stained with hematoxylin and eosin (HE) and were interpreted by light microscopy.

Results: The histopathological examination of the fetal lungs revealed edema, hemorrhage, slight inflammatory reaction, marked emphysema, and desquamation of the pneumocytes and bronchiolar or bronchial epithelial cells.

Conclusion: High-dose IA BM administrations to induce lung maturation can paradoxically cause severe pathological lesions in the fetal lungs. These might explain the toxic effects we encountered with this mode of treatment. (J Turkish-German Gynecol Assoc 2012; 13: 242-6)

Key words: Animal models, betamethasone, corticosteroids, intra-amniotic, lung maturation

Received: 28 July, 2012

Accepted: 03 October, 2012

Özet

Amaç: Fetal akciğer matürasyonu, yenidoğan sağkalımı için zarurî olan çok önemli bir süreçtir. Kortikosteroidler, mutlak olarak preterm fetüste akciğer matürasyonunu sağlamak için anneye uygulanmaktadır. Bunun yerine, tek doz intra-amniyotik (İA) tedavinin de akciğer matüratesini artıracığı ileri sürülebilir. Keçi modelindeki en son çalışmamızda, yüksek doz İA betametazonun (BM) ölü doğumlarda artış ve amfizematöz değişiklikler ile ilişkili olduğunu gösterdik. Mevcut çalışmadaki amacımız; önceki bulgularımızı genişleterek, indüklenmiş preterm doğumdan 48 saat önce tek ve yüksek dozda İA BM sonrasında, elimizdeki materyaller üzerinde histopatolojik değişikliklerin gösterilmesidir.

Gereç ve Yöntemler: Gebeliğin 118. gününde (term, 150 gün) 8 mg/kg İA BM verilen ve 120. günde sezaryen ile preterm doğum planlanan beş kıl keçisi fetüsüne ait akciğerler patolojik incelemeye alındı. Numuneler hematoksilin ve eozin (HE) ile boyanarak ışık mikroskopisi altında değerlendirildi.

Bulgular: Fetal akciğerlerin histopatolojik incelemesinde ödem, kanama, hafif enflamatuvar reaksiyon, belirgin amfizem ve pnömositler ile bronşiyolar veya bronşiyal epitelyum hücrelerinin deskumasyonu saptandı.

Sonuç: Akciğer matürasyonu sağlamak için yüksek doz İA BM uygulanması, beklenmedik şekilde fetal akciğerlerde ağır patolojik lezyonlara neden olabilir. Mevcut bulgular, bu tarz tedaviye bağlı toksik bulguların açıklanmasını sağlayabilir.

(J Turkish-German Gynecol Assoc 2012; 13: 242-6)

Anahtar kelimeler: Hayvan modeli, betametazon, kortikosteroid, intra-amniyotik, akciğer matürasyonu

Geliş Tarihi: 28 Temmuz 2012

Kabul Tarihi: 03 Ekim 2012

Introduction

The pulmonary system is among the last of the fetal organ systems to mature, both functionally and structurally. Because the immature pulmonary system may not oxygenate the neonate adequately, preterm birth can lead to significant

neonatal morbidity or mortality (1). Reduced lung function during infancy has been shown in association with preterm birth, probably persisting through adulthood (2-4). Immature lungs may increase the risk of respiratory distress and death among both term and preterm infants during the neonatal period (2). Moreover, low birth weight secondary to preterm

delivery has been associated with reduced lung function and increased death rates from chronic obstructive airway disease in adult life (4).

Animal studies and clinical human data have revealed that fetal lung maturation takes place after maternal corticosteroid administration (5). In line with this, elevated cortisol levels have been shown to enhance lung maturation (6). However, the efficacies of various corticosteroid analogs, total dose, dosing intervals, and the means of administration for fetal lung maturation have not been exactly defined. Alternative routes of administration, such as the IA route might be hypothesized to be more effective than the standard maternal method of administration. Our previous animal study showed that the dose and the application route of betamethasone (BM) are particularly important for fetal lung maturation (7). In the mentioned investigation (7), we proposed that higher (than that of previously used) doses of IA can be an attractive treatment option to induce improved antenatal lung maturation. However, we found that a high (8 mg/kg) dose of intra-amniotic (IA) and fetal i.m. (4 mg/kg) BM was not superior to the standard dose and the maternal route of administration in the goat model. Moreover, IA BM was associated with an increased number of stillbirths and macroscopic emphysematous changes, compared to controls. Despite these toxic effects, detailed histopathological examination of the fetal lungs was not included in this previous paper (7), and we were not able to identify the exact underlying mechanisms of pulmonary injury following the IA route.

Here, we report the detailed histopathological findings in the fetal lungs of kids that we gathered from our previous experimental design. These were antenatally treated with high-dose (8 mg/kg of estimated fetal weight) IA BM. Our aim was to delineate the causes for the unexpected toxic effect we encountered following high-dose IA therapy.

Material and Methods

All the experiments were approved by the institutional animal use and care committee at Süleyman Demirel University and performed in accordance with the National Institute of Health Guidelines for the Care and Handling of Animals. The number of animals was restricted ($n=5$), as suggested by the animal ethics committee. Details of the procedures were described thoroughly in our previous study (7). Briefly, five female hair goats (*Capra hircus*), 2 to 4 years old and 40 ± 5 kg in weight were used for the study. Goats were fed on standard feed and tap water ad libitum. A singleton structurally normal ongoing pregnancy was confirmed by ultrasonography (Echo Camera SSD-500, Aloka, Tokyo, Japan) at gestational days 60, 75, and 90 (term pregnancy, 150-155 days). At day 118, amniocentesis with a 21 G needle under ultrasound guidance was performed (Figure 1). Betamethasone disodium phosphate plus betamethasone acetate (Celestone chronodose amp, Schering-Plough Inc, İstanbul, Turkey) equivalent to 8 mg/kg of estimated fetal weight was injected into the amniotic sac. Subsequently, at day 120, excluding the stillborn kids, cesarean section (CS) with paralumbal skin and dorsal curvature uterine incision was performed under sterile conditions at gestational day 120 (cor-

responding to 31-32 weeks of gestation in human pregnancy). Details of the operation are provided elsewhere (8).

After preterm delivery, the kids were euthanized with high-dose (50 mg/kg) sodium thiopental (Pental Sodyum, IE Ulugay, İstanbul, Turkey) administered via the umbilical catheter, the trachea was clamped for 3 min to maintain airway pressure and necropsy performed. At macroscopic examination, any visible lung rupture or pulmonary interstitial emphysema was recorded. The lungs were excised en bloc, the trachea removed to the bifurcation and their wet weight was measured (Figure 2). The lungs were then fixed by 10% formalin inflation into the airways, and fixation continued in formalin for three days. Five different samples were taken from all of the lungs (left apical, left diaphragmatic, right apical, right cardiac and right diaphragmatic lobes). Then, tissue samples were routinely processed, paraffin embedded and cut into 5 mm sections, and slides were stained with hematoxylin and eosin (HE) to be interpreted by

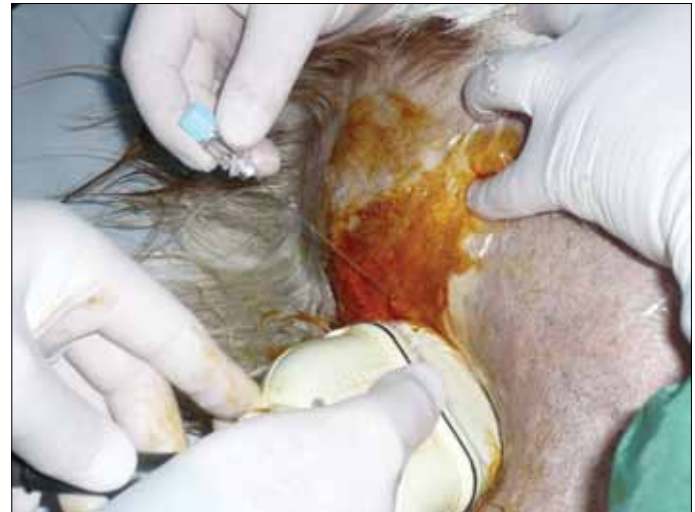

Figure 1. The amniocentesis procedure

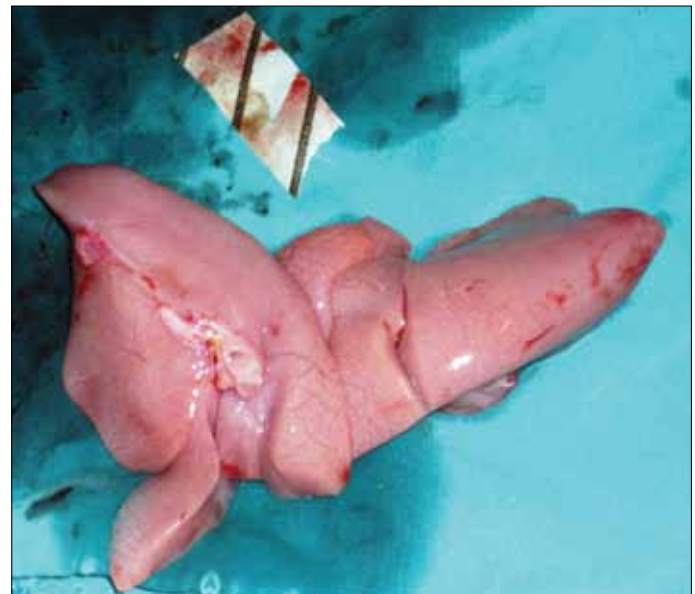

Figure 2. Excised fetal lungs following preterm delivery

light microscopy. Histopathological changes were examined in a blinded manner under the 40x objective of a Nikon E-600 trinocular microscope and microphotography apparatus.

Results

There were 3 stillbirths out of 5 fetuses that were given IA BM. The fetal lungs from one of those kids could not be examined because of a severe autolytic reaction, probably secondary to significant trauma by other goats nearby following stillbirth. The histopathological observation of the remaining fetal lungs (a total of 8 gross specimens from 4 fetuses) revealed edema, slight inflammatory reaction, hemorrhage, marked emphysema, and desquamation of the pneumocytes (Figures 3-5). Edema was typically localized around the vessels at the interstitial tissue. Protein-rich eosinophilic edema fluid was also

present in some alveolar spaces. Slight neutrophilic and mononuclear inflammatory cells were evident around the pulmonary vasculature and around bronchioles. Marked increase in alveolar macrophages was a prominent finding in the alveolar lumens. Severe desquamation was observed in alveolar cells. In addition to alveolar cells, desquamation was also prominent in bronchiolar and bronchial epithelial cells.

Pulmonary lesions were more severe in specimens from stillbirths compared to live births. Marked areas of hemorrhage and edema were common findings in stillborn kids. Thickening at the septal areas due to edema and inflammatory cell infiltrations were also characteristic in these kids. Some of the alveolar spaces were filled with desquamated epithelial cells and inflammatory cells. Atelectatic areas were also commonly encountered in fetuses with stillbirth (Figures 6, 7).

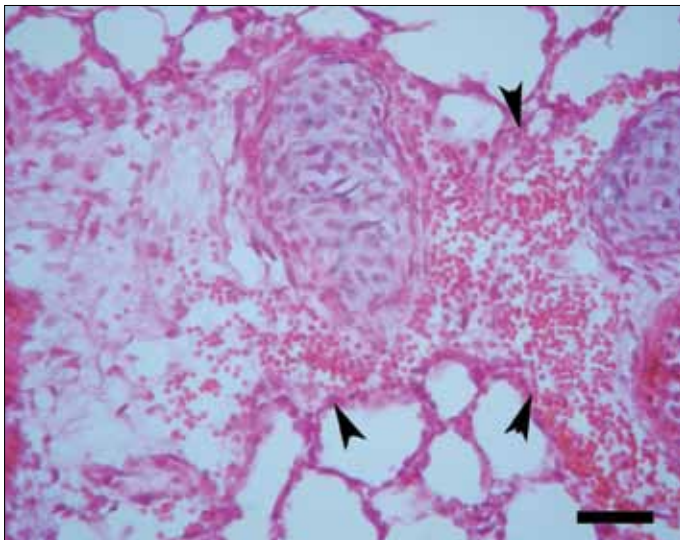


Figure 3. Histopathological appearance of the lungs of a kid showing severe hemorrhage in septal tissue around the bronchi (arrow heads), HE, Bar=50 μ m

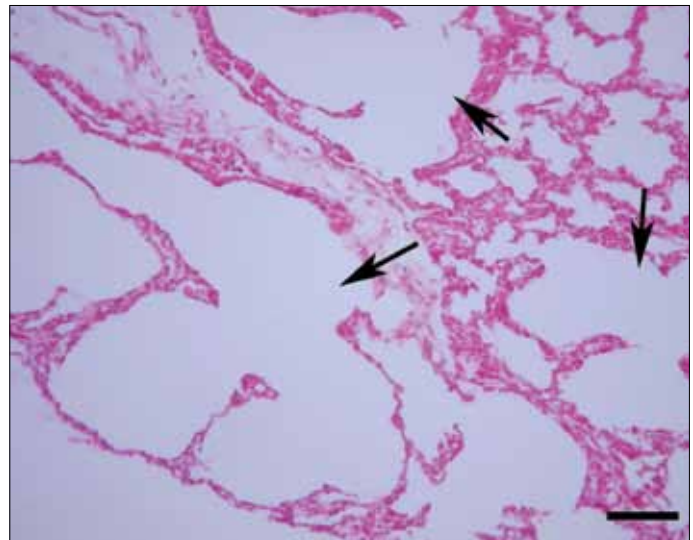


Figure 5. Severe alveolar emphysema (arrows) in the lungs of a kid, HE, Bar=100 μ m

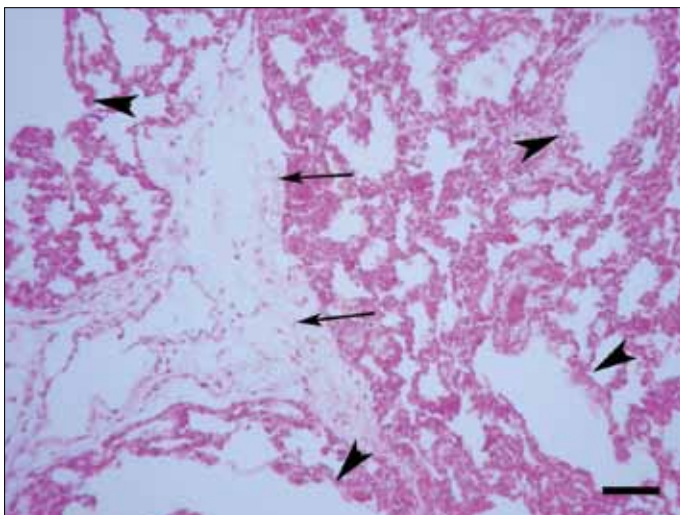


Figure 4. Severe emphysemic areas (arrow heads) and edematous interstitial tissue (arrow) in a kid, HE, Bar=100 μ m

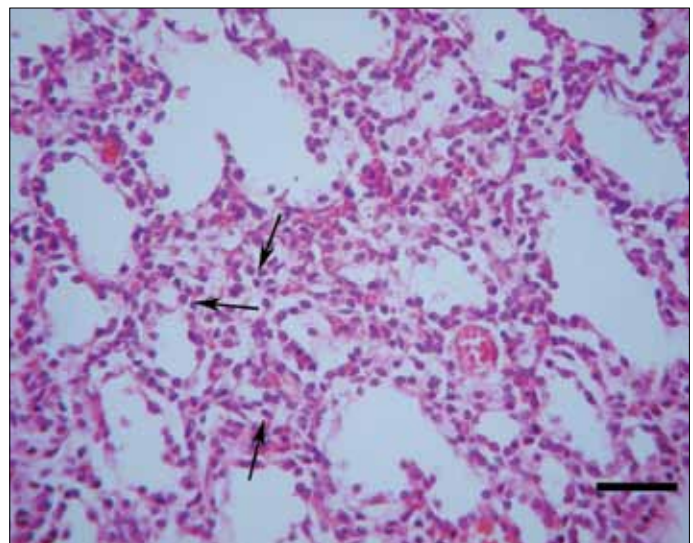


Figure 6. Inflammatory reaction (arrows) in a lung of a stillborn kid, HE, Bar=50 μ m

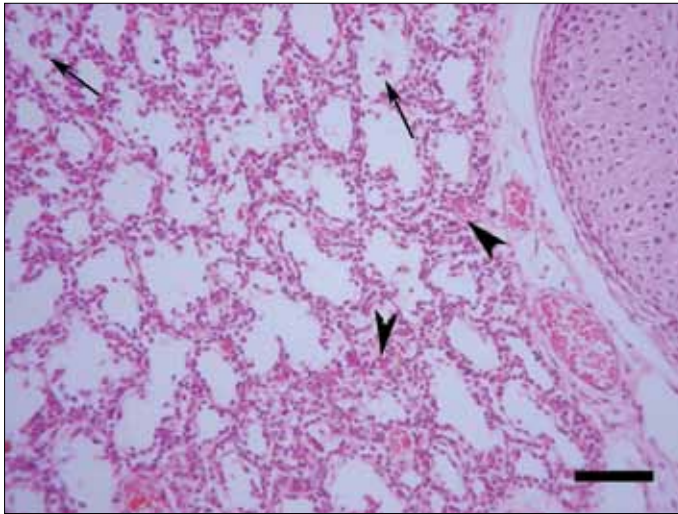


Figure 7. Desquamation of the epithelial cells (arrows) and atelectatic areas (arrow heads) in the lungs of a stillborn kid, HE, Bar=100 μ m

Discussion

High-dose IA treatment with BM was unexpectedly associated with fetal losses (60%) and pulmonary injury in our design (7). In fact, scarce small ruminant animal data in the English language literature, disclosing 50% prenatal loss rate with >2 mg/kg estimated fetal weight of intra-amniotically administered BM, confirms our results (9). Interestingly, lower doses (0.5 mg/kg estimated fetal weight) of IA BM were not associated with stillbirths (0/9 lambs) in the mentioned study (9). In another investigation on fetal baboons, 6 mg (fixed dose) IA BM at four and again at three days prior to preterm delivery was reported to significantly increase the amniotic fluid lecithin/sphingomyelin ratio (10). The immature fetal baboon pulmonary system was shown to respond to IA BM with improved pulmonary stability but not with a synchronous increase in tissue distensibility (10). Although limited available data on low-dose IA BM indicates certain favorable effects, lower doses were shown to induce inadequate fetal lung maturation, especially when compared with the conventional maternal route of administration (9). Therefore, we had speculated that a single high-dose BM administered into the amniotic fluid would lead to effective drug concentrations in the fetal alveolar fluid and pulmonary tissues, which are actually the primary target of treatment. However, our histopathological data indicated toxic effects associated with prominent pulmonary injury at this high dose. We could locate only one prior investigation on pulmonary histological changes following low-dose (2 mg/kg estimated fetal weight) IA BM or budesonide (11). The authors showed that IA corticosteroids, 2 or 7 days before preterm delivery in lambs, resulted in thinning of alveolar walls with a higher proportion of alveolar ducts and a lower alveolar wall fraction relative to controls. These favorable changes were correlated with improved lung function and increased surfactant (11). As we did not observe similar favorable morphometric changes, the dose we used in our design is probably toxic and conveys no additional benefit.

BM given intra-amniotically at high doses (>2mg/kg) can be speculated to be absorbed by the chorioamniotic membranes and perhaps by the fetal surface of the placenta, leading to reabsorption by the fetus. Following reabsorption in a cyclic manner, BM would be expected to accumulate toxic levels in the fetus. This toxic accumulation probably initiates lung injury and finally causes fetal death. Some fetuses tend to demonstrate an exaggerated response with prominent edema and inflammation, as supported by our findings from stillbirths. Another possibility, however, is the emergence of such histopathological characteristics following fetal loss. This may be unlikely, as the specimens were available in a short time after fetal loss except in one case, which was excluded from analysis.

Septal thickening was an important histopathological feature that we encountered. In contrast, low (2 mg/kg) doses of IA BM were reported to be associated with thinning of alveolar walls, which is a favorable finding for lung maturation. Therefore, IA BM at very high doses (8 mg/kg) not only causes lung injury but also disturbs normal fetal lung maturation. It must, however, be noted that even standard doses of BM administered maternally for fetal lung maturation can induce certain adverse histopathological changes. For example, the results of a pregnant sheep model indicated that 70% of lambs delivered at 128 days of gestation, 24h after a single injection of 0.5 mg/kg maternal i.m. BM developed pulmonary interstitial emphysema, compared with fewer than 5% of control animals (12).

Our data from the present design would be insufficient to explain the exact mechanisms and causes of increased fetal death rate (60%) following high-dose IA BM, as we do not have specimens from other organs. However, toxicity caused particularly by BM in other organ systems, including the fetal central nervous system, can be expected. At this stage, we do not know whether these unfavorable effects on the fetus are specific for BM or whether they can be generalized to other glucocorticoids.

Budesonide is a steroid derivative with minimal systemic absorption and almost no placental transfer. Budesonide is conventionally used as an oral inhalant in the treatment of childhood asthma. Limited data from animal (sheep) experimentation reveals no perinatal loss with relatively high doses of IA budesonide administration; moreover, its pulmonary maturational effects were reported to be comparable to the standard maternal BM therapy (9, 11). Hence, budesonide and other corticosteroids with minimal absorption and limited toxicity can be candidates for fetal therapy, including IA administrations. Further experimental studies will be needed on IA budesonide therapy.

Conclusion

High-dose IA BM causes severe pathological lesions, including edema and hemorrhage in the fetal lungs. These changes may elucidate the toxic effects and increased fetal losses we encountered with this mode of treatment.

Acknowledgements: This research was supported by a grant from the Scientific and Technological Research Council of Turkey (grant no. 110S260)

Conflict of interest

No conflict of interest was declared by the authors.

References

1. Parilla BV, Dooley SL, Jansen RD, Socol ML. Iatrogenic respiratory distress syndrome following elective repeat cesarean delivery. *Obstet Gynecol* 1993; 81: 392-5.
2. Bernstein IM, Horbar JD, Badger GJ, Ohisson A, Golan A. Morbidity and mortality among very-low-birth-weight neonates with intrauterine growth restriction. *Am J Obstet Gynecol* 2000; 182: 198-206. [\[CrossRef\]](#)
3. Rona RJ, Gulliford MC, Chinn S. Effects of prematurity and intra-uterine growth on respiratory health and lung function in childhood. *BMJ* 1993; 306: 817-20. [\[CrossRef\]](#)
4. Stein CE, Kumaran K, Fall CH, Shaheen SO, Osmond C, Barker DJ. Relation of fetal growth to adult lung function in South India. *Thorax* 1997; 52: 895-9. [\[CrossRef\]](#)
5. Sweet DG, Huggett MT, Warner JA, Moss TJM, Kloosterboer N, Halliday HL, et al. Maternal betamethasone and chorioamnionitis induce different collagenases during lung maturation in fetal sheep. *Neonatology* 2008; 94: 79-86. [\[CrossRef\]](#)
6. Merrill JD, Ballard RA. Antenatal hormone therapy for fetal lung maturation. *Clin Perinatol* 1998; 25: 983-97.
7. Sezik M, Antalyali M, Ozmen O, Haligur M, Koker A, Ozkaya O, et al. Ultra-high dose of intra-amniotic or direct fetal intramuscular betamethasone for lung maturation in the preterm goat model. *Eur J Obstet Gynecol Reprod Biol.* 2012; 164: 15-23. [\[CrossRef\]](#)
8. Sezik M, Ozkaya O, Arslanoglu E, Koker A, Cetin H, Ozbasar D, et al. Evaluation of intra-amniotic surfactant administration for lung maturation in preterm sheep. *J Exp Anim Sci* 2007; 43: 301-7. [\[CrossRef\]](#)
9. Moss TJ, Mulrooney NP, Nitsos I, Ikegami M, Jobe AH, Newnham JP. Intra-amniotic corticosteroids for preterm lung maturation in sheep. *Am J Obstet Gynecol* 2003; 189: 1389-95. [\[CrossRef\]](#)
10. Kotas RV, Kling OR, Block MF, Soodsma JF, Harlow RD, Crosby WM. Response of immature baboon fetal lung to intra-amniotic betamethasone. *Am J Obstet Gynecol* 1978; 130: 712-7.
11. Polglase GR, Nitsos I, Jobe AH, Newnham JP, Moss TJ. Maternal and intra-amniotic corticosteroid effects on lung morphometry in preterm lambs. *Pediatr Res* 2007; 62: 32-6. [\[CrossRef\]](#)
12. Willet KE, Jobe AH, Ikegami M, Newnham J, Sly PD. Pulmonary interstitial emphysema 24 hours after antenatal betamethasone treatment in preterm sheep. *Am J Respir Crit Care Med* 2000; 162: 1087-94.