



# Long-term Results in Pediatric Developmental Cataract Surgery with Primary Intraocular Lens Implantation

Elif Demirkılınç Biler\*, Şeyda Yıldırım\*\*, Önder Üretmen\*, Süheyla Köse\*\*\*

\*Ege University Faculty of Medicine, Department of Ophthalmology, İzmir, Turkey

\*\*Adıyaman University Research and Training Hospital, Department of Ophthalmology, Adıyaman, Turkey

\*\*\*Private Practice, İzmir, Turkey

## Abstract

**Objectives:** The aim of this study was to evaluate the outcomes of pediatric developmental cataract surgery with primary intraocular lens (IOL) implantation.

**Materials and Methods:** Patients between 2 and 16 years old who underwent cataract surgery with primary IOL implantation were retrospectively evaluated. Age at time of surgery, pre- and postoperative best corrected visual acuities, postoperative ocular complications, and any accompanying ocular pathologies were obtained from the patients' charts. Mean refractive changes and degree of myopic shift were analyzed according to the age groups. Operated eyes were also compared with the fellow eyes in unilateral cases.

**Results:** A total of 101 eyes of 65 patients were included. The average age at time of surgery was  $76 \pm 40$  months and the average follow-up period was  $44 \pm 30$  months. Among the 78 eyes that could be assessed for visual acuity improvement, 66 (84.6%) of them showed  $\geq 2$  lines of improvement. The difference in the mean refractive change between the 2-5 years old and 8-16 years old age groups was found to be statistically significant. However, the mean refractive change per year was not found to be significant between the same age groups. In unilateral cases, the operated eyes showed a greater myopic change than the fellow eyes, with no statistically significant difference. The most common postoperative complication was visual axis opacity.

**Conclusion:** Good visual outcomes can be achieved following pediatric cataract surgery with primary IOL implantation. Optic axis opacities were the most common postoperative complications. Overall, refractive changes following surgery are inevitable, and more prominent in younger age groups.

**Keywords:** Pediatric cataract surgery, myopic shift, primary intraocular lens implantation, pseudophakic glaucoma, visual axis opacity

## Introduction

Pediatric cataract surgery offers unique challenges when compared to adult cataract surgery. These difficulties result from differences in the surgical technique, types of complications, and prevalence.<sup>1</sup> Pediatric aphakia can lead to a group of problems, such as anisometropic amblyopia, posterior capsular opacification, glaucoma, strabismus, and loss of binocular function.<sup>2</sup> Due to advances in operative techniques, an increasing number of ophthalmologists have accepted primary intraocular lens (IOL) implantation as a mode of aphakic rehabilitation in recent years.<sup>3,4,5,6</sup> For children older than 2 years who underwent cataract surgery, IOL implantation is considered to be the gold standard

by most authors.<sup>7</sup> However, although IOL implantation is the standard of care for adult patients, the minimum recommended age for implantation in children remains controversial.<sup>1,7</sup> Because the pediatric eye is still developing, refractive changes occur during the postoperative childhood or adolescent years in patients who underwent IOL implantation for cataracts.<sup>8,9</sup> Moreover, varying degrees of refractive myopic shift after pediatric cataract surgery and IOL implantation have been reported, with a moderate amount of individual variability.<sup>4,8,9,10,11,12,13</sup> A postoperative increased inflammatory response in children is another serious problem which can lead to fibrinous reactions, pigment deposits on the IOL, decentration of the IOL, and posterior synechiae.<sup>14</sup>

**Address for Correspondence:** Elif Demirkılınç Biler MD, Ege University Faculty of Medicine, Department of Ophthalmology, İzmir, Turkey  
Phone: +90 232 390 35 94 E-mail: elif.dem@gmail.com ORCID-ID: orcid.org/0000-0002-3741-1191

**Received:** 22.01.2017 **Accepted:** 07.06.2017

©Copyright 2018 by Turkish Ophthalmological Association  
Turkish Journal of Ophthalmology, published by Galenos Publishing House.

This study was designed to evaluate the postoperative outcomes, such as visual acuity improvement, refractive changes, myopic shift, complications, and additional surgical interventions, following pediatric developmental cataract surgery with primary IOL implantation.

### Materials and Methods

This was a retrospective study carried out on 65 consecutive pediatric patients between 2 and 16 years of age with developmental cataracts, who underwent cataract surgery with primary IOL implantation between January 1998 and May 2014 at the Ege University Faculty of Medicine, Department of Ophthalmology. All of the patients were followed for at least 6 months postoperatively. Eyes with cataracts due to trauma, surgery, or any other ocular pathologies were excluded from this research.

Data were collected from the patients' charts, including gender, age at time of cataract surgery, laterality, surgical procedure, best corrected visual acuity (BCVA) via Snellen chart, the presence, type, and amount of ocular deviation, cycloplegic refraction, slit-lamp examination, fundus examination and B-scan ultrasonography (if needed), IOP measurement, the course of amblyopia therapy, and postoperative complications and management. Axial length measurement (Sonogage Eye Scan, Cleveland, OH, USA) and keratometric evaluation (Topcon KR-7000P; Topcon Europe BV, Netherlands) were performed preoperatively to calculate the IOL power. Because the postoperative myopic shift was anticipated, the postoperative refraction was targeted to be hyperopic in concordance with a survey performed among the members of the American Association for Pediatric Ophthalmology.<sup>6</sup> The age-adjusted target refractions were calculated as recommended by Enyedi et al.<sup>9</sup> We aimed for a postoperative refractive goal of +6 for a 1-year-old, +5 for a 2-year-old, +4 for a 3-year-old, +3 for a 4-year-old, +2 for a 5-year-old, +1 for a 6-year-old, and emmetropia for older ages. The SRK/T formula was used as recommended in a recent infant aphakia treatment study.<sup>15</sup>

All of the surgeries were performed under general anesthesia by one of the authors (E.D.B., O.U., or S.K.). The operative method involved two 1.1-mm side port incisions, anterior microcapsulorrhexis, hydrodissection, phacoaspiration, an additional 3.2-mm corneal incision, and in-the-bag hydrophilic acrylic IOL implantation. If the patient was younger than 5 years old, had mental retardation, or cooperated poorly, a routine posterior capsulorrhexis combined with anterior vitrectomy was performed. In the other cases, the posterior capsule was left intact. Posterior capsulotomy combined with anterior vitrectomy was not performed in 4 children <5 years old who were cooperative enough to undergo Nd:YAG laser capsulotomy. The incisions were closed with 10-0 nylon sutures.

Prescriptions for postoperative topical tobramycin and dexamethasone sodium phosphate every two hours, and cyclopentolate hydrochloride three times each day were tapered during the first postoperative month. All of the patients were

routinely examined 1 day and 5 days after surgery, then once a week for 1 month, every 1-3 months during the first year, then every 6 months during the postoperative follow-up period. The extra visits and routine follow-up visit intervals were arranged for each patient individually. Amblyopia therapy was carried out as needed. During every postoperative visit, a comprehensive ophthalmologic examination was repeated, including BCVA, refractive assessment, evaluation of ocular deviation, IOL measurement, and slit-lamp and fundus examinations.

For the analysis, the patients were divided into 3 groups according to their age at surgery: 2 to 5 years old, 5 to 8 years old, and 8 to 16 years old. All of the refractive data represented the spherical equivalent refraction (sphere plus one-half of the cylinder). Moreover, the eyes with unilateral cataracts were compared with the normal fellow eyes according to the mean refractive changes during the follow-up period.

### Statistical Analysis

Statistical analysis was performed with SPSS for Windows version 18.0 (SPSS Inc., Chicago, IL, USA). All of the data were reported as the average ± standard deviation. Statistical comparisons were performed with the Mann-Whitney U and Student's t-tests, and a p value of <0.05 was considered to be statistically significant.

The research protocol adhered to the Declaration of Helsinki for research involving human subjects. All of the parents or guardians of the children studied provided written consent to the screening and follow-up assessments.

### Results

A total of 101 eyes of 65 patients were included in this study; 36 patients had bilateral cataract surgery. The average age at the time of surgery was 76±40 months (range 25-192 months) and the average follow-up time was 44±30 months (range 6-174 months). Both the pre- and postoperative visual acuities (Snellen chart) could be evaluated in 78 eyes of 52 patients. BCVA improved by ≥2 lines in 61 eyes (78.2%), and improved by 1 line in 6 eyes at the last follow-up when compared with their preoperative measurements. Six of the eyes showed no changes in visual acuity. At the last follow-up, 71 eyes of 47 patients had visual acuities of ≥0.5.

The visual acuity improvements were also analyzed according to laterality (Table 1). Among those patients who had unilateral cataract surgery, visual acuity improvement could be assessed in

**Table 1. Best corrected visual acuity improvements according to laterality**

	BCVA improvement			
	No change	1 line	2 lines	>2 lines
All (78 eyes)	6 (7.7%)	6 (7.7%)	5 (6.4%)	61 (78.2%)
Unilateral (26 eyes)	5 (19.2%)	2 (7.7%)	3 (11.5%)	16 (61.6%)
Bilateral (52 eyes)	1 (1.9%)	4 (7.7%)	2 (3.9%)	45 (86.5%)

BCVA: Best corrected visual acuity

26 eyes. BCVA improved by  $\geq 2$  lines in 19 eyes (73.1%) and by 1 line in 2 eyes at the last follow-up when compared with their preoperative measurements; however, 5 eyes showed no changes in visual acuity. The visual acuity improvement could be evaluated in 52 eyes of 26 patients among the 36 patients who had bilateral cataract surgery. The BCVA improved by  $\geq 2$  lines in 47 eyes (90.4%), and improved by 1 line in 4 eyes at the last follow-up when compared with preoperative measurements. One eye showed no change in visual acuity.

Ten patients had monocular sensory strabismus preoperatively. The visual acuity improvement could be assessed in 7 of the 10 patients with monocular strabismus. In 6 eyes (85.7%), BCVA improved by  $\geq 2$  lines. Three patients had nystagmus preoperatively. One of them had an improvement of  $\geq 2$  lines in both eyes.

Among 42 children (64.6%) that were prescribed occlusion therapy after surgery, 36 could be evaluated during the follow-up period with regard to their visual acuity improvement; 18 (50%) showed  $\geq 2$  lines of improvement in response to the occlusion therapy.

The patients were divided into 3 groups according to their ages at time of surgery: 43 eyes of 25 patients 2 to 5 years old in the first group, 28 eyes of 18 patients 5 to 8 years old in the second group, and 30 eyes of 22 patients 8 to 16 years old in the third group. Refractive changes were analyzed according to these

age groups (Table 2). The mean refractive change and refractive change per year of follow-up were calculated among only the cases with myopic shift. Although these values were observed to be greatest in the younger age groups, only the difference in the mean refractive change between the 2-5 years old and 8-16 years old age groups were found to be statistically significant ( $p=0.009$ ). However, the mean refractive change per year was not significant between the 2-5 years old and 8-16 years old age groups ( $p=0.335$ ).

In the unilateral cases, the operated eye showed a greater mean refractive change and greater mean refractive change per year. However, there was no significant difference between the operated and nonoperated eyes regarding the mean of these values (mean refractive change  $-1.05 \pm 1.64$  vs.  $-0.58 \pm 0.66$ , mean refractive change per year  $-0.36 \pm 0.87$  vs.  $-0.22 \pm 0.53$ ;  $p$  values 0.18 and 0.48, respectively).

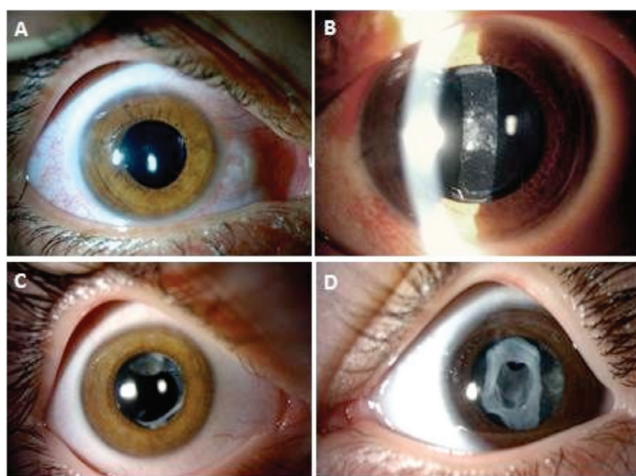
No intraoperative complications were observed. In 52 of 101 eyes, at least one postoperative complication was observed during the follow-up period. The most common ocular complication was visual axis opacity, which was observed in 49 eyes, including posterior capsule opacification (PCO) in 23 eyes (22.8%), secondary membrane or lens reformation in 15 eyes, and capsular phimosis in 11 eyes.

Posterior capsulotomy and anterior vitrectomy were performed in 67 eyes. Visual axis opacification (PCO in 11 eyes, secondary membrane or lens reformation in 4 eyes, and capsular phimosis in 8 eyes) was seen in 23 of those 67 eyes (34.3%) and 15 of them required additional intervention (22.3%). Among 34 eyes without primary posterior capsulotomy, visual axis opacification (PCO in 22 eyes, secondary membrane or lens reformation in 1 eye, and capsular phimosis in 3 eyes) was observed in 26 eyes (76.4%) and 22 of them required further intervention (64.7%) (Figure 1).

Pediatric pseudophakic glaucoma was observed in 2 eyes (1.98%), and medical antiglaucomatous treatment was effective in both cases.

## Discussion

In this study, we reported good visual outcomes after cataract surgery with primary IOL implantation in pediatric patients between 2 and 16 years of age. We were able to assess the visual acuity changes after surgery in 78 eyes, and of those, 72 eyes (92.3%) showed improvements in visual acuity. In a study by Kleinman et al.<sup>1</sup>, the authors reported that over 80% of the eyes had improvements in visual acuity, and more than 50% of the



**Figure 1.** Postoperative images of patients with A) no complication; B) posterior capsular opacification; C) capsular phimosis and lens reformation; and D) secondary membrane formation

**Table 2. Refractive changes during the follow-up period in age groups**

Age at surgery (years)	n (eye)	Myopic shift	Mean refractive change (D)	Mean follow-up time (years)	Mean refractive change (D) per year
2-5	43	38/43 (88.4%)	$-2.6 \pm 2.4$ (-8.63 to -0.12)	$4.3 \pm 3.0$ (13-174 months)	$-0.69 \pm 0.55$
5-8	28	21/28 (75%)	$-1.45 \pm 0.97$ (-3.87 to -0.12)	$3.4 \pm 2.3$ (6-87 months)	$-0.57 \pm 0.45$
8-16	30	16/30 (53.3%)	$-1.37 \pm 1.13$ (-5.12 to -0.12)	$2.9 \pm 1.5$ (9-65 months)	$-0.51 \pm 0.48$

eyes achieved visual acuities of  $\geq 20/40$  at the last follow-up. In another study by Crouch et al.<sup>2</sup>, out of 52 pediatric pseudophakic eyes, 85% had 20/40 vision or better. Inatomi et al.<sup>16</sup> observed visual acuities of 20/40 or better in 79% of the operated eyes in their study of 15 unilateral cases. We observed 2 lines or more of visual acuity improvement in 78.2% of our patients, while 91% of the patients had visual acuities of 20/40 or better at the last follow-up, in concordance with the literature.

Myopic shifts following pediatric cataract surgery and IOL implantation have been reported in the literature to varying degrees.<sup>8,9,10,11,13,17</sup> In our study, we found myopic shifts in all of the age groups; however, the differences in the mean refractive change and mean refractive change per year, especially in the 2-5 years old age group, were found to be much greater, which was statistically significant. Plager et al.<sup>17</sup> reported refractive changes in 38 eyes that underwent primary IOL implantation and were followed for an average of 6 years. They stated that the rate of myopic shift decreased with age, and the variability among individuals decreased with age. Crouch et al.<sup>2</sup> observed a myopic shift that continued even until early adolescence following cataract surgery in their long-term study, with an average follow-up of 5.45 years. Although in previous reports the myopic shift in pseudophakic eyes has been attributed to excessive axial elongation by amblyopia and visual deprivation,<sup>18,19</sup> Enyedi et al.<sup>9</sup> reported that they did not believe that the trend of myopia in pseudophakia was the result of excessive elongation, but rather of normal eye growth with a fixed IOL power. They suggested that the myopic shift that they and other authors have observed is consistent with this growth pattern.<sup>9</sup> Dahan and Drusedau<sup>10</sup> also reported that pseudophakic eyes showed the most axial elongation during the first 2 years, and continued to grow more slowly up to the age of 8 years old, as in normal phakic eyes.

In 15 unilateral cases, long-term (4 to 15 years) changes in refraction, axial length, and refractive power of the cornea were evaluated and compared with nonoperated eyes, and no significant differences in the axial length or refractive power of the cornea between the operated and nonoperated eyes were detected, although there was significant myopic change in the operated eyes.<sup>16</sup> Enyedi and other authors (like Crouch) explained that this was because the IOL power was stable in the operated eye, while the normal phakic lens retained accommodation and compensated for developmental elongation.<sup>2,9</sup> In developing phakic eyes, it was reported that the progressive flattening of the crystalline lens decreased the refractive consequences of axial elongation.<sup>20</sup> McClathey et al.<sup>21</sup> inferred that the myopic shift of an operated eye was an optical phenomenon; as the eye grows, the IOL moves farther and farther from the retina. Analogous to the effects of the vertex distance with high-power lenses, the anterior movement of the IOL as the child grows induces a myopic shift by itself.<sup>21</sup> When we evaluated our unilateral cases and compared the operated eyes with the fellow eyes, we found a higher myopic shift in the operated eyes than the nonoperated fellow eyes, in concordance with these studies, but the difference was not statistically significant. However, since we did not measure axial length in the follow-up visits, we could not

discuss how axial elongation influenced the refractive state in the pseudophakic eyes during the children's development. This is a major limitation of our research.

Postoperative complications were another focus of our study. We determined that the most common ocular complication was visual axis opacity, including PCO, secondary membrane or lens reepithelialization, and capsular phimosis, as previously reported.<sup>1,14</sup> The prevalence of PCO has been reported to range between 14% and 72% in different studies with different age groups, surgical techniques, and IOL types.<sup>1,2,22</sup> We observed PCO in 22.8% of our cases, secondary membrane or lens reepithelialization in 14.9%, and capsular phimosis in 10.9%. However, all of these complications were successfully treated using appropriate interventions. The preventive measures for visual axis opacification following pediatric cataract surgery include a primary posterior capsulectomy with or without anterior vitrectomy.<sup>23</sup> In our clinic, we routinely perform a posterior capsulotomy with an anterior vitrectomy post-IOL implantation in children under 5 years old. In patients older than this, we leave the posterior capsule intact because, in most of those cases, it is easier to treat PCO with Nd:YAG laser. In our study, all of the eyes in patients older than 5 years with significant PCO were successfully treated with Nd:YAG laser.

Glaucoma is one of the most important and common complications of congenital cataract surgery. It is reported that the incidence of glaucoma in cases of aphakia ranges from 0.9% to 32%, which is less common than in pseudophakic patients.<sup>24,25</sup> In a recent study among pediatric patients, glaucoma incidence was reported as 33.3% in aphakia and 34.8% in patients with secondary IOL implantation, whereas no glaucoma was detected in patients with primary IOL implantation.<sup>26</sup> Our glaucoma incidence was 1.98%, in concordance with the literature.

## Conclusion

In conclusion, this study demonstrated that good visual outcomes can be achieved after pediatric cataract surgery with IOL implantation, even in patients with monocular sensorial strabismus and nystagmus. Occlusion therapy can play a great role in the improvement of visual acuity. Refractive changes after pediatric cataract surgery are inevitable, and predicting a future myopic shift remains difficult. Physicians must be aware of the variability of refractive changes, and must adjust for this with appropriate spectacles. Surgeons should also be aware of the possible postoperative complications after pediatric cataract surgery, and must pay close attention. Careful long-term follow-up and informing parents of any possible complications are essential for the care of these patients.

## Ethics

**Ethics Committee Approval:** Ege University, Clinical Research Ethics Committee (approval no: 17-11.1/76).

**Informed Consent:** The research protocol adhered to the Declaration of Helsinki for research involving human subjects. All of the parents or guardians of the children studied provided written consent to the screening and follow up assessments.

**Peer-review:** Externally peer-reviewed.

#### Authorship Contributions

Surgical and Medical Practices: Elif Demirkılınç Biler, Önder Üretmen, Süheyla Köse, Concept: Elif Demirkılınç Biler, Design: Elif Demirkılınç Biler, Önder Üretmen, Data Collection or Processing: Şeyda Yıldırım, Elif Demirkılınç Biler, Analysis or Interpretation: Elif Demirkılınç Biler, Önder Üretmen, Süheyla Köse, Literature Search: Şeyda Yıldırım, Elif Demirkılınç Biler, Writing: Elif Demirkılınç Biler, Öner Üretmen, Şeyda Yıldırım.

**Conflict of Interest:** No conflict of interest was declared by the authors.

**Financial Disclosure:** The authors declared that this study received no financial support.

#### References

- Kleinman G, Zaugg B, Apple DJ, Bleik J. Pediatric cataract surgery with hydrophilic acrylic intraocular lens. *J AAPOS*. 2013;17:367-370.
- Crouch ER, Crouch ER Jr, Pressman SH. Prospective analysis of pediatric pseudophakia: myopic shift and postoperative outcomes. *J AAPOS*. 2002;6:277-282.
- Plager DA, Yang S, Neely D, Sprunger D, Sondhi N. Complications in the first year following cataract surgery with and without IOL in infants and older children. *J AAPOS*. 2002;6:9-14.
- Brady KM, Atkinson CS, Kilty LA, Hiles DA. Cataract surgery and intraocular lens implantation in children. *Am J Ophthalmol*. 1995;120:1-9.
- Rosenbaum AL, Masket S. Intraocular lens implantation in children. *Am J Ophthalmol*. 1995;120:105-107.
- Wilson ME Jr, Bartholomew LR, Trivedi RH. Pediatric cataract surgery and intraocular lens implantation: Practice styles and preferences of the 2001 ASCRS and AAPOS memberships. *J Cataract Refract Surg*. 2003;29:1811-1820.
- Infant Aphakia Treatment Study Group, Lambert SR, Buckley EG, Drews-Botsch C, DuBois L, Hartmann E, Lynn MJ, Plager DA, Wilson ME. The infant aphakia treatment study: design and clinical measures at enrollment. *Arch Ophthalmol*. 2010;128:21-27.
- Kora Y, Shimizu K, Inatomi M, Fukado Y, Ozawa T. Eye growth after cataract extraction and intraocular lens implantation in children. *Ophthalmic Surg*. 1993;24:467-475.
- Enyedi LB, Peterseim MW, Freedman SF, Buckley EG. Refractive changes after pediatric intraocular lens implantation. *Am J Ophthalmol*. 1998;126:772-781.
- Dahan E, Drusedau MU. Choice of lens and dioptric power in pediatric pseudophakia. *J Cataract Refract Surg*. 1997;23(Suppl 1):618-623.
- Ben Ezra D. Cataract surgery and intraocular lens implantation in children. *Am J Ophthalmol*. 1996;121:224-226.
- Gimbel HV, Ferensowicz M, Raanan M, DeLuca M. Implantation in children. *J Pediatr Ophthalmol Strabismus*. 1993;30:69-79.
- Hutchinson AK, Drews-Botsch C, Lambert SR. Myopic shift after intraocular lens implantation during childhood. *Ophthalmology*. 1997;104:1752-1757.
- Medsing A, Nischal KK. Pediatric cataract: challenges and future directions. *Clin Ophthalmol*. 2015;9:77-90.
- Vanderveen DK, Trivedi RH, Nizam A, Lynn MJ, Lambert SR; Infant Aphakia Treatment Study Group. Predictability of intraocular lens power calculation formulae in infantile eyes with unilateral congenital cataract: results from the Infant Aphakia Treatment Study. *Am J Ophthalmol*. 2013;156:1252-1260.
- Inatomi M, Kora Y, Kinohira Y, Yaguchi S. Long-term follow-up of eye growth in pediatric patients after unilateral cataract surgery with intraocular lens implantation. *J AAPOS*. 2004;8:50-55.
- Plager DA, Kipfer H, Sprunger DT, Sondhi N, Neely DE. Refractive change in pediatric pseudophakia: 6-year follow-up. *J Cataract Refract Surg*. 2002;28:810-815.
- Wiesel TN, Raviola E. Increase in axial length of the macaque monkey eye after corneal opacification. *Invest Ophthalmol Vis Sci*. 1979;18:1232-1236.
- Tigges M, Tigges J, Fernandes A, Eggers HM, Gammon JA. Postnatal axial eye elongation in normal and visually deprived rhesus monkey. *Invest Ophthalmol Vis Sci*. 1990;31:1035-1046.
- Gordon RA, Donzis PB. Refractive development of the human eye. *Arch Ophthalmol*. 1985;103:785-789.
- McClathrey SK, Dahan E, Maselli E, Gimbel HV, Wilson ME, Lambert SR, Buckley EG, Freedman SF, Plager DA, Parks MM. A comparison of the rate of refractive growth in pediatric aphakic and pseudophakic eyes. *Ophthalmology*. 2000;107:118-122.
- Batur M, Gul A, Seven E, Can E, Yaşar T. Posterior Capsular Opacification in Preschool- and School-Age Patients after Pediatric Cataract Surgery without Posterior Capsulotomy. *Turk J Ophthalmol*. 2016;46:205-208.
- Jafarinasab MR, Rabbanikhah Z, Karimian F, Javadi MA. Lensectomy and PCIOL Implantation with versus without Posterior Capsulotomy and Anterior Vitrectomy for Pediatric Cataracts. *J Ophthalmic Vis Res*. 2008;3:37-41.
- Rabiah PK. Frequency and predictors of glaucoma after pediatric cataract surgery. *Am J Ophthalmol*. 2004;137:30-37.
- Mills MD, Robb RM. Glaucoma following childhood cataract surgery. *J Pediatr Ophthalmol Strabismus*. 1994;31:355-360.
- Solmaz NU, Onder F, Koca GE. Development of Secondary Glaucoma After Congenital Cataract Surgery and the Underlying Risk Factors. *Turk J Ophthalmol*. 2011;41:358-363.