

McCune-Albright Syndrome Mimicking Malignancy: an Endocrine Disease From Oncologist's Perspective

D. Bahar Genç¹, M. Alp Özkan¹, Atilla Büyükgebiz²

¹Anadolu Medical Center, Department of Pediatric Oncology, Kocaeli, Turkey

²Istanbul Bilim University, Department of Pediatric Endocrinology, Istanbul, Turkey

Introduction

Fibrous dysplasia (FD) is a common benign disorder of the bone in which fibro-osseous tissue replaces the bony spongiosa. It comprises around 7-10% of all benign bone tumors. 70-80% of FD cases are monostotic and 20-30% are polyostotic (1). McCune-Albright syndrome (MAS) is defined by the triad of FD, café au lait spots, and precocious puberty or at least one of the typical hyperfunctioning endocrinopathies in almost any possible combination (2). Bone lesions observed in MAS and FD can mimic malignant processes (3). Besides, coexisting neoplasia is a rare but probable occurrence and malignant transformation develops in 0.5-4% of the cases of FD/MAS (4). Computerized tomography (CT) and conventional radiographic findings demonstrate the characteristics of FD. However, magnetic resonance imaging (MRI) and FDG (fludeoxyglucose)-PET-CT imaging appearances of FD often resemble those of tumors. This potential diagnostic pitfall could lead to unnecessary medical interventions (5,6,7).

We report the case of a patient who had multifocal bone lesions and ataxia and was referred to our clinic with a presumptive diagnosis of malignancy. The patient was subsequently diagnosed as MAS and postinfectious cerebellitis.

Case Report

A 9-year-old girl was admitted to the pediatric emergency department because of a 2-day-history of unsteady gait,

ABSTRACT

Fibrous dysplasia (FD) is categorized as either monostotic or polyostotic and may occur as a component of McCune-Albright syndrome (MAS). Imaging findings can mimic neoplastic diseases. We present a case of MAS initially suspected to have neoplastic disease. A 9-year-old girl was admitted to pediatric emergency with ataxia. Upon hospitalization, an extradural mass was seen on cranial magnetic resonance imaging (MRI) and the bone survey showed lytic lesions in the long bones. The patient was referred to the pediatric oncology department with a presumptive diagnosis of Langerhans cell histiocytosis or metastatic tumor. Further investigations demonstrated that the patient had MAS and coexisting postinfectious cerebellitis. The findings in this patient demonstrate that the radiographic findings and the clinical presentation of FD and MAS may be similar to those of malignant diseases.

Key words: Fibrous dysplasia, malignancy, McCune-Albright syndrome

Conflict of interest: None declared

Received: 10.05.2012

Accepted: 20.06.2012

Address for Correspondence

D. Bahar Genç MD, Anadolu Medical Center, Pediatric Oncology, Kocaeli, Turkey
Phone: +90 262 654 05 90 GSM: +90 532 420 68 50 E-mail: baharbeker@yahoo.com
©Journal of Clinical Research in Pediatric Endocrinology, Published by Galenos Publishing.

vomiting, and dizziness. She was the third child of four pregnancies to a non-consanguineous couple. Her prenatal/natal history was unremarkable and her two siblings were healthy. One sibling had died in utero at the 8th month of pregnancy without an identified pathology. The patient's history did not reveal any recent immunization, upper respiratory tract infection, diarrhea or drug use. On inspection, the patient appeared to be in a state of exhaustion. Her blood pressure was 110/70 mm Hg, respiratory rate 24/minute and pulse rate 80/minute. Her height was 135 cm (50-75th perc., SDS: 0.9) and weight was 27 kg (25-50th perc.). Her body mass index (BMI) was 14.8. Physical examination findings were within normal limits except for ataxia. There were two irregularly bordered café au lait spots - one on the right cheek and the other in the presacral area. Breast development and pubic hair growth both corresponded to Tanner stage 4.

Initial laboratory findings were within normal ranges. A presumptive diagnosis of acute postinfectious cerebellitis was made. Parenteral hydration and acyclovir therapy were initiated. Otolaryngology consultation was sought. An inner ear problem as cause of ataxia was considered, but could not be proven by audiological examination. Cranial MR was done to delineate central nervous pathologies and revealed that there were fusiform expansions reaching 1.5 cm in thickness in almost all skull bones with a special predominance in the occipital and right parietal bones. Moderate diffuse contrast enhancement was also noted in these bones. Brain parenchyma was normal in terms of white and grey matter. The radiological differential diagnosis included Langerhans cell histiocytosis, primary bone lymphoma and neuroblastoma metastasis. CT scans supported the MRI findings except for a ground glass appearance indicative of FD (Figure 1).

The bone survey findings were as follows: loss of the distinction between cortex and medulla at the cranium, fingers and toes, as well as the humeri, radii, and ulnae, in addition to disrupted trabecular structure and presence of radiolucent areas. ^{99m}Tc MDP scintigraphy demonstrated extensive multiple osteoblastic uptake in accordance with either histiocytosis or FD.

The lytic and expansive bone lesions raised the suspicion of malignancy, and the patient was referred to the department

of pediatric oncology. Re-evaluation of the patient's history revealed that the breast development and pubic hair growth had started 2⁶/₁₂ years before the current situation. Precocious puberty, café au lait spots, and polyostotic FD in radiological differential diagnosis pointed to MAS. However, due to a suspicion of malignancy and presence of coexisting ataxia, a bone marrow biopsy was performed to exclude malignant infiltration. The biopsy represented both cortical and medullary areas. There were no signs of neoplasia, but the trabeculae were thin and mimicked Chinese letters, lacking osteoblastic rimming and were surrounded by a moderately cellular fibroblastic proliferation. The findings were consistent with FD. The patient was therefore referred to the department of pediatric endocrinology.

The patient's bone age was 11 years. Thyrotropin (TSH) was found to be slightly elevated (5.07 mU/mL). Serum alkaline phosphatase level was 738 U/L, Ca 10 mg/dL, and phosphorus 5 mg/dL. Her DEXA results revealed a Z-score (lumbar spine) of -1.9. The patient was diagnosed as a case of MAS. Her symptoms disappeared after 10 days of acyclovir treatment and supportive measures. She was discharged to be followed up jointly by the orthopedics and pediatric endocrinology departments. The patient had menarche at age of 9⁸/₁₂ years.

Discussion

FD is a developmental anomaly of the bone formation in which the normal bone and marrow are replaced by fibrous tissue and small, woven spicules of bone. FD may exist in a monostotic or polyostotic form. MAS is characterized by a combination of FD, cutaneous pigmentation, and endocrine abnormalities (2). The mutations in the regulatory Gs α protein - G protein α subunit - (encoded by the *GNAS* gene) are the underlying molecular etiology of MAS. The disease is not inherited as MAS results from postzygotic somatic mutation (8). The earlier the mutation occurs in embryogenesis, the more widespread are the tissues involved. Mutations late in embryogenesis are more focused and account for mild cases, with only one or two of the three manifestations of the syndrome which makes the diagnosis more difficult (9).

The diagnosis of MAS is usually established on clinical grounds. The medical history including extraskelatal manifestations should be taken into consideration. The initial evaluation of our patient failed to reveal her precocious puberty and therefore MAS was not among the differential diagnoses considered for the multifocal skeletal involvement. The diagnosis became evident when the concomitant presence of polyostotic FD, café au lait spots, and precocious puberty was evaluated. Unfortunately, *GNAS* mutation testing was not available in our facility.

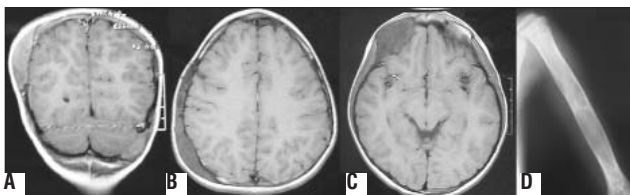


Figure 1. A: Coronal magnetic resonance imaging (MRI) showing extradural mass lesion at parietal area, B: Axial MRI showing fusiform expansion of skull bones extending through occipital area, C: MRI demonstrating frontal mass, D: Plain film of humerus revealing lytic lesions with ground glass appearance

The detection of a bone mass with/without limp or fracture poses a diagnostic dilemma for the general pediatrician or orthopedic surgeon in deciding whether the mass is cancerous or indicates FD. A radiograph is usually the first imaging modality to be performed. The plain film reveals a lytic, ground glass lesion in FD. In case of doubt about the diagnosis, the CT is helpful in demonstrating the medullary-based, fibro-osseous nature of FD (1). After the diagnosis of FD, bone scintigraphy or a skeletal survey should be done to determine the extent of the disease. However, that is where the second question comes in: Whether the patient has isolated FD or MAS with atypical or partial form. The classical triad of MAS includes precocious puberty, café au lait spots, and FD. This classical definition, however, does not hold for patients with partial and atypical forms of the syndrome (8, 10). A single endocrinopathy other than precocious puberty, such as isolated Cushing's syndrome in the neonatal period, might be the first manifestation of MAS (11,12). Fortunately, endocrine manifestations serve to increase the awareness of the physician and lead to a more detailed diagnostic assessment. In the absence of other signs of the syndrome, MAS diagnosis may be delayed until the development of classical findings. Hannon et al (13) reported that the pediatric FD cases were not routinely being evaluated for MAS. In this study, 5 of the 9 children with FD were found to have café au lait spots and 3 to have thyroid dysfunction. *GNAS* mutations were positive in 5 of the 9 cases. The authors concluded that a diagnosis of MAS

might be overlooked in a substantial proportion of children with FD of the bone. In a study from France, the authors searched for the activating *GNAS* mutations in 113 patients presenting with different signs of MAS. Three of 7 patients with isolated FD were positive for *GNAS* mutations (8). In a meta-analysis done by Lee et al (14), 9 studies searching *GNAS* mutations in 203 cases of sporadic FD were analyzed. The overall positivity rate for *GNAS* mutation was 71.9% (146/203). These studies draw attention to the likelihood of MAS in cases with isolated FD at initial presentation.

After diagnosis, MAS patients are referred to pediatric endocrinology clinics. However, the clinical dilemma may still persist in MAS cases presenting with mass lesions. *GNAS* mutations responsible for MAS lead to adenylyl cyclase-mediated increase in cAMP which initiates uncontrolled cell proliferation (15). Thus, FD possesses the potential for malignant change. Although very rare, its frequency was estimated to be 0.5% for monostotic FD and 4% for MAS (4). Several reports have documented the presence of thyroid, breast, pituitary and adrenocortical tumors in patients with MAS (16). In addition, activating mutations of *GNAS* have been identified in adrenal hyperplasia, ovarian cysts, thyroid carcinomas, adrenocortical, pituitary, renal and Leydig cell tumors (17). Furthermore, coexisting FD and malignancy in independent sites can cause potential diagnostic confusion in terms of metastatic disease (3,18,19).

Table 1. Previously reported MAS cases mistaken for neoplastic diseases

Report	Year	Age (years)	Presentation diagnosis	Differential	Intervention	Pathology diagnosis	Definitive
Current case	2012	9	Cerebellitis	LCH, Metastasis	Bone marrow biopsy	Fibrous dysplasia	MAS
Gucev et al (5)	2010	3	Ovarian mass	Ovarian tumor	Salpingo-oophorectomy	Benign ovarian cyst	MAS
Khanna et al (7)	2010	6	Testicular enlargement	Testicular cancer	Biopsy	Sertoli cell hyperplasia	MAS
Nabhan et al (6)	2007	3.5	Ovarian mass	Ovarian tumor	Salpingo-oophorectomy	Benign ovarian cyst	MAS
Nabhan et al (6)	2007	5.6	Ovarian mass	Ovarian tumor	Salpingo-oophorectomy	Benign ovarian cyst	MAS
Nabhan et al (6)	2007	4	Endocrinopathy/ Ovarian mass	Ovarian tumor	Salpingo-oophorectomy	Benign ovarian cyst	MAS
Nabhan et al (6)	2007	2	Ovarian mass	Ovarian tumor	Salpingo-oophorectomy	Benign ovarian cyst	MAS
Arrigo et al (20)	2006	4.6	Testicular enlargement	Testicular cancer	Biopsy	Sertoli cell hyperplasia	MAS
Kirk et al (12)	1999	0.13	Vomiting/ Abdominal distention	?	Laparotomy/Cystectomy	Benign ovarian cyst	MAS
Shawis et al (21)	1985	0.58	Ovarian mass	Ovarian tumor	Laparotomy/Cystectomy	Benign ovarian cyst	MAS

MAS: McCune-Albright syndrome

Some of the MAS cases may present with atypical initial features such as ovarian masses and testicular enlargement. In an otherwise healthy child who presents with a pelvic/testicular mass, the distinction between malignant and benign lesions can be challenging. Such patients may undergo unnecessary diagnostic or therapeutic interventions. Nabhan et al (6) reported that 4 out of 9 patients presenting with ovarian masses underwent unnecessary salpingo-oophorectomy and were all later diagnosed with MAS and benign ovarian cysts. In a study from Macedonia, a 3-year-old girl with a mass at the left ovary had surgery and the pathology of the salpingo-oophorectomy revealed a benign ovarian cyst (5). In Khanna et al.'s (7) and Arrigo et al.'s (20) studies, two boys presenting with unilateral macroorchidism underwent testicular biopsy in order to exclude malignancy. Ovarian cysts that can be encountered in MAS cases may also require invasive measures like laparotomy (12,21) (Table 1). In a European Collaborative Study, 113 patients who showed at least one of the signs of MAS were investigated with regard to activating Gs α mutations. Of the tissues analyzed, 13, 11 and 1 of the samples belonged to ovary, bone and testis, respectively. The ovarian tissue samples were reported to be obtained from ovariectomy. The reason for tissue sampling was not given. However, since only 27 patients out of 113 MAS cases in this series displayed the complete classical triad, it can be hypothesized that the invasive tissue sampling was done in an effort to identify the underlying pathology before the MAS was diagnosed (8). Since the radiographic findings and clinical presentation of FD and MAS may be similar to those of malignant diseases, and also considering the overlooked MAS cases with isolated FD followed in orthopedics clinics, it would be highly probable to increase the number of cases undergoing tissue sampling for suspected malignancy.

Conflict of Interest

The findings in this patient demonstrate that the radiographic findings and the clinical presentation of FD and MAS may be similar to those of malignant diseases.

References

1. Leet AI, Collins MT. Current approach to fibrous dysplasia of bone and McCune-Albright syndrome. *J Child Orthop* 2007;1:3-17.
2. Dumitrescu CE, Collins MT. McCune-Albright syndrome. *Orphanet J Rare Dis* 2008;3:12.
3. von Falck C, Rosenthal H, Laenger F, Lotz J, Knapp WH, Galanski M. Avid uptake of [18F]-FDG in fibrous dysplasia can mimic skeletal involvement in Hodgkin's disease. *Eur J Nucl Med Mol Imaging* 2008;35:223. (Epub 2007 Sep 14)
4. Hoshi M, Matsumoto S, Manabe J, Tanizawa T, Shigemitsu T, Izawa N, Takeuchi K, Kawaguchi N. Malignant change secondary to fibrous dysplasia. *Int J Clin Oncol* 2006;11:229-235.
5. Gucev Z, Tasic V, Jancevska A, Krstevska-Konstantinova M, Pop-Jordanova N. McCune-Albright syndrome (MAS): early and extensive bone fibrous dysplasia involvement and "mistaken identity" oophorectomy. *J Pediatr Endocrinol Metab* 2010;23:837-842.
6. Nabhan ZM, West KW, Eugster EA. Oophorectomy in McCune-Albright syndrome: a case of mistaken identity. *J Pediatr Surg* 2007;42:1578-1583.
7. Khanna G, Kantawala K, Shinawi M, Sarwate S, Dehner LP. McCune-Albright syndrome presenting with unilateral macroorchidism and bilateral testicular masses. *Pediatr Radiol* 2010;40:16-20. (Epub 2010 Jul 6)
8. Lumbroso S, Paris F, Sultan C. Activating Gs α mutations: Analysis of 113 patients with signs of McCune-Albright syndrome-A European Collaborative Study. *J Clin Endocrinol Metab* 2004;89:2107-2113.
9. Patel KB. McCune-Albright syndrome: a case report in a male. *Indian J Dermatol Venereol Leprol* 2010;76:723.
10. Bercaw-Pratt JL, Moorjani T, Santos XM, Karaviti L, Dietrich JE. Diagnosis and management of precocious puberty in atypical presentations of McCune-Albright syndrome: a case series review. *J Pediatr Adolesc Gynecol* 2012;25:9-13. (Epub 2011 Nov 3)
11. Paris F, Philibert P, Lumbroso S, Servant N, Kalfa N, Sultan C. Isolated Cushing's syndrome: an unusual presentation of McCune-Albright syndrome in the neonatal period. *Hormone Res* 2009;72:315-319. (Epub 2009 Oct 19)
12. Kirk JM, Brain C, Carson DJ, Hyde JC, Grant DB. Cushing's syndrome caused by nodular adrenal hyperplasia in children with McCune-Albright syndrome. *J Pediatr Adolesc Gynecol* 1999;134:789-792.
13. Hannon TS, Noonan K, Steinmetz R, Eugster EA, Levine MA, Pescovitz OH. Is McCune-Albright syndrome overlooked in subjects with fibrous dysplasia of bone? *J Pediatr* 2003;142:532-538.
14. Lee SE, Lee EH, Park H, Sung JY, Lee HW, Kang SY, Seo S, Kim BH, Lee H, Seo AN, Ahn G, Choi YL. The diagnostic utility of the GNAS mutation in patients with fibrous dysplasia: meta-analysis of 168 sporadic cases. *Hum Pathol* 2012;43:1234-1242. (Epub 2012 Jan 14)
15. Dorsam RT, Gutkind J. G-protein-coupled receptors and cancer. *Nat Rev Cancer* 2007;7:79-94.
16. Wilson CH, McIntyre R, Arends MJ, Adams DJ. The activating mutation R201C in GNAS promotes intestinal tumorigenesis in Apc(Min/+) mice through activation of Wnt and ERK1/2 MAPK pathways. *Oncogene* 2010;29:4567-4575.
17. Radhika V, Dhanasekaran N. Transforming G proteins. *Oncogene* 2001;20:1607-1614.
18. Kato K, Hayashi T, Tabuchi K, Okuzumi N, Kigasawa H, Abe Y, Toyoda Y, Aida N, Sekido K, Sato H, Tanaka M, Tanaka Y. Concurrent Ewing sarcoma family of tumors and fibrous dysplasia: possible diagnostic pitfall. *J Pediatr Hematol Oncol* 2007;29:15-18.
19. Basu S, Baghel N, Puri A, Shet T, Merchant NH. 18 F-FDG avid lesion due to coexistent fibrous dysplasia in a child of embryonal rhabdomyosarcoma: source of false positive FDG-PET. *J Cancer Res Ther* 2010;6:92-94.
20. Arrigo T, Pirazzoli P, De Sanctis L, Leone O, Wasniewska M, Messina MF, De Luca F. McCune-Albright syndrome in a boy may present with a monolateral macroorchidism as an early and isolated clinical manifestation. *Horm Res* 2006;65:114-119. (Epub 2006 Feb 2)
21. Shawis RN, El Gohary A, Cook RC. Ovarian cysts and tumours in infancy and childhood. *Ann R Coll Surg Engl* 1985;67:17-19.