



Elastic Stable Intramedullary Nailing for Pediatric Forearm Fractures: A Retrospective Analysis of Thirty Four Cases

Çocuk Ön Kol Kırıklarının Cerrahi Tedavisinde Elastik Stabil Kanal-İçi Çivileme: Otuz Dört Hastanın Retrospektif Analizi

© Sercan Çapkın, © Mahmut Aydın, © Fatih Günaydın, © Serkan Sürücü, © Doğan Atlıhan

University of Health Sciences, Haseki Training and Research Hospital, Department of Orthopedics and Traumatology, İstanbul, Turkey

Abstract

Aim: The purpose of this investigation was to present our institutional experience of 34 pediatric both bone forearm fractures treated with titanium elastic intramedullary nails.

Methods: Thirty-four patients, who were treated with titanium elastic nail for both bone forearm fractures diagnosis between 2011 and 2016, were included in the study. Clinical and radiological evaluation of the patients was retrospectively analyzed.

Results: Bone healing process was completed for all patients at a mean of 6.6 weeks. The implants were removed at a mean time of 9.7 months from the index operation. Complications, including skin infections at the entry side of the nail, were recorded in three (8.82%) patients. These three patients had type 1 open fracture according to the Gustilo-Anderson classification and were treated with first generation cephalosporins. In a subjective measure of outcome during follow-up, it was observed that 33 patients (97.06%) were very satisfied and one (2.94%) was satisfied; no patient reported being not satisfied.

Conclusion: Since titanium elastic nailing is a safe and effective method of treatment with advantages of easy implantation and removal as well as excellent cosmetic and functional results, elastic stable intramedullary nailing is the first treatment option that should be considered in pediatric both bone forearm fractures.

Keywords: Titanium elastic nail, forearm fracture, pediatric

Öz

Amaç: Çocuk önkol çift kırıklarının cerrahi tedavisinde elastik intramedüller çivileme uyguladığımız 34 hastanın sonuçlarını değerlendirmektir.

Yöntemler: Çalışmaya 2011-2016 yılları arasında önkol çift kemik kırığı tanısı ile titanyum elastik çivi uyguladığımız 34 hasta dahil edildi. Hastaların klinik ve radyolojik takipleri geriye dönük analiz edildi.

Bulgular: Hastalarda ortalama kaynama süresi 6,6 haftaydı. İmplantların çıkarılma zamanı ortalama 9,7 aydı. Hastaların üçünde (%8,82) çivi giriş yerinde deri enfeksiyonu tespit edildi. Bu üç hasta Gustillo Anderson sınıflamasına göre tip 1 açık kırık olan hastaydı ve birinci kuşak sefalosporin ile tedavi edildi. Bir hasta dışında tüm hastalarda (%97,06) klinik ve radyolojik olarak Price kriterlerine göre mükemmel sonuç elde edildi.

Sonuç: Klinik ve radyolojik sonuçlarının iyi olması, uygulama tekniğinin ve implant çıkartılmasının kolay olması, daha az yumuşak doku hasarına yol açması nedeniyle çocuk önkol çift kırıklarının cerrahi tedavisinde elastik stabil intramedüller çivileme uygulamasının iyi bir seçenek olduğunu düşünüyoruz.

Anahtar Sözcükler: Titanyum elastik çivi, önkol kırığı, pediatrik

Introduction

Pediatric forearm fractures are common injuries among children, comprising 3% to 6% of all pediatric fractures (1-3). Treatment with closed reduction and cast immobilization is still the gold standard for most of the pediatric

forearm fractures (4). However, unstable or open injuries often require surgical treatment to maintain adequate alignment (5). Intramedullary fixation with titanium elastic nails (TENs) has emerged as the most common method for fixation of forearm fractures in skeletally immature

Address for Correspondence/Yazışma Adresi: Sercan Çapkın
University of Health Sciences, Haseki Training and Research Hospital, Department of Orthopedics and Traumatology, İstanbul, Turkey

Phone: +90 506 842 75 96 E-mail: sercancapkın@gmail.com ORCID ID: orcid.org/0000-0001-6957-5927

Received/Geliş Tarihi: 27 May 2017 **Accepted/Kabul Tarihi:** 18 October 2017

©Copyright 2018 by The Medical Bulletin of
University of Health Sciences Haseki Training and
Research Hospital
The Medical Bulletin of Haseki published by
Galenos Yayınevi.

©Telif Hakkı 2018 Sağlık Bilimleri Üniversitesi Haseki Eğitim ve Araştırma Hastanesi
Haseki Tıp Bülteni, Galenos Yayınevi tarafından basılmıştır.

patients (6). The biomechanical principal of TENsis based on the symmetrical bracing action of two elastic nails inserted into the metaphysis, each of which bears against the inner bone at three points (7,8). This produces the following four properties that are essential for achieving optimal results; flexural, axial, translational and rotational stability (7). Elastic stable intramedullary nailing (ESIN) has the benefits of early immediate stability to the involved bone segment, which permits early mobilization and return to the normal activities of the patients, with very low complication rate (9,10). The purpose of this study was to demonstrate our experience of ESIN treatment of 34 pediatric both bone forearm fractures and discuss in the context of the literature.

Methods

We performed a retrospective analysis of records of children with both bone forearm fractures and open epiphyseal plates, treated with ESIN between January 2011 and December 2015 in the Department of Orthopedics and Traumatology at Haseki Training and Research Hospital, İstanbul, Turkey. Approval for this retrospective study was granted by our institutional review board, and all patients provided written informed consent before enrolment. Thirty-four patients, who were treated with TENs for the pediatric both bone forearm fractures, were included in the study. Patients without appropriate reduction were operated. Inappropriate reduction: for children younger than eight years; full displacement fracture or angulation of 15 degrees, for children older than eight years; 10 degrees of angulation or full-displacement on antero-posterior or lateral plane radiographs.

All the patients were operated under general anesthesia. The patients were placed in the supine position with the upper limb on a radiolucent side table. The first bone to be fixed was the one that is easiest to reduce. Preferably closed reduction of radius was achieved under image intensifier and radial fracture was fixed with the nail advanced in a retrograde fashion through a drill hole just proximal to the distal radial epiphysis. Optimal care was taken not to injure the extensor tendons and superficial radial cutaneous nerve. The tip of the radial nail was bent to about 15 to 30 degrees for easy passage of the pin through the medullary cavity. Ulnar fracture was fixed with a nail which was inserted in an antegrade fashion through the olecranon. The diameter of the nails ranged between 2 and 3 mm, depending on the child's age and size of the bone. It was noted that the diameter of the nail had filled at least 50% of the inner diameter of the diaphysis and the nails did not pass the epiphysis. The curved ends were buried under the skin in all cases. The skin incisions were sutured.

Post operatively, a long arm splint was used in all cases for two weeks. Physiotherapy was started as early as possible. Intermittent extension and flexion of the elbow and wrist was allowed by the second day after operation. Supination and pronation was allowed only after three weeks.

Clinical results were evaluated according to the scale developed by Price. According Price, absence of complaints with strenuous physical activity or a loss of pronation-supination less than 10 degrees can be considered as excellent, good if mild complaints with strenuous activity and/or 11°-30° loss of forearm rotation; fair if subjective complaints during daily activities or 31°-90° loss of forearm rotation and all other results were considered poor (11).

Statistical Analysis

Descriptive statistics were completed including percent, mean, and range using Microsoft Excel, 2010.

Results

Thirty patients were male and four were female. The fractures were right sided in 14 patients and left sided in 20. Twenty-seven of the forearm fractures were closed and seven were type 1 open fracture according to the Gustilo-Anderson classification. Six fractures were located at distal 1/3, 24 at middle 1/3 and four at proximal 1/3. The average age of the patients was 10.8 years, and the mean follow-up period was 25.5 months. Demographic characteristics of the patients and the treatments are shown in Table 1. Radiologically, the presence of callus formation and the absence of pain and sensitivity due to clinically forearm movements were considered union. The mean time to

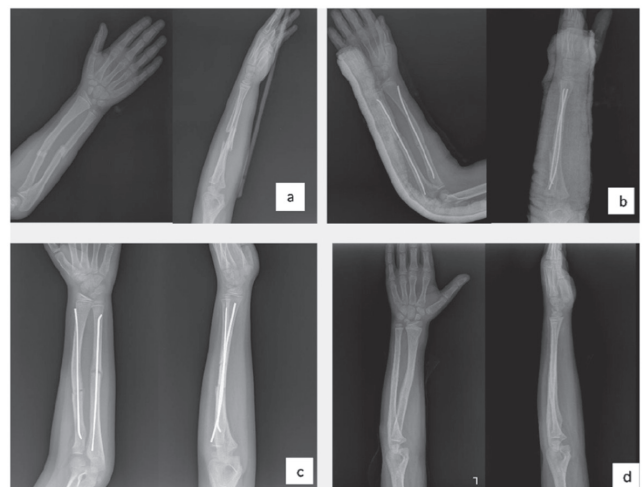


Figure 1. (a) Anterior posterior and lateral views of a eight years-old boy with a type 1 open diaphyseal both-bone forearm fracture (b) treated with closed reduction and elastic stable intramedullary nailing of the radius and ulna (c) postoperative 4th weeks, callus formation visible (d) one year later, the nails are removed

fracture union was 6.6 weeks. Complications including skin infections at the entry side of the nail were recorded in 3 (8.82%) patients. These three patients had type 1 open fracture according to the Gustilo-Anderson classification and treated with first generation cephalosporins. There were no cases of delayed union, non-union or mal-union.

In a subjective measure of outcome during follow-up, 33 patients (97.06%) were found to be very satisfied and one patient (2.94%) was observed to be satisfied; no patient reported being not satisfied. The implants were removed under general anesthesia as a day surgery procedure without difficulty at a mean time of 9.7 months after the

Table 1. Summary of the patients with intramedullary fixation of forearm fractures

P	Age (years)	Gender	Side	Reduction	Complications	Implant removal (months)	Time to union (months)	Follow-up (months)
1	13	m	L	Closed	no	8	8	28
2	14	m	R	Open	no	6	8	24
3	14	m	L	Closed	no	10	6	24
4	13	m	R	Closed	no	7	7	22
5	11	m	R	Closed	no	8	6	24
6	10	m	L	Closed	no	9	6	24
7	13	m	R	Closed	no	12	7	36
8	11	m	L	Open	inf	8	6	24
9	12	m	R	Closed	no	11	6	36
10	11	m	L	Closed	no	13	6	36
11	11	m	L	Closed	no	14	7	38
12	14	m	R	Closed	no	10	9	36
13	9	m	L	Closed	inf	10	6	40
14	8	m	L	Open	no	12	8	26
15	12	m	R	Closed	no	11	7	24
16	11	m	L	Closed	no	10	6	22
17	14	m	L	Closed	no	12	6	24
18	10	m	R	Closed	no	13	6	26
19	11	m	L	Open	no	11	8	28
20	7	m	R	Closed	no	6	6	22
21	10	m	L	Closed	no	8	8	22
22	14	f	L	Closed	no	6	7	18
23	9	m	L	Open	inf	10	6	18
24	9	m	L	Closed	no	10	6	20
25	10	m	L	Closed	no	9	6	20
26	13	f	R	Open	no	10	8	22
27	9	m	L	Closed	no	10	7	28
28	8	m	L	Closed	no	9	6	28
29	10	m	R	Closed	no	12	6	22
30	10	m	L	Closed	no	12	7	22
31	14	m	R	Closed	no	16	6	24
32	12	m	R	Open	no	9	7	24
33	7	f	L	Closed	no	6	6	20
34	5	f	R	Closed	no	5	5	18

P: Patient, m: Male, f: Female, R: Right, L: Left, inf: Skin infections at the entry side of the nail

index operation. During follow-up, all patients completed bone healing and regained a full range of motion after rehabilitation (Figure 1).

According to the Price criteria, the result was excellent in 97.06% of patients. Wrist, forearm and elbow movements were full in all patients except one. The patient had 10 degrees of wrist dorsiflexion and regained full wrist motion after implant removal. Forearm rotation loss detected in none of the patients.

Discussion

Most of forearm fractures can be treated successfully by closed methods and cast application with satisfactory results with displaced forearm, a recognized failure rate has been reported to be 7-32% and some of the indications for operative intervention are open fractures, irreducible fractures, unstable fractures, pathological fractures, fractures with neurovascular compromise, malunions, and refractures (6,12). Flexible intramedullary nailing is a preferred fixation method for pediatric forearm fractures. Most series showed good to excellent results using this method (13-15). The rate of complications associated with TENs has been reported to be 15-67% in the literature (16,17). Flynn and Waters (18) reported a complication rate of 14.6%, however, Shah et al. (19) reported that the complication rate was 0%. In their study, Antabak et al. (20) found a complication rate of 25% among 88 patients. Kruppa et al. (17) reported a complication rate of 8.9%, 6.9% of which underwent reoperation. In our study, complications including infections at the entry side of the nail were recorded in three (8.82%) patients. Complications such as refracture, rupture of the extensor pollicis tendon, epiphyseal damage, angular or rotational deformity, synostosis and damage to the sensory branch of the ulnar nerve were not seen in any patient. In a subjective measure of outcome during follow-up, 97.06% of patients were very satisfied and 2.94% satisfied; no patient reported being not satisfied.

Conclusion

Since TEN is a safe and effective method of treatment with the advantages of excellent cosmetic and functional results, it is the first treatment option that should be considered in pediatric both bone forearm fractures. Its retrospective and non-comparative nature is a limitation of our study. Similar studies with a nonoperative control group or comparative studies with other operative techniques and longer duration of follow-up are needed for drawing a definite conclusion.

Authorship Contributions

Surgical and Medical Practices: S.Ç., S.S., F.G., D.A. Concept: S.Ç., D.A. Design: S.Ç. Data Collection or

Processing: S.Ç., M.A., S.S., F.G. Analysis or Interpretation: S.Ç. Literature Search: S.Ç. Writing: S.Ç.

Conflict of Interest: No conflict of interest was declared by the authors.

Financial Disclosure: The authors declared that this study received no financial support.

References

1. Cheng JC, Shen WY. Limb fracture pattern in different pediatric age groups: a study of 3350 children. *J Orthop Trauma* 1993;7:15-22.
2. Landin LA. Epidemiology of children's fractures. *J Pediatr Orthop B* 1997;6:79-83.
3. Worlock P, Stower M. Fracture patterns in Nottingham children. *J Pediatr Orthop* 1986;6:656-60.
4. Creasman C, Zaleske DJ, Ehrlich MG. Analyzing forearm fractures in children: the more subtle signs of impending problems. *Clin Orthop* 1984;188:40-53.
5. Franklin CC, Robinson J, Noonan K, Flynn JM. Evidence-based medicine: management of pediatric forearm fractures. *J Pediatr Orthop* 2012;32 (Suppl 2):S131-4.
6. Flynn JM, Jones KJ, Garner MR, Goebel J. 11 years experience in the operative management of pediatric forearm fractures. *J Pediatr Orthop* 2010;30:313-9.
7. Li Y, Stabile KJ, Shilt JS. Biomechanical analysis of titanium elastic nail fixation in a pediatric femur fracture model. *J Pediatr Orthop* 2008;28:874-8.
8. Mahar A, Sink E, Faro F, Oka R, Newton PO. Differences in biomechanical stability of femur fracture fixation when using titanium nails of increasing diameter. *J Child Orthop* 2007;1:211-5.
9. Pogorelec Z, Furlan D, Biocić M, Mestrović J, Jurić I, Todorčić D. Titanium intramedullary nailing for treatment of simple bone cysts of the long bones in children. *Scott Med J* 2010;55:35-8.
10. Wall EJ, Jain V, Vora V, Mehlman CT, Crawford AH. Complications of titanium and stainless steel elastic nail fixation of pediatric femoral fractures. *J Bone Jt Surg Am* 2008;90:1305-13.
11. Price CT, Scott DS, Kurzner ME, Flynn JC. Malunited forearm fractures in children. *J Pediatr Orthop* 1990;10:705-12.
12. Fernandez FF, Egenolf M, Carsten C, Holz F, Schneider S, Wentzensen A. Unstable diaphyseal fractures of both bones of the forearm in children plate fixation versus intramedullary nailing. *Injury* 2005;36:1210-6.
13. Salonen A, Salonen H, Pajulo O. A critical analysis of postoperative complications of antebrachium TEN-nailing in 35 children. *Scand J Surg* 2012;101:216-21.
14. Shoemaker S, Comstock C, Mubarak S, Wenger DR, Chambers HG. Intramedullary Kirschner wire fixation of open or unstable forearm fractures in children. *J Pediatr Orthop* 1999;19:329-37.
15. Lascombes P, Prevot J, Ligier JN, Metaizeau JP, Poncelet T. Elastic stable intramedullary nailing in forearm shaft fractures in children: 85 cases. *J Ped Orthop* 1990;10:167-71.

16. Garg NK, Bhallal MS, Malek IA, Webster RA, Bruce CE. Use of elastic stable intramedullary nailing for treating unstable forearm fracture in children. *J Trauma* 2008;65:109-15.
17. Kruppa C, Bunge P, Schildhauer TA, Dudda M. Low complication rate of elastic stable intramedullary nailing (ESIN) of pediatric forearm fractures: A retrospective study of 202 cases. *Medicine (Baltimore)* 2017;96:e6669.
18. Flynn JM, Waters PM. Single-bone fixation of both-bone forearm fractures. *J Pediatr Orthop* 1996;16:655-9.
19. Shah AS, Lesniak BP, Wolter TD, Caird MS, Farley FA, Vander Have KL. Stabilization of adolescent bothbone forearm fractures: a comparison of intramedullary nailing versus open reduction and internal fixation. *J Orthop Trauma* 2010;24:440-7.
20. Antabak A, Luetic T, Ivo S, et al. Treatment outcomes of both-bone diaphyseal paediatric forearm fractures. *Injury* 2013;44:11-5.