

Severe calcific constrictive pericardiectomy operation: ‘Hearts of stone’

Tuğra Gençpınar¹, Çağatay Bilen¹, Gökmen Akkaya¹, Hasan Hepağuşlar², Kıvanç Metin³,
Hudai Çatalyürek³, Öztekin Oto³

¹⁾ Dokuz Eylül University, Department of Cardiovascular Surgery, MD., Izmir, Turkey

²⁾ Dokuz Eylül University, Department of Anesthesiology and Reanimation, MD., Izmir, Turkey

³⁾ Dokuz Eylül University, Department of Cardiovascular Surgery, MD., Prof., Izmir, Turkey

Abstract

Background: Dense constrictive pericarditis, ‘‘Hearts of stone’’ is a rare condition characterized by limitation of myocardium due to a massive fibrosis and calcification of the pericardium. The aim of this study was to research the literature to discuss the surgical intervention and management of densely calcified constrictive pericarditis.

Methods: Over a seven-year period, 19 consecutive patients who underwent pericardiectomy operation for severe constrictive pericarditis reviewed to determine reasons, surgical techniques, mortality and morbidity rates, and improvement of functional capacity. We freed the anterior pericardium from phrenic nerve to phrenic nerve. In two cases, we used a rongeur to break down the dense calcification. The indications for pericardiectomy were tuberculous in 4 cases (21%), idiopathic-fibrous in 11(57.8%), rheumatic in 2(10.5%), uremic in 1(5.2%), and neoplastic in 1(5.2%).

Results: Inpatients mortality ratio was 5.2% in case of isolated severe calcified pericardiectomy. Ascites in 3 patients (15.7%), hepatomegaly in 4 (21%) and peripheral edema in 15 (78.9%) were found on their physical examination. In the 1st postoperative month follow up, dramatically improvement of preoperatively functional capacity were the number of cases in New York Heart Association class IV (worse general condition) moved from 14 to II; in class III from 4 to II; in class II from to I in one case. In our all series, idiopathic-fibrous was the most frequent cause of chronic severe constrictive pericarditis, but the second most common tuberculous pericarditis was increasing overall. Postoperative and neoplastic pericarditis were rare.

Conclusion: The preoperative clinical conditions and functional status at follow-up was improved in all cases. We recommended that the orthopedic surgical instrument, ‘rongeur’, is very useful to cut that totally calcified tissue.

Keywords: Constrictive pericarditis, pericardiectomy, heart failure, calcification

Gençpınar T., Bilen Ç., Akkaya G., Hepağuşlar H., Metin K., Çatalyürek H., Oto O. Severe calcific constrictive pericardiectomy operation, ‘Hearts of stone’. EJCM 2016; 04 (4): 77-82. Doi: 10.15511/ejcm.16.04077.

Introduction

Chronic calcific constrictive pericarditis is caused by massive fibrosis and calcification of the pericardium, processes that inhibit diastolic filling of the heart.^[1-3] It may be idiopathic or frequently caused by viral infections, radiotherapy, thoracic and/or heart surgery. The clinical features are non-specific. Therefore, limitation of myocardium due to a rigid pericardium result to chronic heart failure. Surgical pericardiectomy is an effective intervention for dense calcific constrictive pericarditis. After surgical removal of the pericardium, diastolic filling of the heart returns into normal. Patients are potentially curable by a pericardiectomy from phrenic nerve to phrenic nerve. Yetkin et al.^[2] recommend that the median sternotomy approach for chronic constrictive pericarditis and consider cardiopulmonary bypass safe to use in indicated cases.

Diagnosis can made by chest X-ray and computed tomography (CT), magnetic resonance imaging (MRI), echocardiogram (ECHO) and heart catheterization that can showed anterior chest wall calcification like calcified pericarditis. Goel et al.^[1] have demonstrated that standard chest CT-scan allows a nice anatomic delineation of the pericardium and its calcifications. Furthermore, computed tomography best defines the often asymmetric degree of pericardial thickening or calcification, which may be important in determining the optimal surgical approach for pericardial resection.

Methods

We reviewed the cases of 19 patients who underwent pericardiectomy operation via median sternotomy for severe constrictive pericarditis, "Hearts of stone" between January 2008 and July 2015, to determine causes, treatment options of surgical techniques, mortality and morbidity rates, and improvement of functional capacity. In all patients who has admitted to our clinic for the surgical therapy, cardiac evaluation confirmed constrictive pericarditis. All cases presented with dyspnea on exertion and easy fatigability.

In all cases, the operation was performed thorough median sternotomy. We freed the anterior pericardium from phrenic nerve to phrenic nerve. In two cases, the severe calcified pericardium around both ventricles

was so hard to contract because of dense calcified tissue which adhered to the myocardium. Different seizers failed to cut due to severe calcification and adhesion. Therefore, we employed a rongeur to peel off the calcified pericardium gently around the right and left ventricles which performed without the usage of extracorporeal circulation.

The primary outcomes were the risk factors including advanced age, sex, smoking status, hypertension, hyperlipidemia, carotid disease, diabetes mellitus, prior cardiac events, chronic obstructive pulmonary disease, peripheral vascular disease, neurological events, HbA1c levels, and serum creatinine levels. The secondary outcomes were of preoperative New York Heart Association (NYHA) heart failure functional class and left ventricular ejection fraction. Other outcome measures were perioperative death (in hospital) and intensive care unit vital follow up. In all calculations and statistical analyses, "Statistical Package for Social Sciences" (SPSS-Chicago, IL, USA) 16 and Software Excel (Microsoft-USA) programs were used. The statistical results are presented as mean values.

Results

During the 7-year period between January 2008 and July 2015, we performed pericardiectomy operation thorough median sternotomy on 19 cases with a diagnosis of constrictive pericarditis. The cases consisting of 9 female (47.3%), 10 male (52.2%) were found. 19 cases with an average age of 56.57 years (min: 35, max: 85) (11.23 SD) have been observed.

Ascites in 3 patients (15.7%), hepatomegaly in 4 (21%) and peripheral edema in 15 (78.9%) were found on their physical examination. The cases operated on within 2 months after the onset of symptoms. Laboratory results found hyponatremia, hypoproteinemia and hypoalbuminemia in all cases. The mid-term survival was satisfactory. There was no any neurological complication (postoperative major adverse cardiovascular and cerebral event (MACCE) during pericardiectomy operation. Comorbidities related to the patient group were the diabetes mellitus in 1 case (5.2%) (Insulin dependent-HbA1c median ratio 7.78) and the hypertension in 3 cases (15.1%). There was 1 case (5.2%) with atrial fibrillation. None of the cases had concomitant coro-

nary artery disease. Chronic Obstructive Pulmonary Disease was observed in 1 case (5.2%). Alcohol use was not found. Smoking was observed in 8 patients (42.1%). Preoperatively, four of the 19 patients (21%) had needed pericardiocentesis. These patients had taken diuretics and digitalis at optimal doses for heart failure.

Inpatients mortality ratio was 5.2% (1 case in tuberculous pericarditis, 85 years old) with multiple organ failure and low cardiac output. No patients had required a mechanical circulatory support or dialysis. Prolonged ventilatory use (≥ 24 hours), mediastinal re-operation for hemorrhage, sternal wound infection, or mediastinitis had not been put forth. The average intubation time was found to be 1.05 ± 5.1 hours. Postoperative periods were uneventful. Computed tomographies and chest X-

rays were normal (**Figure 1-2**) Normal cardiac functions were revealed by serial echocardiography that showed left ventricular ejection fractions were about 50% globally and left and right ventricular hypokinesia in all cases.

There founded none evidence of phrenic nerve injury. We had not used to placed temporary pacing wires or Intra-aortic balloon counter-pulsation (IABP). There was no need ventricular defibrillation. The patients maintained normal life activities and discharged in five days. In the 1st postoperative month follow up, dramatically improvement of functional capacity were the number of cases in NYHA class IV (worse general condition) moved from 14 (preoperatively) to II; in class III from 4 to II; in class II from to I in one case. The

Table 1. The demographic characteristics of the cases (n=19)

	56.57±11.23	
Mean Age (yr)	(min: 35, max: 85)	
Female	9 (47.3%)	
Mortality	5.2%	
	n	%
Current Smoker	8	42.1
Hypertension	3	15.1
Diabetes (HgA1c ≥ 7 mg/dl)	1	5.2
History of Myocard Infarction	-	-
Chronic Obstructive Pulmonary Disease	1	5.2
Peripheral Vascular Disease	1	5.2
Coronary Artery Disease	-	-
Atrial Fibrillation	1	5.2
Neurological complication (MACCE)	-	-
Ascites	3	15.7
Hepatomegaly	4	21
Peripheral edema	15	78.9

Figure 1. CT angiography image of dense constrictive pericarditis

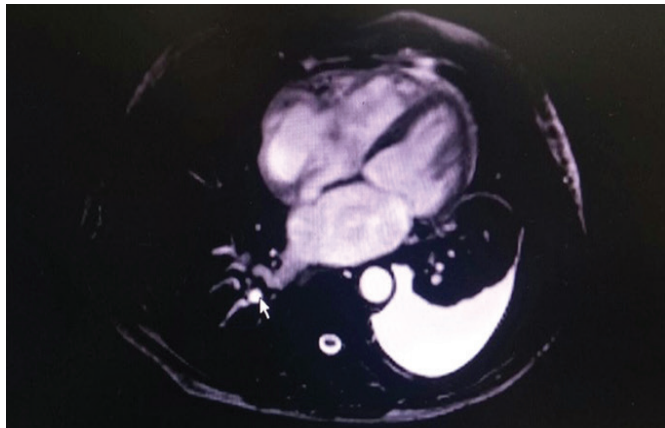
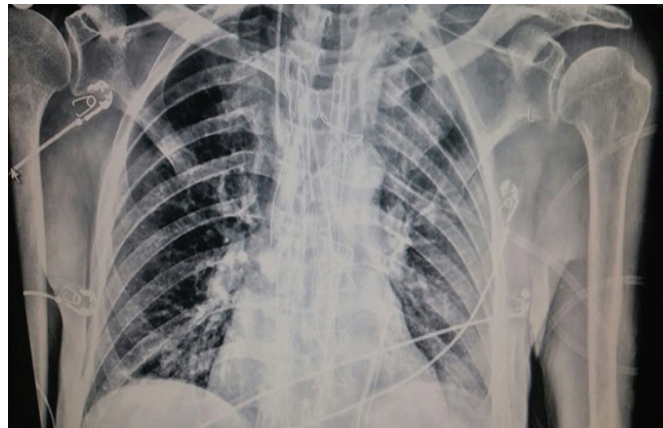


Figure 2. Post-operative X-ray image



chronic constrictive pericarditis were tuberculous in 4 cases (21%), idiopathic-fibrous in 11 (57.8%), rheumatic in 2 (10.5%), uremic in 1 (5.2%), and neoplastic in 1 (5.2%) (Table-2).

Standard anticoagulant therapy (acetyl - salicylic acid 100 mg/day) was given. Mean duration of intensive care unit (ICU) was 3.9/day, and the duration of hospital stay was 5.2 days. Blood drainage was about 3.31/liter. Both erythrocyte replacement (average 2.89/liter) and fresh frozen plasma were used for bleeding. There was no need for early repeat pericardiectomy or re-exploration.

Discussion

Dense chronic constrictive pericarditis was previously described in 1842 by Cheever.^[2] Severe calcific constrictive pericarditis give rise to increase both ventricular end-diastolic pressures and a decrease in out-

flow volume.^[1-5] Pericardiectomy is the only treatment option for calcified pericardium.^[3-7] Pericardiectomy is a safe surgical approach with available techniques.^[6-8] Cases typically present with symptoms of both sided heart failure which including dyspnoea, orthopnoea, easy fatigability, hepatomegaly and ascites. Most common causes are tuberculosis, viral infection, previous cardiac surgery, radiotherapy, idiopathic, sarcoidosis and rheumatic diseases.^[7-10] In approximately 50% of cases, chest X-ray and computed tomography are used to demonstrate dense calcification of the pericardium.^[2-4] The echocardiogram and heart catheterization are important for diagnosis that visible pericardial calcification on chest region.^[10-12]

During the 7-year period, anterior pericardium was resected from phrenic nerve to phrenic nerve. We freed the anterior pericardium first from the aorta and the left ventricular outflow tract as supported by literature.^[12-15] After that, the both ventricles and finally venae cavae was resected. None of patient required cardiopulmonary bypass. In two cases, the calcified pericardium around both ventricles was so hard to contract because of calcified tissue which adhered to the myocardium. Different seizers failed to cut; therefore we used a rongeur to break down the calcification (Figure 3). This orthopedic surgical instrument was very useful to cut that totally calcified tissue which is of about 8 mm thickness. Rongeur was applied to gouge out pericardium in small pieces. The tricky point is not to create sharp ends during step by step biting of pericardium in order to avoid penetration. We offer that a rongeur is very useful for peeling off the

Table 2. Comparison of pre-post operative NYHA class

NYHA Class	Preoperatively (%)	Postoperatively (1st month) (%)
I	-	1 (5.2)
II	1 (5.2)	18 (94.7)
III	4 (21)	-
IV	14 (73.6)	-
NYHA: New York Heart Association Class		

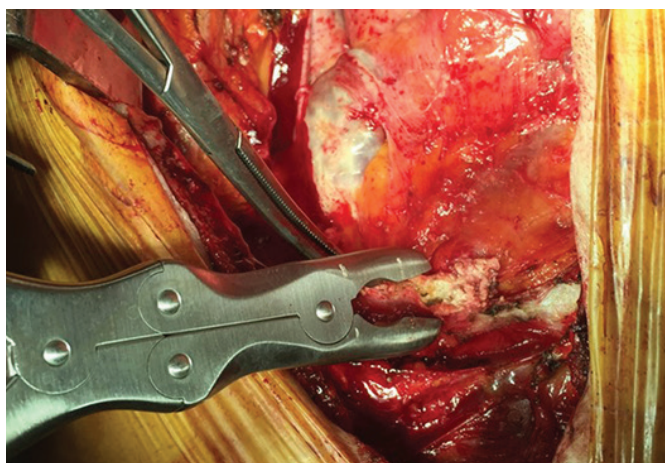
densely calcified pericardium.

We avoided electrocauterization to prevent thermal dysfunction. Also, phrenic nerves protected. Surgical loops (Design for Vision *3.5, US) were used during dissection and the operation. For an excellent exposure, an additional deep pericardial retraction suture was used. The pericardiectomy field was irrigated with 0.1 ml/sec flow %0.9 saline solution to aspirate microparticles. All patients were followed up by serial echocardiography which showed improvement. Also, nor late recurrence or mediastinal re-exploration was found.

In our research series, idiopathic-fibrous is the most frequent reason of chronic constrictive pericarditis (57.8%), but the second most common tuberculous pericarditis (21%) is soaring overall. Postoperative and neoplastic pericarditis are rare. Yetkin et al.^[2] have demonstrated that in developed western countries cases of uremic, postoperative, and neoplastic pericarditis are increasing. In order to maintain hemodynamic stability, we recommend early surgical intervention. Also, tuberculosis or neoplastic cases must be continued their specific medical treatment.

Hirai et al.^[8] detected that using an 'Ultrasonic Scalpel' is a useful method for treatment of chronic constrictive pericarditis, and advocate the use of the Ultrasonic Scalpel for a safe and easy pericardiectomy. The scalpel,

Figure 3. CT angiography image of dense constrictive pericarditis



curette, and rongeur are used for gouging out bone in neurosurgery and orthopedic surgery.^[5] Regarding the surgical treatment of severely calcific constrictive pericarditis, a rongeur can also be used in dissection of severely calcified pericardium. Another difficulty in cases, we used rongeur previously. We offer that a rongeur is very useful for peeling off the densely calcified pericardium. Phrenic nerve-during pericardiectomy must be protected. Global left ventricular regional wall motion should be observed carefully during the surgery.

Also, experienced surgical approach is essential for successful severe calcific pericardiectomy. In order to maintain hemodynamic stability; careful manipulation of the heart and pericardial incision, intra-aortic balloon pump and pacing wires preparation, pharmacological interventions, and anesthesia monitoring are very important. Inotropic agents are essential to maintain cardiac output during the manipulations. In addition, the availability of heart-lung machine and perfusionist are necessary for temporary support. The follow-up is required with a great experience. Fluid and electrolyte balance must be protected during the operation and intensive care unit.

Conclusion

Surgical treatment of severely calcific constrictive pericarditis has been shown to improve hemodynamic stability and can safely improve heart function. The preoperative functional status at mid-term follow-up was improved in all cases. Difficulty in cases, a rongeur may useful to gently peel off the calcified pericardium around the right and left ventricles. The article highlights the importance of considering different instruments in those research.

Study Limitations: *The primary limitation of our study is the lack of access to patient records before 2008. Long-term follow-up and large-scale prospective studies are needed to determine the frequency of severely calcific constrictive pericarditis.*

References

1. Goel PK, Moorthy N. Tubercular chronic calcific constrictive pericarditis. *Heart Views* 2011;12(1):40-1.
2. Yetkin U, Kestelli M, Yilik L, et al. Recent surgical experience in chronic constrictive pericarditis. *Tex Heart Inst J* 2003;30(1):27-30.
3. Liu S, Ma C, Ren W, et al. Regional left atrial function differentiation in patients with constrictive pericarditis and restrictive cardiomyopathy: a study using speckle tracking echocardiography. *Int J Cardiovasc Imaging* 2015(7):6.
4. Seidler S, Lebowitz D, Müller H. Chronic constrictive pericarditis. *Rev Med Suisse* 2015;11(476):1166, 8-71.
5. Budjan J, Haghi D, Henzler T, et al. Myocardial herniation in constrictive pericarditis mimicking arrhythmogenic right ventricular cardiomyopathy. *Eur Heart J* 2015(6):18.
6. Negishi K, Popović ZB, Negishi T, et al. Pericardiectomy is Associated with Improvement in Longitudinal Displacement of Left Ventricular Free Wall Due to Increased Counterclockwise Septal-to-Lateral Rotational Displacement. *J Am Soc Echocardiogr* 2015(6):1.S0894-7317(15)00383-1.
7. Ota T, Mizutani T. Microscopic anterior clinoidectomy with micro-rongeurs for a superior projecting paraclinoid internal carotid artery aneurysm: a technical note. *Br J Neurosurg* 2013;27(4):540-2.
8. Hirai S, Hamanaka Y, Mitsui N, et al. Surgical treatment of chronic constrictive pericarditis using an ultrasonic scalpel. *Ann Thorac Cardiovasc Surg* 2005;11(3):204-7.
9. DeValeria PA, Baumgartner WA, Casale AS, et al. Current indications, risks, and outcome after pericardiectomy. *Ann Thorac Surg* 1991;52(2):219-24.
10. Girardi LN, Ginsberg RJ, Burt ME. Pericardiocentesis and intrapericardial sclerosis: effective therapy for malignant pericardial effusions. *Ann Thorac Surg* 1997;64:1422-8.
11. Panchal P, Adams E, Hsieh A. Calcific constrictive pericarditis: a rare complication of CREST syndrome. *Arthritis Rheum* 1996;39(2):347-50.
12. Watanabe A, Hara Y, Hamada M, Kodama K, Shigematsu Y, Sakuragi S, et al. A case of effusive-constrictive pericarditis: an efficacy of GD-DTPA enhanced magnetic resonance imaging to detect a pericardial thickening. *Magnetic Resonance Imaging* 1998;16(3):347-50.
13. Lominadze Z, Kia L, Shah S, et al. Constrictive Pericarditis as a Cause of Refractory Ascites. *ACG Case Rep J* 2015;10;2(3):175-7.
14. Tsang MY, Choi JO, Borlaug BA, et al. Low-Flow, Low-Gradient Severe Aortic Stenosis in the Setting of Constrictive Pericarditis: Clinical Characteristics, Echocardiographic Features, and Outcomes. *Circ Cardiovasc Imaging* 2015;8(7):e002812.
15. Choi JH, Uhm JS, Lee SE, et al. Constrictive Pericarditis Long after a Gunshot Wound. *Korean Circ J* 2015;45(4):333-6.35.

Received: 04/08/2016

Accepted: 10/11/2016

Published: 20/12/2016

Disclosure and conflicts of interest:

The authors declare no conflict of interest.

Corresponding author:

Dr. Tuğra Gençpınar

Mail: tugra01@yahoo.com