



A Rare Case: Segmental Testicular Infarction

İbrahim Karabulut¹, Ali Haydar Yılmaz², Mahmut Koç², Şaban Oğuz Demirdöğen³

Abstract

Bu çalışmada nadir rastlanan segmental enfarktın, akut skrotumun ayırıcı tanıları arasında değerlendirmesini amaçladık. Ani skrotal ağrı nedeniyle başvuran 32 yaşındaki hastanın radyolojik değerlendirme sonucu testiste kanlanmayan kitle tespit edilmiş. Tümör markırları negatif olan hastaya parsiyel orşiektomi yapılmış. Segmental enfarkt tespit edilmiş. Akut skrotumun klinik ve radyolojik bulgular birlikte değerlendirilerek ayırıcı tanılar arasında segmental enfarkt da olabileceği göz önünde bulundurularak gereksiz orşiektomilerin önüne geçilmelidir. Bu tür hastalarda progresyon yoksa takip edilebileceği de akılda tutulmalıdır.

Anahtar Kelimeler: Enfarkt, segmental, testis

Introduction

Testicular infarction is usually observed globally, and its most common causative factor is testicular torsion. Testicular adnexa, acute epididymitis, and epididymo-orchitis can be included in the differential diagnosis. Strangulated inguinal hernia, segmental testicular infarction, testicular tumor, and idiopathic scrotal edema are among the rarer causes of acute scrotum. Global infarction is a diagnosis of urologic emergency. Segmental testicular infarction is a rare case, and it is seen in the second and fourth decades of life. Although its clinical symptom is similar to testicular torsion in the beginning, late acute stages and radiological images can be mixed with testicular tumors. Therefore, it may result in radical intervention. In the early period, it is observed as a heterogeneous hypochoic focus with an unclear margin. Infection, trauma, tumors, bleeding, iatrogenic causes, and torsion are responsible for its etiology (1). In our study, we aimed to present the case of a patient in whom we conducted partial orchiectomy due to the presence of testicular mass lesion and whose pathology result was indicative of segmental testicular infarction.

Case Report

A 32-year-old male patient applied our clinic due to left testicular pain. No pathology could be detected in his scrotal examination. It was learned from his anamnesis that he had undergone left varicocelelectomy a year ago, and his pain had begun afterward; it was also learned that he was infertile. The results of requested laboratory analyses were normal. A 18×15-mm mass lesion inside the left testis without hypochoic heterogeneous internal blood supply was observed on performing scrotal Doppler ultrasonography (GE Healthcare®; USA) and the right testis was observed to be normal. A 2-cm mass lesion not displaying apparent contrast enhancement in T2 sequences was observed when pelvic magnetic resonance imaging (MRI) (Siemens® Germany) in the patient with a pre-diagnosis of testicular tumor (Figure 1). No pathological lymph node was observed. Tumor marker levels were normal (lactic acid dehydrogenase : 98 U/L, alpha-fetoprotein: 1.92 ng/mL, and serum beta human chorionic gonadotropin: <1.2 mIU/mL). He was found to have oligospermia based on his spermiogram.

A decision of perform partial orchiectomy was made as there was no blood supply and contrast enhancement, his tumor marker levels were normal, he was infertile, and his tumor burden was below 30%. Informed consent was obtained from the patient. The layers were opened via a inguinal incision under general anesthesia. The testicle was passed through, and the tunica vaginalis and albuginea were opened. The lesion described in the radiological images was palpated in the testicle. It was opened (Figure 2) and removed after excising it from the surrounding tissues (Figure 3). Biopsies were taken from around the lesion. The defect that occurred was primarily closed (Figure 4). The patient was discharged without

¹Clinic of Urology, Bölge Training and Research Hospital, Erzurum, Turkey

²Department of Urology, Bilecik State Hospital, Bilecik, Turkey

³Department of Urology, Atatürk University School of Medicine, Erzurum, Turkey

Address for Correspondence:
Ali Haydar Yılmaz
E-mail: alicerrahcom@yahoo.com

Received: 16.09.2016

Accepted: 15.05.2017

© Copyright 2017 by Available online at
www.istanbulmedicaljournal.org

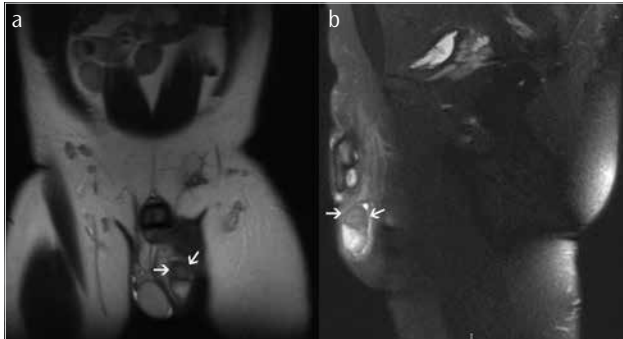


Figure 1. a, b. Magnetic resonance image of the lesion

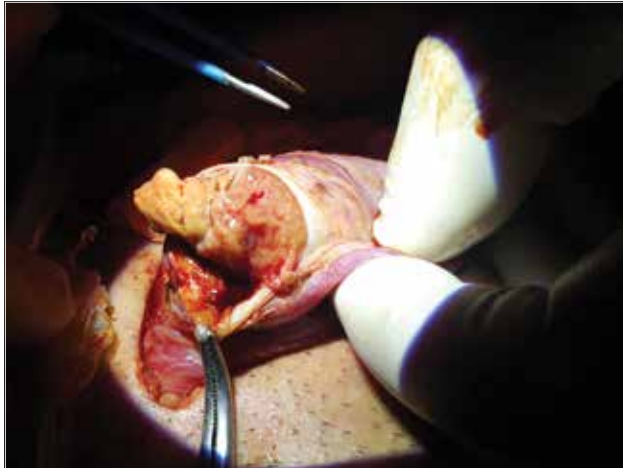

Figure 2. Open lesion

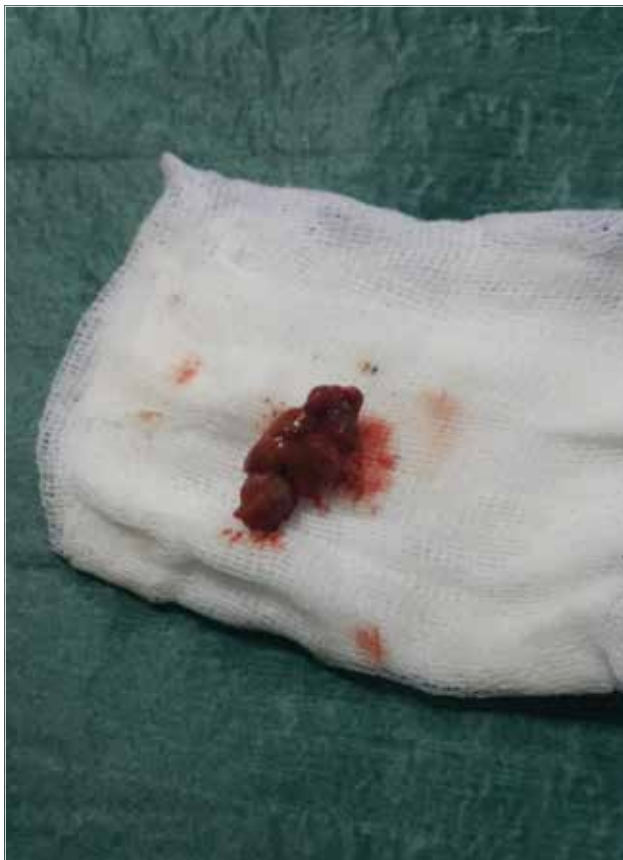

Figure 3. Excised lesion

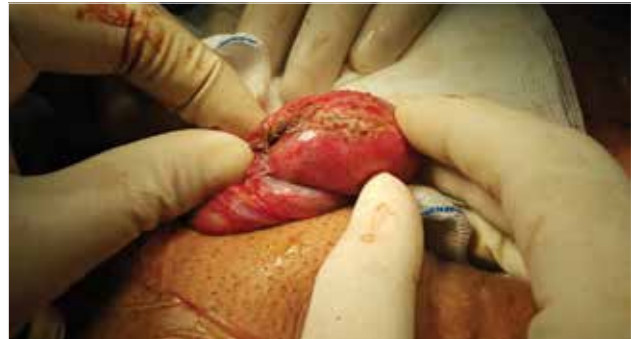

Figure 4. Covered testicular tissue

any complication on the postoperative day 2. The biopsies of the surrounding tissues around the testicle that displayed diffuse necrosis and atrophy were reported to be nonmalignant tissue.

Discussion

Segmental testicular infarcts are rarely seen. The causes of hemorrhagic infarcts are still controversial (2). The reason for the occurrence of hemorrhagic infarcts in the testicle or in one of its segments stems from the fact that the segmental regions are considered as functional end organs (3). Although there is no factor in most patients to determine the etiology, cholesterol embolism, malakoplakia, protein S or antitrombin III, vasculitides, sickle cell anemia, varicocele, epididymitis, and orchitis have been considered (4-6). Our patient had a history of undergoing varicocele, and connected segmental artery is accused as a possible etiological cause.

It was indicated in a series of 24 cases conducted by Bilagi et al. (7) that it can appear in different clinical presentations. Sudden-onset scrotal pain was present in all cases, which was similar to our case who present with sudden-onset scrotal pain. Fourteen of the patients had scrotal inflammatory disease, three of them were idiopathic, and five of them had spermatic cord torsion. The median age was detected to be 38 years, and this was similar to the age of our patient. They included 12 patients in the follow-up protocol, and no progression was observed in these patients. Arterial infarcts are more commonly seen in the upper pole of the testicle (8). A circular pattern on performing Doppler ultrasonography is more often associated with venous infarct secondary to epididymitis and germ cell tumor (9). The appearance in radiological imaging can be mixed with testicular tumor. MRI can also help make the diagnosis. It is effective in displaying the margins of the lesion (10). The differentiation of tumor and necrotic tissues in the magnetic resonance image is not always possible. In spite of accessible image modalities, the diagnosis of segmental testicular infarction is controversial. The radiological and pathological correlation is sub-optimal in most cases, and the final diagnosis is established by performing orchiectomy (11, 12).

A diagnosis of necrosis can be established by frozen examinations to be conducted during partial orchiectomy. When tumor markers are lacking and there is little doubt in terms of malignancy, delaying surgery and long follow-up protocols are recommended as alternatives to unnecessary orchiectomy. Surgery is necessary for patients displaying progression (13). In our case, we planned to

perform partial orchiectomy in the first session and then radical orchiectomy if necessary according to the pathological results. Our aim was to prevent unnecessary organ loss that could occur related with false positivity after frozen and avoid facing the patient with tumor burden related with false negativity. Furthermore, it has been suggested in guidelines that organ-preserving surgery can be performed if the tumor burden is below 30% in a single testicle. Another reason leading us to organ-preserving surgery was the disorder of the patient's sperm parameters and the fact that the patient was infertile. We performed surgery in the first place to take into consideration other differential diagnoses having similar clinical courses and prevent problems that may be experienced in the follow-up protocol. Moreover, radiological and pathological correlations remain suboptimal in most cases and the final diagnosis is established by performing orchiectomy.

Conclusion

Partial orchiectomy is increasingly used in the field of urology. A triangular-shaped hypoechoic unflushing region in a Doppler radiological image will help establish a diagnosis. False positivity and false negativity that can occur as a result of frozen in patients who have a testicular mass that is not very large have an expectation of fertility and have problems in their sperm parameters should be taken into consideration. Unnecessary orchiectomies should be avoided by evaluating clinical and radiological findings taking into consideration segmental testicular infarction can be in the differential diagnosis. It should also be kept in mind that organ-preserving surgery can be an alternative.

Informed Consent: Written informed consent was obtained from patient who participated in this case.

Peer-review: Externally peer-reviewed.

Author contributions: Concept - İ.K., M.K.; Design - İ.K., A.H.Y.; Supervision - A.H.Y., Ş.O.D.; Resource - İ.K.; Materials - İ.K.; Data Collection and/or Processing - İ.K.; Analysis and/or Interpretation - İ.K., A.H.Y.; Literature Search - M.K., Ş.O.D.; Writing - İ.K., A.H.Y.; Critical Reviews - İ.K., A.H.Y., M.K., Ş.O.D.

Acknowledgements: The authors would like to thank Prof. İsa Özbey.

Conflict of Interest: No conflict of interest was declared by the authors.

Financial Disclosure: The authors declared that this study has received no financial support.

References

1. Kantarcı F, Mihmanlı İ. Skrotal görüntüleme. *Trd Sem* 2015; 3: 59-70. [\[CrossRef\]](#)
2. Baratelli GM, Vischi S, Mandelli PG, Gambetta GL, Visetti F, Sala EA. Segmental hemorrhagic infarction of testicle. *J Urol* 1996; 156: 1442. [\[CrossRef\]](#)
3. Jordan GH. Segmental hemorrhagic infarct of testicle. *Urology* 1987; 29: 60-3. [\[CrossRef\]](#)
4. Secil M, Kocyigit A, Aslan G, Kefi A, Ozdemir I, Tuna B, et al. Segmental testicular infarction as a complication of varicocele: sono-graphic findings. *J Clin Ultrasound* 2006; 34: 143-5. [\[CrossRef\]](#)
5. Eisner DJ, Goldman SM, Petronis J, Millmond SH. Bilateral testicular infarction caused by epididymitis. *Am J Roentgenol* 1991; 157: 517-9. [\[CrossRef\]](#)
6. Paik ML, MacLennan GT, Seftel AD. Embolic testicular infarction secondary to nonbacterial thrombotic endocarditis in Wegener's granulomatosis. *J Urol* 1999; 161: 919-20. [\[CrossRef\]](#)
7. Bilagi P, Sriprasad S, Clarke JL, Sellars ME, Muir GH, Sidhu PS. Clinical and ultrasound features of segmental testicular infarction: six-year experience from a single centre. *Eur Radiol* 2007; 17: 2810-8. [\[CrossRef\]](#)
8. Bertolotto M, Derchi LE, Sidhu PS, Serafini G, Valentino M, Grenier N, et al. Acute segmental testicular infarction at contrast-enhanced ultrasound: early features and changes during follow-up. *AJR M J Roentgenol* 2011; 196: 834-41. [\[CrossRef\]](#)
9. Yusuf G, Sellars ME, Kooiman GG, Diaz-Cano S, Sidhu PS. Global testicular infarction in the presence of epididymitis: clinical features, appearances on grayscale, color Doppler, and contrast-enhanced sonography, and histologic correlation. *J Ultrasound Med* 2013; 32: 175-80. [\[CrossRef\]](#)
10. Fernandez-Perez GC, Tardaguila FM, Velasco M, Rivas C, Dos Santos J, Cambroner J, et al. Radiologic findings of segmental testicular infarction. *AJR Am J Roentgenol* 2005; 184: 1587-93. [\[CrossRef\]](#)
11. Aquino M, Nghiem H, Jafri SZ, Schwartz J, Malhotra R, Amin M. Segmental testicular infarction: sonographic findings and pathologic correlation. *J Ultrasound Med* 2013; 32: 365-72. [\[CrossRef\]](#)
12. Madaan S, Joniau S, Klockaerts K, DeWever L, Lerut E, Oyen R, et al. Segmental testicular infarction: conservative management is feasible and safe. *Eur Urol* 2008; 53: 441-5. [\[CrossRef\]](#)
13. Kim HK, Goske MJ, Bove KE, Minovich E. Segmental testicular infarction in a young man simulating a testicular tumor. *Pediatr Radiol* 2009; 39: 400-2. [\[CrossRef\]](#)

Cite this article as: Karabulut İ, Yılmaz AH, Koç M, Demirdöğen ŞO. A Rare Case: Segmental Testicular Infarction. *Istanbul Med J* 2017; 18: 236-8.