

## Insidious Threat of Children: Esophageal Foreign Body Ingestion

Atalay Şahin, Fatih Meteroğlu, Ahmet Erbey, Ahmet Sızlanan, Refik Ülkü

Department of Thoracic Surgery, Dicle University Faculty of Medicine, Diyarbakır, Turkey

### Abstract

**Objective:** Foreign body ingestion commonly occurs in children. Objects that may not easily pass the esophagus cause severe complications, such as impaction, perforation, and obstruction. Different methods are used for their removal. We aimed retrospectively to analyze the cases in which we performed emergent esophagoscopy.

**Material and Methods:** Between 2002 and 2013, 732 children with suspicion of foreign body ingestion were studied. Of them, 720 underwent emergency intervention. Objects located at the first narrowing of the esophagus were removed under sedation, and the remaining objects were taken out under general anesthesia with the aid of rigid esophagoscopy.

**Results:** The mean age of the children was 3.9 years (range 1 month and 16 years). Coins in 648 cases and a variety of objects, opaque and non-opaque, were removed under direct vision. Urgent intervention was carried out in 6 cases with dyspnea, in 2 delayed cases, and in 3 patients with esophageal perforation. Successful removal was performed in 69 patients (95.8%). Perforation occurred in 3 cases. Removal was succeeded within surgery in 2 cases (2.7%). One patient died.

**Conclusion:** A delay in esophageal body ingestion increases the complication rate. Round batteries and objects that are non-oval, long, large, and spiky should be dealt with great attention. (*JAEM 2014; 13: 159-61*)

**Key words:** Esophagus, foreign body, ingestion

### Introduction

Foreign body aspiration into the aerodigestive ways in both children and adults is a challenging condition and has mortality and severe morbidity. Children, generally, are prone to keeping numerous objects, whether they are edible or not, in their mouths and swallowing (1). Esophageal foreign bodies (EFBs) are commonly seen in children under 15 years. This rate is higher in children between 0-3 years, taking almost every material into their mouths. Existence of EFBs is kept in mind if there are typical digestive and respiratory complaints in those with a suspected aspiration history. A delay in the diagnosis represents severe and important life-threatening results. It presents a more stable condition than airway foreign bodies (2-4). Some objects can easily pass through the upper gastrointestinal tube; however, some hard, sharp, and long ones cause perforations and complications. Aspirated materials are impacted at anatomic and physiologic narrowings, the cricopharyngeal area, the crossing of the aorta and left main bronchus, and the lower esophageal sphincter. Most aspirated objects are coins; even they vary according to the region and culture (1). Less commonly seen objects are polygonal and sharp, pointed foreign bodies. They

can cause more serious complications. Button batteries causing toxicity and injuries, previous abdominal surgery, and diseases affecting swallow function and treatment take particular attention.

### Material and Methods

Between January 2002 and December 2013, in our department, 720 patients admitting with hypersalivation, dysphagia, pain, and coughing were retrospectively evaluated for age, gender, complaints, clinical signs, types of objects, impaction locations, radiologic results, preferred treatment options, admission times, length of hospital stays, morbidity, and mortality. Patients were evaluated radiologically with bi-plane x-rays following a physical examination and anamnesis. We tried to define the location and shapes of EFBs and whether they were opaque. Radiological studies with contrast medium and computerized tomography were ordered for those that were non-opaque and in patients with a suspected history. Removal procedures of EFBs under general anesthesia in the operation theater provided fasting duration and the symptoms of the patients. Coins and oval objects, seen at the first narrowing of the esophagus, were removed under sedation. Foreign bodies were attempted to be

*This study was presented at 9<sup>th</sup> National Trauma and Emergency Surgery Congress, 19-23 April 2013, Antalya, Turkey.*

**Correspondence to:** Atalay Şahin; Department of Thoracic Surgery, Dicle University Faculty of Medicine, Diyarbakır, Turkey  
Phone: +90 507 541 38 65 e-mail: atalaysahin44@yahoo.com

**Received:** 19.03.2014 **Accepted:** 30.04.2014

©Copyright 2014 by Emergency Physicians Association of Turkey - Available online at [www.akademikaciltip.com](http://www.akademikaciltip.com)  
DOI: 10.5152/jaem.2014.162



seen via direct laryngoscopy at the first narrowing when the patient was fully relaxed. For removal, a forceps was used to grasp ESBs in this way. The esophagus was checked up with rigid esophagoscopy. Other foreign bodies were endoscopically removed under general anesthesia. All patients were followed up for 24 hours regarding fever, chest pain, subcutaneous emphysema, and leukocytosis. Patients who swallowed liquid materials and different forms of drugs were excluded in this study.

### Statistical Analysis

This study was approved by the local ethic committee. The data provided were analyzed using Statistical Package for Social Sciences 15.0 (SPSS, Inc., Chicago, IL, USA). Chi-square test was used for comparison of categorical variables.  $p < 0.05$  was regarded as significant.

### Results

The mean age was 3.9 years (range 1 month-16 years). The majority of the patients was male (55%). Of 720 patients, 52.4% was 0-3 years old (Table 1). The most common and remarkable symptom was drooling in 50.4% of the patients. Admissions were within 6 hours of the event in 90% of cases and 24 hours in 3% of cases. Opaque view was present in 99% of cases (Figure 2 a, b, c, d). We did not find the esophageal pathology and recurrent EFB impaction in the questionnaire.

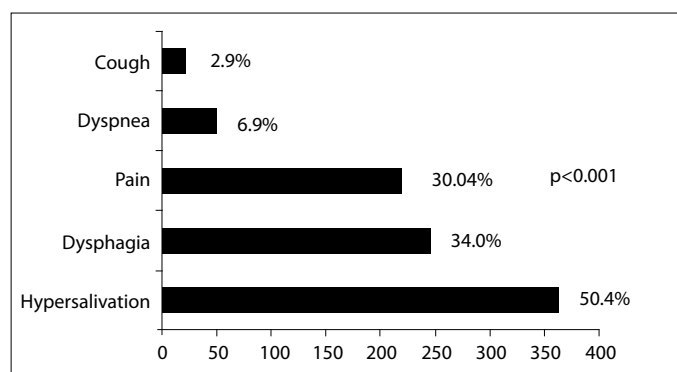
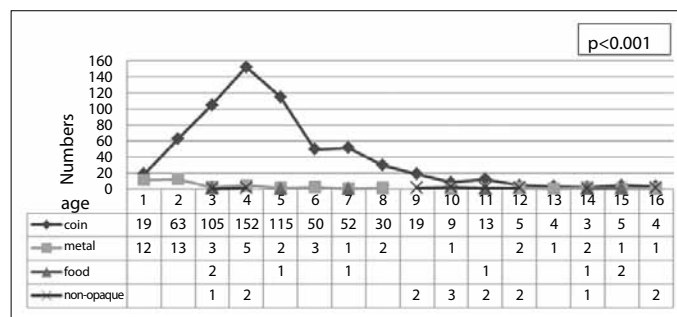
Coins were prominent among EFBs in 93% and successfully removed (Figure 3). The majority of EFBs was found in the first narrowing in 51.2%, and the remaining EFBs were in the second and third narrowing (35.4% and 13.4%, respectively) (Figure 4). Non-opaque and non-edible materials were commonly found at the lower narrowings. Prompt interventions were required in 6 patients, whose prominent symptom was dyspnea, and in 2 patients who were admitted 24 hours later. Out of coins, foreign bodies were successfully removed in 69 cases (96%) of 72 patients with opaque and non-opaque objects. Emergent procedure was required in 3 patients who had esophageal perforations. EFB could not be removed via esophagoscopy in 2 patients, and removal procedure was done after cervical and thoracic surgery (2.7%). One patient died due to acute mediastinitis.

### Discussion

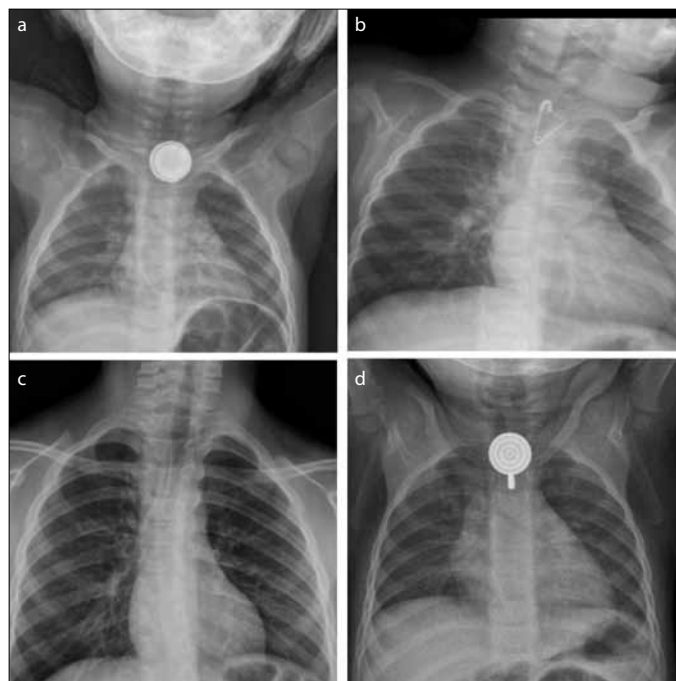
Obstruction following EFBs causes dysphagia, odynophagia, and chest pain. Obstruction may be total or partial. Objects generally impact at anatomical narrowings. Cervical esophagus or the first narrowing has been defined as the most common location in several studies (5-6). Obstruction at the proximal esophagus can cause obstruction of airways. An EFB, we managed, was found in the cervical esophagus in most cases of our study group. Decrease of peristaltic movements at the cricopharyngeus constriction leads to foreign body impaction.

EFBs may vary according to regions, cultures, and lifestyles (1). Symptoms of EFBs in children are different than those seen in adults. Symptoms in small children are drooling, dysphagia, discomfort, and cough (7). These findings are easily seen in the differential diagnosis of several diseases. Radio-opaque objects are easily seen on x-rays, and this makes the diagnosis easy (8). It is essential to undertake emergent procedures for patients with respiratory compromise without consuming time in the operating room. In these patients, objects, especially non-opaque, that are found at the second nar-

**Table 1.** Distribution of foreign bodies by age

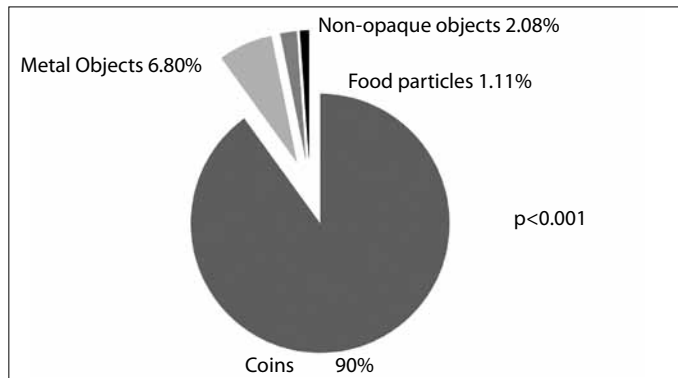


**Figure 1.** Symptoms caused by foreign bodies



**Figure 2. a-d.** Pictures of different foreign bodies in the esophagus

rowing can push the trachea and cause dyspnea, tachypnea, and wheezing. Emergent endoscopy should be done in children swallowing button batteries and sharp-pointed EFBs (7-9). Both of these kinds of objects and their removal can cause esophageal injuries and perforations, resulting in fatality (10). Batteries, which have a broad use in toys and daily life, create necrosis and perforations due to corrosive substance release and electrical discharge, in addition to



**Figure 3.** Distribution of aspirated foreign bodies

the pressure they produce toward the mucosa. Batteries including potassium and sodium cause liquefaction necrosis, and those including mercury and heavy metals lead to metal poisoning. Esophageal perforations present more severely and dangerously than those in other parts of the gastrointestinal system. Finding an EFB differs from objects in the lower parts of the gastrointestinal system. The esophagus does not have enough peristaltic movements to pass the foreign body away. Coins and oval objects, which are commonly seen among EFBs, can spontaneously proceed into the stomach. Batteries, unused and charged in particular, and magnetic materials cause mucosal injuries (11). Button batteries, which resemble coins, deserve special attention (11). Interventions without delay for EFBs without acute symptoms decrease the complication rates (12). Erosion, abrasion, and local tear can occur in delayed cases. EFBs impacted for a long time can be a source of fever. An EFB itself, waiting in the esophagus for a while, or difficulty of the procedure during esophagoscopy can result in perforations and, related to this, mediastinitis, sepsis, retropharyngeal abscess, and fistula between the esophagus and airways. Perforations that occur in the esophagus can cause acute mediastinitis associated with dyspnea and odynophagia. Delay in diagnosing perforations is associated with high mortality (13). After removal of an EFB, the probability of perforation, therefore, should be ruled out. EFBs in the thoracic part, which represent fewer findings and cause delays, have higher complication rates (14, 15). Perforations at the thoracic esophagus have a higher mortality risk than those seen at the cervical esophagus.

## Conclusion

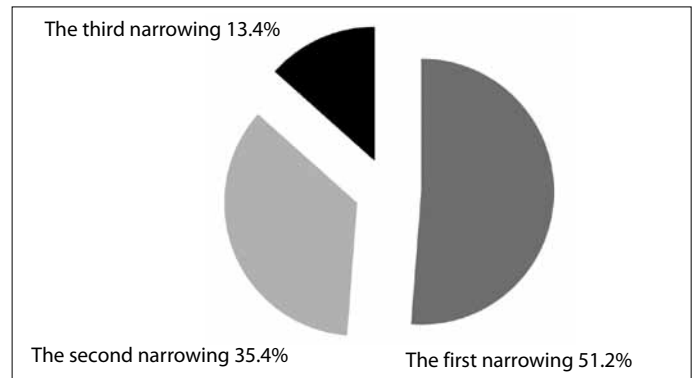
Early diagnosis and intervention are crucial for EFBs, which are challenging due to severe and life-threatening complications. Pediatric patients have to be kept with their parents and in the standing or sitting position in order to decrease anxiety and complications until the procedures are done. Rigid esophagoscopy is a safe procedure, even if there are alternative methods in the retrieval of EFBs. Patients should be carefully managed in regard to esophageal perforations resulting in fatality.

**Ethics Committee Approval:** Ethical committee approval was obtained from Dicle University Faculty of Medicine, 25.12.2013, 2013/36

**Informed Consent:** Due to the retrospective nature of this study, informed consent was waived.

**Peer-review:** Externally peer-reviewed.

**Author Contributions:** Concept - A.Ş., F.M., A.E.; Design - A.Ş., A.S., A.E.; Supervision - A.Ş., F.M., R.Ü.; Materials - A.E., F.M., A.S.; Data Collection and/or



**Figure 4.** Distribution of foreign bodies at constrictions

Processing - A.Ş., F.M.; Analysis and/or Interpretation - A.Ş., F.M., R.Ü.; Literature Review - A.Ş., A.E.; Writer - A.Ş., F.M.; Critical Review - A.Ş., F.M., A.E.

**Conflict of Interest:** The authors declared no conflict of interest.

**Financial Disclosure:** The authors declared that this study has received no financial support.

## References

- İnci İ, Özçelik C, Ülkü R, Eren N. Özofagus Yabancı Cisimleri: 682 Olgunun İncelenmesi. *GKDC Dergisi* 1999; 7: 148-52.
- Smith MT, Wong RK. Esophageal foreign bodies: types and techniques for removal. *Curr Treat Options Gastroenterol* 2006; 9: 75-84. [[CrossRef](#)]
- Li ZS, Sun ZX, Zou DW, Xu GM, Wu RP, Liao Z. Endoscopic management of foreign bodies in the upper-GI tract: experience with 1088 cases in China. *Gastrointest Endosc* 2006; 64: 485-92. [[CrossRef](#)]
- Lin HH, Lee SC, Chu HC, Chang WK, Chao YC, Hsieh TY. Emergency endoscopic management of dietary foreign bodies in the esophagus. *Am J Emerg Med* 2007; 25: 662-5. [[CrossRef](#)]
- Çobanoğlu U, Yalçınkaya İ. Özofagus yabancı cisimleri: 175 olgunun analizi. *Türk Göğüs Kalp Damar Cerr Derg* 2008; 16: 244-9.
- Wyllie R. Foreign bodies in the gastrointestinal tract. *Curr Opin Pediatr* 2006; 18: 563-4. [[CrossRef](#)]
- Balci AE, Eren S, Eren MN. Esophageal foreign bodies under cricopharyngeal level in children: an analysis of 1116 cases. *Interactive Cardiovascular and Thoracic Surgery* 2004; 3: 14-8. [[CrossRef](#)]
- Guloglu C, Aldemir M, Eren S, Kara İH. Acil Servise Başvuran Yabancı Cisim Olgularının Değerlendirilmesi *Türk Aile Hek Derg* 2003; 7: 67-72.
- Suvak B, Beyazit Y, Sayılır A, Kurt M, Torun S, Yeşil Y, et al. Özofagusta Yabancı Cisim Saptanan Olgularımızın Retrospektif Analizi. *Yeni Tıp Dergisi* 2011; 28: 159-63.
- Zhang S, Cui Y, Gong X, Gu F, Chen M, Zhong B. Endoscopic Management of Foreign Bodies in the Upper Gastrointestinal Tract in South China: A Retrospective Study of 561 Cases. *Dig Dis Sci* 2010; 55: 1305-12. [[CrossRef](#)]
- Yardeni D, Yardeni H, Coran AG, Golladay ES. Severe esophageal damage due to button battery ingestion: can it be prevented? *Pediatr Surg Int* 2004; 20: 496-501. [[CrossRef](#)]
- Cheng W, Tam PK. Foreign-body ingestion in children: experience with 1265 cases. *J Pediatr Surg* 1999; 34: 1472-6. [[CrossRef](#)]
- Başer M, Arslantürk H, Kisli E, Arslan M, Öztürk T, Uygan I, Kotan C. Primary aortoduodenal fistula due to a swallowed sewing needle: a rare cause of gastrointestinal bleeding. *Ulus Travma Acil Cerrahi Derg* 2007; 13: 154-7.
- Çevik M, Gökdemir MT, Gökdemir MT, Boleken ME, Söğüt O, Kürkçüoğlu C. The characteristics and outcomes of foreign body ingestion and aspiration in children due to lodged foreign body in the aerodigestive tract. *Pediatr Emerg Care* 2013; 29: 53-7. [[CrossRef](#)]
- Hurtado CW, Furuta GT, Kramer RE. Etiology of esophageal food impactions in children. *J Pediatr Gastroenterol Nutr* 2011; 52: 43-6. [[CrossRef](#)]