

What is Your Diagnosis: Ventricular or Pseudo-Ventricular Tachycardia?

Tanınız Nedir: Ventriküler Yoksa Psödo-Ventriküler Taşikardi?

Enes Elvin Gül, Mehmet Kayrak, Hasan Gök

Department of Cardiology, Meram School of Medicine, Selçuk University, Konya, Turkey

Introduction

Ventricular tachycardia (VT) is a life-threatening condition and its rapid development is very common even in the stable hemodynamic status. Artifacts on electrocardiograms are one of the main causes of the misinterpreting ventricular tachycardias. This case report showed that using accurate electrocardiographic algorithms for differentiation of tremor-induced pseudo-ventricular tachycardia can be useful for a rapid and accurate diagnosis of a true ventricular tachycardia.

Case Report

A 56-year-old man was admitted to the Emergency Department with chest pain. An electrocardiography (ECG) showed an acute anteroseptal myocardial infarction (Figure 1). The patient was referred to the cardiology department, and treatment was immediately started. The patient was administered streptokinase infusion. Under thrombolytic treatment, the ECG revealed suspicious ventricular tachycardia (VT) (Figure 2), and the patient's hemodynamic condition was normal. His blood pressure was 110/70 mmHg, and on physical examination, the patient was found to be in mild respiratory distress. The plasma level of both troponin I and creatine kinase-MB were elevated on admission, 7.6 ng/ml (reference value <0.01 ng/ml), and 37.1 ng/ml (reference value: 0.54-4.19 ng/ml), respectively. Because of suspicions of artifact, defibrillation was not performed. An ECG performed one minute later showed normal QRS complexes, and the possibility of a tremor-induced artifact was raised. The patient had a history of Parkinson's disease and used selegiline and biperiden.

Discussion

Knight et al found that the "notches sign" is especially useful in cases in which the native QRS complexes are not readily recognizable within the apparent instance of rapid, wide-complex tachycar-

dia (1). To confirm the presence of artifact, one need only establish that the notch-to-notch intervals correspond to the sinus RR intervals, which can easily be done in each of these recordings. Huang et al. (2) systematically created the accuracy of electrocardiographic algorithm for the differentiation of tremor-induced pseudo-VT from true VT. They used 3 electrocardiographic signs: "sinus" sign, "spike" sign, and "notch" sign, and created an electrocardiographic algorithm.

We recently observed an interesting case suggesting tremor-induced pseudo-VT and used the algorithm described by Huang et al. (2). In our case, 2 of 3 signs of the algorithm were present; sinus sign and notch sign. Sinus sign, as described by Huang et al, is a presentation of the sinus rhythm in the one of the frontal leads (leads I, II, and III). The notch sign was firstly described by Knight et al. (1) and is visible in the frontal leads except for lead I (Figure 2). Interestingly, tremor-induced pseudo-VT was detected during thrombolytic therapy. It is well known in the literature that non-sustained VT, polymorphic VT, and ventricular fibrillations might be electrocardiographic predictors of reperfusion. These signs are benign and point to revascularization.

There are only two case reports in the literature regarding Parkinson's tremor mimicking ventricular tachycardia (3, 4). However, in these cases the differentiation of the tremor-induced pseudo-VT from true VT was not confirmed using any accurate algorithm.

The possibility of artifacts as a cause of ECG findings should always be considered in an otherwise asymptomatic patient who is hemodynamically stable. Electrocardiographic changes suggesting artifacts may elicit unnecessary diagnostic or therapeutic procedures. This case highlights the importance of correlating ECG findings with the history and clinical examination and of using 12-lead ECGs for rhythm interpretation, particularly to confirm the consistency of arrhythmias in all leads.

Conflict of Interest

No conflict of interest was declared by the authors.

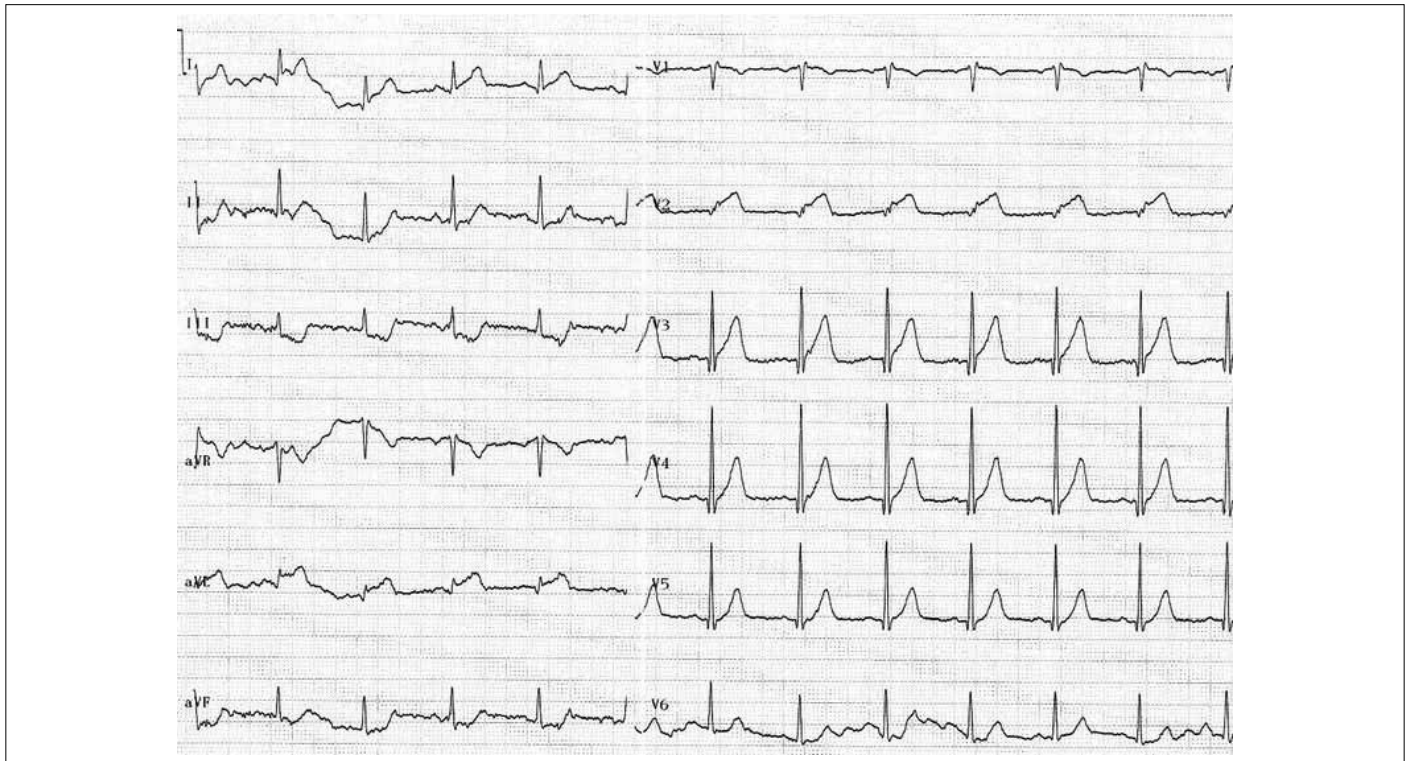


Figure 1. ECG on admission: 12-lead ECG showing normal sinus rhythm with ST segment elevation in the V1-V2 leads and aVL, and reciprocal ST segment depressions in leads II, III and aVF

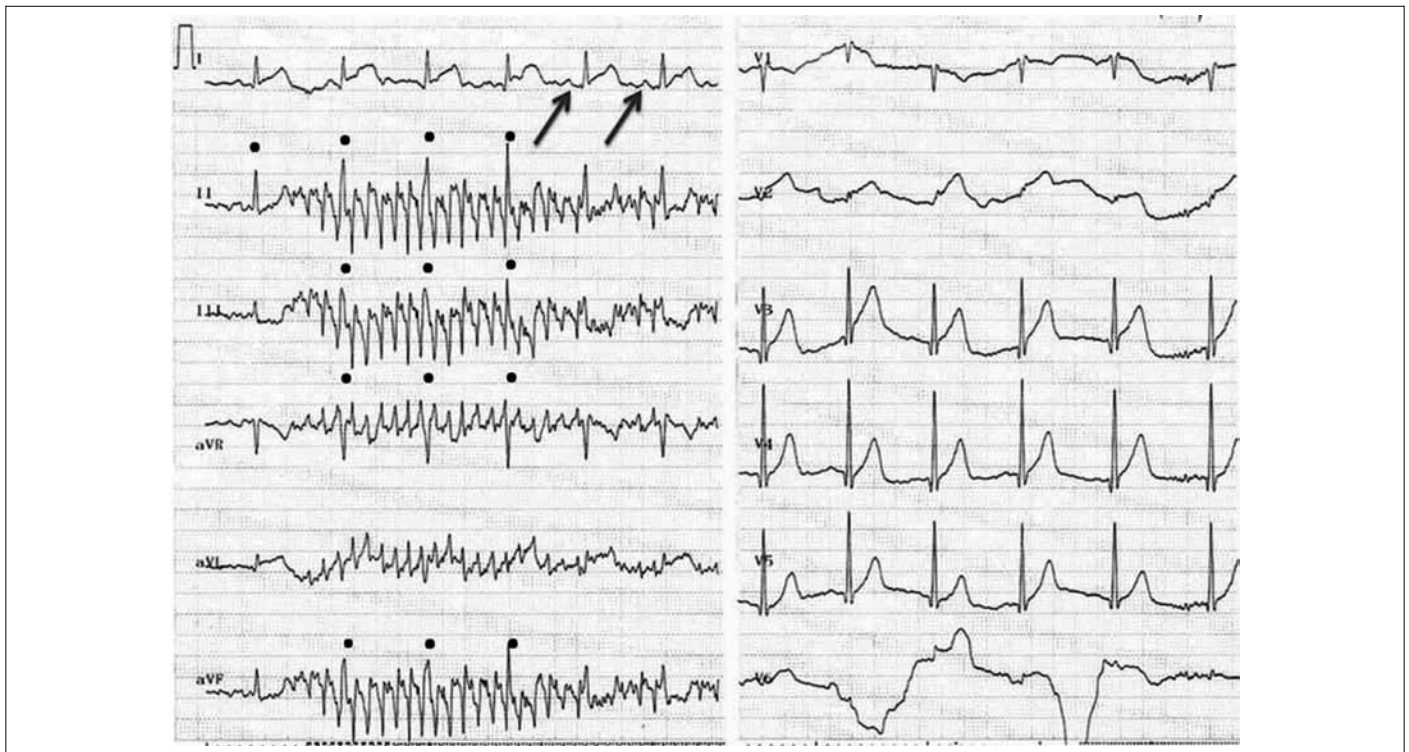


Figure 2. ECG during thrombolytic treatment which raised concerns about ventricular tachycardia. Note that VT was seen in limb leads and in each limb lead, time intervals (in milliseconds) between the black notches (demarcated by solid circles) are equal to or are simple multiples of the R-R intervals of the native beats. This is the "Notch sign" of ventricular tachycardia which was first demonstrated by Knight et al. Also, lead I shows a sinus rhythm (red arrows indicating regular P-waves following QRS complexes) which is the "Sinus sign" suggesting tremor-induced pseudo-VT

References

1. Knight BP, Pelosi F, Michaud GF, Strickberger SA, Morady F. Clinical consequences of electrocardiographic artifact mimicking ventricular tachycardia. *N Engl J Med* 1999; 341: 1270-4. [\[CrossRef\]](#)
2. Huang CY, Shan DE, Lai CH, Fong MC, Huang PS, Huang HH et al. An accurate electrocardiographic algorithm for differentiation of tremor-induced pseudo-ventricular tachycardia and true ventricular tachycardia. *Int J Cardiol* 2006; 111: 163-5. [\[CrossRef\]](#)
3. Bhatia L, Turner DR. Parkinson's tremor mimicking ventricular tachycardia. *Age Ageing* 2005; 34: 410-1. [\[CrossRef\]](#)
4. Boos CJ, Khan MY, Thorne S. An unusual case of misdiagnosed ventricular tachycardia. *Emerg Med J* 2008; 25: 173-4. [\[CrossRef\]](#)