

# An Unusual Penetrating Head Trauma

## *Alışılmadık Bir Penetran Kafa Travması*

<sup>1</sup>Mürteza ÇAKIR, <sup>2</sup>Zeynep ÇAKIR, <sup>2</sup>Mücahit EMET, <sup>2</sup>Sahin ASLAN,  
<sup>2</sup>Mustafa UZKESER, <sup>2</sup>Çetin Refik KAYAOĞLU

<sup>1</sup>Atatürk Üniversitesi Tıp Fakültesi, Nöroşirurji A. D, Erzurum  
<sup>2</sup>Atatürk Üniversitesi Tıp Fakültesi, Acil Tıp A. D, Erzurum

### ABSTRACT

**Background:** Penetrating injuries, except for ones caused by fire arms, may lead to limited damage due to low penetration speed.

**Case:** A 35-year-old male patient was brought to our clinic due to penetration of a nail to his head following falling down in the construction site where he was working. There were no focal or lateralizing neurological findings, nor were there any pathology related to the fundus of the eye. On the computed brain tomography, it was observed that the nail had penetrated from the lateral orbital wall into the orbita and it had reached the medial orbital wall by crossing the bulbus and orbital nerve. The patient underwent neurosurgery and ophthalmology consultations and an urgent operation was planned. No complications related to the wound or the operation occurred.

**Conclusion:** The purpose of surgery in penetrating head injuries is removal of the penetrating object and the debridement of the affected tissues following the emergent stabilization of the patient. Although intracranial and transorbital penetrating injuries tend to lead to local tissue damage, clinicians also should be focused on late complications.

**Key words:** Trauma, Penetrating Head Injuries, Trans Orbital Foreign Body, Nail

### Correspondence Author:

Yrd. Doç. Dr. Zeynep Çakır  
Atatürk Üniversitesi Tıp Fakültesi Acil Tıp AD  
Palandöken 25090 Erzurum, Türkiye  
Telefon (İş): + 90 442 316 63 03 – 1463  
Telefon (Cep): + 90 505 654 00 56  
E-Mail: zeynepcakir@hotmail.com

Received: 11.11.2008

Received after revision(s): 21.11.2008

Accepted: 21.11.2008

### ÖZET

**Giriş:** Günümüzde penetran kafa travmalarının en sık sebebi olan ateşli silah yaralanmaları dışında kalan penetran yaralanmalarda penetrasyon hızı düşük olduğu için hasar sınırlı kalabilir.

**Vaka:** 35 yaşında erkek hasta, çalıştığı inşaatta, kayıp düşmesi sonucu kafasına çivi saplandığı gerekçesiyle servisimize getirildi. Fokal veya laterilizan nörolojik bulgu, görme ve göz dibine ait patoloji tespit edilmedi. Bilgisayarlı beyin tomografisinde, çivi sol lateral orbita duvarından orbita içine girmiş ve bulbus ve orbital siniri arkadan çaprazlayarak orbita medial duvarına ilerlemiş olarak gözlendi. Nöroşirurji ve göz hastalıkları ile konsülte edilen hastaya, acil operasyon planlandı. Yaralanmaya veya operasyona bağlı komplikasyon izlenmedi.

**Sonuç:** Hastanın acil stabilizasyonunu takiben penetran yabancı cismin uzaklaştırılmasının hızlandırılması ve etkilenmiş bölgelerin debridmanı cerrahi tedavinin hedefidir. İntrakranial ve transorbital penetran yaralanmaları, lokal doku hasarı ile sonuçlanmak eğiliminde olsa da yalnızca başlangıç doku hasarına değil, aynı zamanda geç dönem komplikasyonlara da odaklanılmalıdır.

**Anahtar Kelimeler:** Travma, Penetran Kafa Travması, Trans Orbital Yabancı Cisim, Çivi

## INTRODUCTION

Penetrating brain and skull injuries are relatively less common than other types of head traumas and they constitute a proportion of 0.4% among all (1,2). In the recent century, the most common cause of penetrating head traumas are firearm wounds; but in the past, the most common were knives (3). A relatively rare cause of penetrating head traumas is accidental injury with penetrating objects (4). Although the calvarium is an effective barrier, thinner bone areas such as the temporal region and the orbit make the penetration of the sharp objects possible (5).

The basic treatment approaches in penetrating head injuries caused by firearms or other reasons are similar, including the basic surgical approach, prevention of early and late infections, control of increased intracranial pressure and prevention of secondary damage to the injured area. On the other hand, the damage is limited in penetrating head traumas caused by objects other than firearms, because the speed of penetration is low, but these kinds of wounds are specific, since the penetrating object may keep its presence in the wound and be contaminated (6,3).

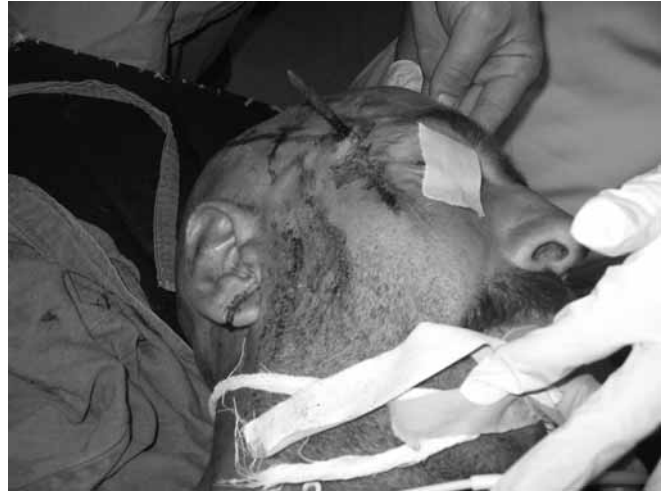## CASE REPORT

A 35-year-old male patient was brought to our clinic due to penetration of his head by a nail following a sliding fall from the standing position without rolling, at the construction site he was working.

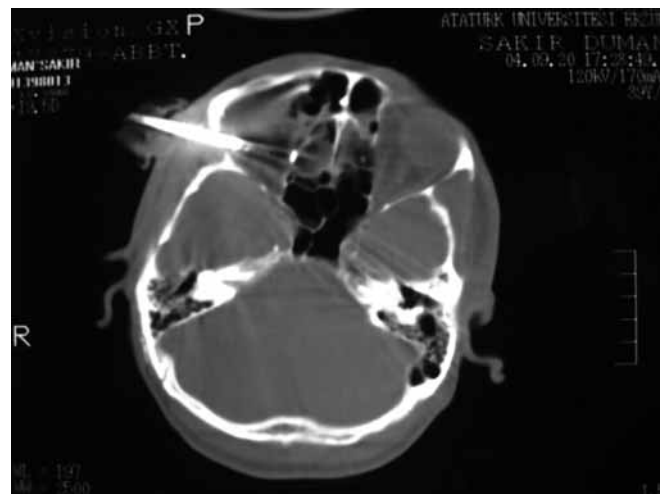
On the initial evaluation performed in the emergency unit of the hospital the general status of the patient was moderate; he was conscious, Glasgow Coma Scale (GCS):15 (E4M6V5), orientated, cooperative, and vital signs were within normal limits and stable. On physical examination, a rusty nail, approximately 15 cm long was seen to have penetrated into the left lateral wall of the orbit from above the zygomatic bone in its half length, with its blunt end (not the sharp, pointed end) (Figure 1). There were no focal or lateralizing neurological findings, nor were any pathologies related to the fundus of the eye or vision. Examinations of other systems were unremarkable.

On the antero-posterior, left lateral and town direct skull X-rays, the nail in question was observed to have been stuck in the skull from its head portion half its length. On CBT, it was observed that the nail had penetrated from the lateral orbital wall into the orbit, reaching the medial orbital wall by crossing the bulbus and the orbital nerve from their posterior aspects (Figure 2). No additional intraorbital or intracranial pathologies were noted. The patient was administered 500 IU intramuscular (IM) human antitetanus immunoglobulin and 3000 IU IM tetanus antiserum. The patient underwent consultations by the neurosurgery and ophthalmology departments and an emergency surgery was planned. Due to lack of an orbital surgery team, it was recommended that the patient be dispatched to a center where orbital surgery could be performed.

The foreign body was removed with general anesthesia in the operating room. Four parenteral antibiotics were administered to the patient in the postoperative period. The patient had no problems of vision. No injury-related or any peri-operative complications occurred. The patient was discharged on the seventh postoperative day. No complication occurred on follow up in the first month.



(Figure 1)



(Figure 2)

## DISCUSSION

The emergency treatment of penetrating head injuries requires local homeostasis, as well as the traditional ABC approach and a security circle (7). Because these injuries are closed fractures, prophylaxis for tetanus and wide spectrum antibiotics which can pass the blood-brain barrier should be administered (6,7). In our patient, an injury with a rusty and contaminated object (a rusty construction nail) in quite a dirty environment was in question. Therefore, prophylaxis for tetanus and intravenous antibiotics were administered during the stabilization in the emergency unit simultaneously with diagnostic procedures.

The basic aims of surgery are prompt removal of the penetrating foreign material and the debridement of the scalp, skull, dura and the affected parenchyma (8). Our patient was operated in the first hour of his admission to our hospital, where the foreign material was removed and appropriate debridement was provided. Transcranial foreign material injuries have their own injury mechanisms on neuronal and vascular structures. They are separated from firearm injuries on the basis of the speed of the wounding mechanism and the absence of the concentration zone around the coagulation necrosis which is a finding in firearm injuries (6,9). Although these kinds of low speed penetrating injuries tend to

conclude as local brain damage rather than a diffuse injury, possibilities such as late-stage brain abscesses, cerebrospinal fistula formation, vascular thrombosis and hemorrhages should be considered besides the initial brain damage.

Long and thin objects carry considerable risks for intracranial and intraorbital areas. The shape and the position of the eye ball and the orbit provide a tendency for direct penetration towards the internal carotid artery, which is one of the weak points of the orbit<sup>(6,10)</sup>. In case of intraorbital foreign bodies, loss of vision may occur in the acute period due to the effect of the object on the globe, optic nerve, ocular blood supply, or in late periods it may emerge as a complication of infection. Foreign bodies such as glass, pieces of wood or metals are tolerated well, whereas organic substances are not<sup>(11,12)</sup>. The complications of penetrating transorbital foreign materials are proptosis, chronic fistulae, diplopia, orbital cellulitis, limitation of eye movements, injury to eye muscles and the optic nerve, endophthalmitis or panophthalmitis, hemorrhage into brain parenchyma, meningitis, epilepsy, brain abscess and tetanus. A CSF fistula may occur as a complication. These fistulae may cause edema of the eyelids by the orbital route (orbitorrhea), or may present as rhinorrhea because of a fracture in the cribriform plate<sup>(13)</sup>. In series of 8 cases by Khalil et al., it was reported that two patients had late carotid-cavernous fistulae and others had optic nerve, ocular nerve, eyeball and lacrimal gland injuries and/or injuries of cerebral tissues. Our patient had none of these early or delayed complications<sup>(6)</sup>.

In conclusion, orbitocranial penetration of foreign materials may lead to life-threatening or restricting effects due to their impact on the brain parenchyma, cavernous sinus and important cerebral arteries and veins. Therefore, foreign materials which extend into the orbital cavity are also close interest in neurosurgery, a separate discipline.

## REFERENCES

- Hayashi Y, Fujisawa H, Tohma Y, Yamashita J, Inaba H. Penetrating head injury caused by bear claws: case report. *J Trauma*. 2003; 55:1178-80.
- Ishikawa E, Meguro K, Yanaka K, Murakami T, Narushima K. Intracerebellar penetrating injury and abscess due to a wooden foreign body. *Neurol Med Chir*. 2000; 40: 458-62.
- O'Neill OR, Gilliland G, Delashaw JB, Purtzer TJ. Transorbital penetrating head injury with a hunting arrow: Case report. *Surg Neurol*. 1994; 42: 494-7.
- Cooper PR. Gunshot wounds of the brain. In: Cooper PR, ed. *Head injury*. 3 rd ed. Baltimore: Williams& Wilkins, 1993; 355-71.
- Bauer M, Patzelt D. Intracranial stab injuries: case report and case study. *Forensic Science International*. 2002; 129: 122-7.
- Khalil N, Elwany MN, Miller JD. Transcranial stab Wounds: morbidity and medico legal awareness. *Surg Neurol*. 1991; 35: 294-9.
- Ardill W, Gidado S. Penetrating head wound. A remarkable case. *Seurg Neurol* 2003; 60: 120-3.
- Kelly DF, Nikas DL, Becker DP. Diagnosis and treatment of moderate and severe head injuries in adults. In: Youmans JR, ed. *Neurological Surgery*. 4 th ed. Philadelphia: WB Saunders, 1996; 1618-1718.
- Safer G, Costella GB; Mattana R, Mattana M, et al. Multiply craniocerebral injuries from penetrating mails. Case Illustration. *J.Neurosurg* 2004; 100: 963.
- Vaicy C, Hunt CD, Heary RF: Successful recovery after an orbitocranial injury. *Ophtal Plast Reconstr Surg*. 2003; 19: 359- 63.
- Belin MW. Foreign bodies and penetrating injuries to eye. In: Catalano RA, Belin M, editors. *Ocular emergencies*. Philadelphia: W.B. Saunders Company, 1992; 197-213.
- Al B, Orak M, Özhasenekler A, İçer M, Çakmak E. Delici İntrakraniyal Yabancı Cisim Yaralanması: Olgu Sunumu. *Akademik Acil Tıp Dergisi*. 2007; 6: 29-31.
- Civelek E, Bilgiç S, Kabataş S, Hepgül KT. Penetran transorbital uzanımlı intrakranial yabancı cisim. *Ulus Travma Acil Cerrahi Derg* 2006;12: 245-48.