

A THORACIC SPINAL FRACTURE AND INSTABILITY: CASE REPORT

YÜRÜMEZ Y.*, ASLAN A.** , SOLAK O.***, ESER O.** , ESME H.***, YAVUZ Y.*

*Associate Professor of Emergency Department, M.D.

**Associate Professor of Neurosurgery, M.D.

***Associate Professor of Thoracic Surgery, M.D.

Afyon Kocatepe University, Faculty of Medicine, Department of Emergency Medicine, Afyonkarahisar, Turkey.

İletişim adresi ve Sorumlu Yazar: Dr. Yusuf YÜRÜMEZ, Afyon Kocatepe Üniversitesi Tıp Fakültesi, Acil Servis, 03200 Afyonkarahisar.
Phone : 0 272 214 20 65 - 3015, Fax : 0 272 213 30 66, e_mail : yusufyurumez@yahoo.com

Başvuru Tarihi: 24.07.2007

Kabul Tarihi: 07.01.2008

SUMMARY

Early diagnosis of upper thoracic spinal injuries has been shown to be very important. Failure of an early diagnosis during initial examination can cause a ten-fold increase in the probability of neurological deficit in patients. Fractures of the upper thoracic spine due to trauma may be associated with sternal injuries. The focus of this study is to attract the attention to the instability caused by the combination of both spinal and sternal fractures. Patients in such conditions should be considered unstable and a treatment plan should be followed accordingly.

Keywords: Trauma; Upper Thoracic Spine; Sternum; Fractures.

TORASİK SPİNAL FRAKTÜR VE İNSTABİLİTE: OLGU SUNUMU

ÖZET

Üst torakal spinal yaralanmaların erken tanısı son derece önemlidir. İlk muayene esnasındaki erken tanıdaki yetersizlik hastada meydana gelebilecek olan nörolojik defisit riskini 10 kat artırabilir. Travmadan kaynaklanan üst torakal spinal fraktürler sternal yaralanmalarla birlikte olabilir. Bu yazının amacı spinal ve sternal fraktürlerin birlikte olduklarında meydana getirdikleri instabiliteye dikkat çekmektir. Bu durumdaki hastalarda instabilite göz önünde bulundurulmalı ve tedavi planı da buna göre düzenlenmelidir.

Anahtar Kelimeler: Travma; üst torakal vertebra; sternum; fraktür.

THORACIC SPINAL FRACTURE AND INSTABILITY: CASE REPORT

Case report

A 20 year-old male patient applied to the emergency department due to a traffic accident. Medical history was received from the patient. He said that it was an in-vehicle accident; the vehicle tumbled a few times, and his head hit to the roof of the vehicle.

The patient was discharged from another hospital after the initial treatment. The initial diagnosis of patient at the other hospital was soft tissue injury and scalp laceration. One hour after his discharge, he admitted to our emergency department with a headache, back pain, and nausea and vomiting complains. His vital signs were normal with no chest discomfort.

In his physical examination, there was a 7 cm sutured cut on the scalp at the back part of the head. Besides, he had an obvious tenderness on his upper thoracic region and on the corpus sternum with palpation. He had no symptoms of cardio-pulmonary compromise and no neurological

defect.

Radiologically, there was a non-displaced corpus sternal fracture line and also a wedge fracture in the T5 vertebrae (Figure 1). His chest X-ray was normal. In the Thoracic Computerised Tomography, there was a wedge fracture in the anterior column and a lamina fracture in the posterior column which was not seen at direct reontgenogram (Figure 2). As a result of our clinical evaluation, we accepted this patient instable according to Magerl classification, because the anterior elements were destroyed (2 point), posterior elements were destroyed (2 point), and there was a relative sagittal plan rotation > 5 degrees (2 point, in our patients 17 degrees)⁶. Therefore, in our patient, we performed posterior transpedicular stabilization (Figure 3). A surgical intervention was not necessary for the sternal fracture. He was monitored radiologically and analgesia was provided when necessary. In our case, the patient did not develop any complication and was discharged eight days after the operation.

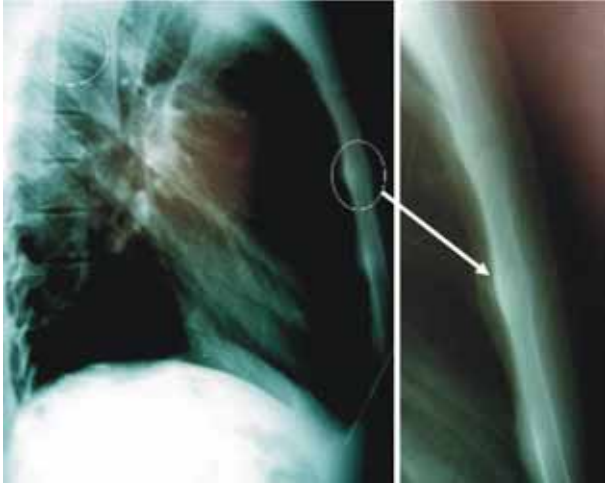


Figure 1: Sternal radiography: a non-displaced *ü*corpus sternal fracture line and also a wedge fracture of 5 vertebrae.

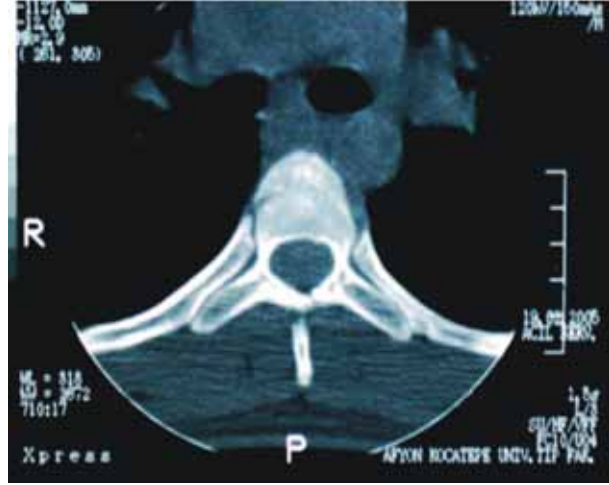


Figure 2: Computerized tomography (CT) scan: the wedge fracture in the anterior column and lamina fracture in the posterior column (T5 vertebrae).

Discussion

Upper thoracic spinal injuries are rare when compared with cervical and thoracolumbar spinal fractures. Nevertheless, they nearly always present with accompanying major injuries.⁴

The association between upper thoracic spine and sternum fractures has previously been documented.^{2,7} Sternal fractures most commonly result from direct trauma and violent flexion injuries of the spine, and are typically midbody and transverse.⁸

The initial diagnosis of upper thoracic spinal fractures remains based on plain films and clinical awareness. In patients who have undergone significant injuring forces, which result in flexion and twisting of the thoracic spine, the diagnosis should be actively sought. This should consist of a careful inspection and palpation of the back, where gaps between spinous processes may be felt within soft tissue swelling.⁴

The importance of an early diagnosis of thoracic spinal fractures was demonstrated by Reid et al., who showed a ten-fold increase in the incidence of neurological deficit in patients in whom the diagnosis was initially missed.⁹ Similarly in our case, the diagnosis was initially missed. Fortunately enough, the patient has arrived to our emergency room just in time, so that right diagnosis was achieved, and a neurological deficit was avoided. The treatment of instable thoracic spine fractures remains controversial despite an increased knowledge of the morphometric, anatomic, and biomechanical features of thoracic vertebrae.¹⁰ There is no consensus regarding optimal treatment and various conservative and operative options have been described in the literature with different inclusion criteria, follow-ups and evaluation tools.¹¹ Schweighofer et al. briefly described a series of 6 patients with Magerl type B or C lesions in the upper and middle thoracic spine and operated these patients.¹² Similarly, our

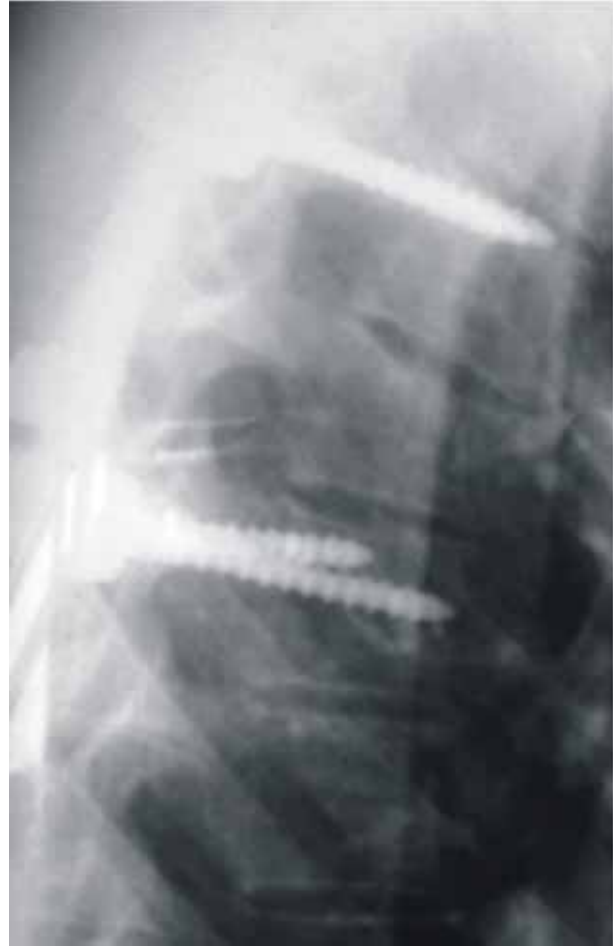

Figure 3: Lateral thoracic radiography: posterior transpedicular stabilization.

case was accepted as Type B according to Magerl classification. Furthermore, our patient had a combination of spinal and sternal fractures. For these reasons, the case was accepted unstable and underwent a posterior transpedicular stabilization.

As a result, isolated compression fractures of the thoracic spine are generally stable but this case illustrates that the combination of isolated compression fractures of the thoracic vertebrae with a sternal fracture may be unstable. Patients in such conditions should be considered unstable and a treatment plan should be followed accordingly.

References

- 1- Baron BJ, and Scalea TM. Spinal cord injuries. In: Tintinalli JE, Kelen GD, Stapczynski JS, editors. Emergency medicine: a comprehensive study guide. 5th ed. New York: McGraw-Hill; 2003. pp:1569-83.
- 2- Lund JM, Chojnowski A, Crawford R. Multiple thoracic spine wedge fractures with associated sternal fracture; an unstable combination. *Injury* 2001; 32:254-55.
- 3- Watkins R 4th, Watkins R 3rd, Williams L, et al. Stability provided by the sternum and rib cage in the thoracic spine. *Spine* 2005;30:1283-6.
- 4- van Beek EJ, Been HD, Ponsen KK, Maas M. Upper thoracic spinal fractures in trauma patients - a diagnostic pitfall. *Injury* 2000;31:219-23. Dalvie SS, Burwell M, Noordeen MHH. Haemothorax and thoracic spinal fracture. A case for early stabilization. *Injury* 2000;31(4):219-23.
- 5- Dalvie SS, Burwell M, Noordeen MHH. Haemothorax and thoracic spinal fracture. A case for early stabilization. *Injury* 2000;31(4):219-23.
- 6- Magerl F, Aebi M, Gertzbein S, Harms J, Nazarian S. A comprehensive classification of thoracic and lumbar injuries. *Eur Spine J* 1994;3:184-201.
- 7- Jones HK, McBride GG, Mumby RC. Sternal fractures associated with spinal injury. *J Trauma* 1989;29:360-64.
- 8- Edwards D, Ward N. Sternal fracture as a complication of normal vaginal delivery labour. *Inj Extra* 2007;38:230-40.
- 9- Reid DC, Henderson R, Saboe L, Miller JD. Etiology and clinical course of missed spine fractures. *J Trauma* 1987;27:980-86.
- 10- Yue JJ, Sossan A, Selgrath C, Deutsch LS, et al. The treatment of unstable thoracic spine fractures with transpedicular screw instrumentation: a 3-year consecutive series. *Spine* 2002;27:2782-87.
- 11- Payer M. Unstable upper and middle thoracic fractures. Preliminary experience with a posterior transpedicular correction-fixation technique. *J Clin Neurosci* 2005;12:529-33.
- 12- Schweighofer F, Hofer HP, Wildburger R, Stockenhuber N, Bratschitsch G. Unstable fractures of the upper thoracic spine. *Langenbecks Arch Chir* 1997;382:25-28.