

Case Report: *Isospora belli* Infection in A Renal Transplant Recipient

Özgür KORU¹, R. Engin ARAZ¹, Yakut AKYÖN YILMAZ², Sibel ERGÜVEN²,
Müjdat YENİCESU³, Bayram PEKTAŞ¹, Mehmet TANYÜKSEL¹

¹Gülhane Askeri Tıp Akademisi, Tıbbi Parazitoloji Bilim Dalı, Ankara, ²Hacettepe Üniversitesi, Mikrobiyoloji ve Klinik Mikrobiyoloji Anabilim Dalı, Ankara, ³Gülhane Askeri Tıp Akademisi, Nefroloji Bilim Dalı, Ankara

SUMMARY: *Isospora belli*, an opportunistic protozoan, is one of the most commonly recognized causes of diarrhea in patients with acquired immunodeficiency syndrome (AIDS). Infection is acquired through fecal contaminated food or water, and generally diagnosed by examination of stool and/or duodenum biopsy specimens with acid-fast staining. Here, we present an uncommon case, chronic diarrhea caused by *I. belli* infection in a patient who is a renal transplant recipient.

Key Words: *Isospora belli*, chronic diarrhea, renal transplant

Olgu Sunumu: Böbrek Transplantasyonlu Bir Hastada *Isospora belli* İnfeksiyonu

ÖZET: *Isospora belli*, akkız immün yetmezlikli sendromlu hastalarda en sık rastlanılan ishal etkenlerinden biri olan fırsatçı protozoon-
dur. İnfeksiyon dışkı ile kontamine yiyecek veya su yoluyla bulaşır ve genellikle dışkı ve / veya duodenum biopsi örneklerinin asit-fast boyamalarıyla tanısı konmaktadır. Bu çalışmada, Türkiye’de yaşayan böbrek transplantasyonu geçirmiş (alıcısı) olan kronik ishalleri bir hastada *I. belli* enfeksiyonu sunulmaktadır.

Anahtar Sözcükler : *Isospora belli*, kronik ishal, böbrek transplantasyonu

INTRODUCTION

Isospora belongs to the coccidia subclass in the family Eimeria. *Isospora belli* is only known to infect humans. *Isospora (I.) belli* is transmitted mainly by ingestion of infective oocysts in faecal contaminated food or water. Infected individuals may be asymptomatic carriers or suffer gastrointestinal disease ranging from mild to severe (10). Clinically; *I. belli* most commonly mimics giardiasis, with a malabsorption syndrome characterized by loose, foul-smelling stools. *I. belli* infection in immunocompromised patients has rarely been described; this is the second report of *I. belli* infection in a renal transplant recipient, in Turkey.

CASE REPORT

A 32-year-old man had undergone renal transplantation in June 1993. He was admitted to the emergency room at Gülha-

ne Military Medical Faculty Hospital, Ankara, on August 2003, with an acute onset of abdominal cramps, watery diarrhoea, low-grade fever, and nausea. The diarrhoea was described as pale yellow without blood or mucus. He had 8-10 episodes per day. Urinalysis did not show hematuria or signs or urinary tract infection. Physical examination was normal, except the auscultation of high-amplitude bowel sounds. Biochemical laboratory tests indicated normal values. He was also tested for HIV, and results were negative at baseline. The patient had no travel history to foreign countries. Stool examinations showed *Entamoeba histolytica*. Treatment with metronidazole showed a dramatic improvement in his condition. In September 2003, abdominal cramps, watery diarrhoea (8-10 episodes per day), and low-grade fever developed again, therefore he admitted to Hacettepe University, Medical Faculty Hospital, emergency service. Routine laboratory tests were performed and only stool culture showed the presence of *Salmonella typhi* C. Routine ova and parasite examination, by an ethyl alcohol-formaldehyde concentration technique, once with and once without iodine for staining, revealed suspicious oocyst like features therefore acid-fast stain was performed on a fresh smear. *I. belli* oocysts

Geliş tarihi/Submission date: 08 Aralık/08 December 2006

Düzeltilme tarihi/Revision date: 20 Şubat/20 February 2007

Kabul tarihi/Accepted date: 13 Mart/13 March 2007

Yazışma /Corresponding Author: Mehmet Tanyüksel

Tel: - Fax: -

E-mail: mtanyuksel@gata.edu.tr

This work was presented in the 9th Congress of Balkan Military Medical Committee (21-24 June 2004, Antalya).

were detected by acid-fast stain. No other intestinal parasites were determined at that time. He was treated with ciprofloxacin for *Salmonella typhi* C, resulting in improvement. Several weeks later, he was readmitted to Gulhane Military Medical Faculty Hospital, because of abdominal cramps, watery diarrhoea, and weight loss. Results of conventional stool examinations were negative, but once more *I. belli* oocysts were detected by acid-fast stain. Therefore the patient was again treated ciprofloxacin intravenously for three days. One week later, *I. belli* oocysts were still detected on acid-fast stained preparations. Complete improvement of the patient was achieved at doses (160 mg of trimethoprim and 800 mg of sulfamethoxazole) of one double-strength (DS) tablet bid orally TMP-SMX-DS for 10 days.

DISCUSSION

I. belli is distributed worldwide particularly endemic in tropical and subtropical regions but has been infrequently detected in stool specimens. Although the infection frequently occurs in the immunocompromised patient, it can also cause disease in adults and children. The diagnosis of *I. belli* is done by the examination of stool and/or duodenum biopsy specimens. Acid-fast staining is used for the detection of *I. belli* oocysts. They are easily determined in stool as long as there are adequate numbers. Fluorescence microscope is used for *Isospora* detection as it can be stained by the fluorescent dyes auramine - rhodamine (5). The routine diagnosis of *I. belli* infection is difficult, especially if the concentrated sediment is from polyvinyl alcohol – preserved stool. The oocysts of the organism, is hard to differentiate from some matters in faeces, and making an ultimate diagnosis (5). The recent emergence of some of the intestinal coccidian as a pathogen in subjects with immune deficiency syndromes has led to the use of specialized permanent staining methods for their recognition and identification. A variety of acid-fast stains have proven to be greatly valuable in the diagnosis of *I. belli* infections.

There are some reports indicating that it is easier to identify autofluorescent oocysts with fluorescence microscopy because it does not require staining (1). However, we detected even the small amounts of oocysts in this patient's stool by acid-fast staining. It should be noted that if the stool preparations are not examined carefully, oocysts might be misinterpreted due to the faecal compounds by iodine staining. With oocysts of *I. belli*, the inner germinal mass (sporoblast) stains an intense red (Figure 1).

There are several reports on intestinal isosporiasis. In a report from Venezuela, patients infected with human immunodeficiency virus (HIV), *Isospora* infection was determined in 56 of 397 immunocompromised subjects (14%) in a cross-sectional study and provoked diarrhoeal illness. It was found that isosporiasis may be a seasonal infection (4). In another study it was reported that a 60-year-old

immunocompetent patient with chronic biliary isosporiasis failed to respond to orally administered treatment with nitazoxanide, a 5-nitrothiazole benzamide compound. Severe malabsorption was considered responsible for treatment failure with nitazoxanide. Administration of intravenously cotrimoxazole stopped the shedding of *I. belli* oocysts in bile within 5 days, excluding initial suspected resistance to cotrimoxazole (2). Most transplant recipients suffer from some type of gastrointestinal complication. There are a large number of infectious agents that causes diarrhoea, including variety of opportunistic organisms and parasitic agents such as *I. belli* (6).

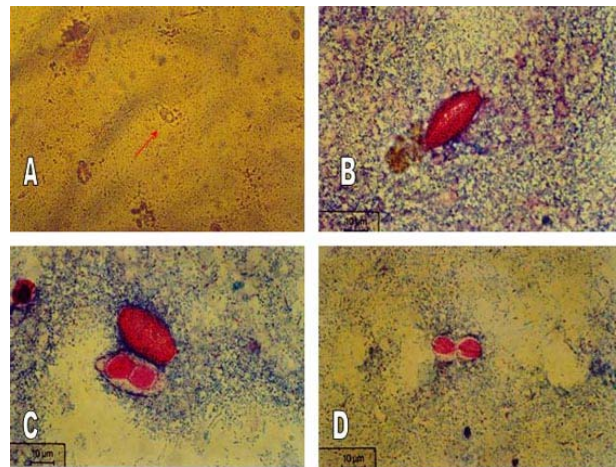


Figure 1. *Isospora belli* oocysts in stool smear preparations. **A:** Iodine staining (x400); **B-D:** acid-fast staining *I. belli* oocyst (sporulation stage) (x1000)

Although the distribution of *I. belli* is worldwide (3, 7), it is rarely reported from most countries including Turkey. There were five cases of isosporiasis between 1994 and 2006, one of them was renal transplant patient (12), one of them was congenital diserythropoiesis patient (9), two of them were AIDS patients (3, 11), and last one was bronchoalveolar carcinoma (7). To our knowledge this is the second reported case of *I. belli* infection of a renal transplant recipient in Turkey. In the detection of coccidian parasites acid-fast staining technique is recommended besides routine ova and parasite (O&P) concentration methods. The detection of human intestinal coccidian parasites depends on the through examination of concentrated stool specimens, but besides O&P examination, acid-fast stain is suggested for *Isospora* oocysts (5).

In conclusion, isosporiasis should be suspected in immunocompromised patients, transplant patients and those infected with human immunodeficiency virus (HIV), with chronic persistent diarrhoea, abdominal cramps, and weight loss. However, symptoms are non-specific and stool samples should be interpreted cautiously for the possible existence of O&P especially for *I. belli* oocysts. Also, TMP-SMX could be the drug of choice in patients with chronic stubborn diarrhoea suffering from isosporiasis.

REFERENCES

1. **Bialek R, Binder N, Dietz K, Knobloch J, Zelck UE**, 2002. Comparison of autofluorescence and iodine staining for detection of *Isoospora belli* in feces. *Am J Trop Med Hyg*, 67: 304-305.
2. **Bialek R, Overkamp D, Rettig I, Knobloch J**, 2001. Case report: Nitazoxanide treatment failure in chronic isosporiasis. *Am J Trop Med Hyg*, 65: 94-95.
3. **Büyükbaba-Boral O, Uysal H, Alan S, Büget E, Nazlıcan Ö**, 2005. AIDS'li bir hastada belirlenen izosporiyaz olgusu. *Türk Mikrobiyol Cem Derg*, 35: 45-49.
4. **Certad G, Arenas-Pinto A, Pocaterra L, Ferrara G, Castro J, Bello A, Nunez L**, 2003. Isosporiasis in Venezuelan adults infected with human immunodeficiency virus: clinical characterization. *Am J Trop Med Hyg*, 69: 217-222.
5. **Garcia LS, Bruckner DA**. Diagnostic Medical Parasitology, Washington, DC: ASM Press, 1997.
6. **Helderman JH**, 2001. Prophylaxis and treatment of gastrointestinal complications following transplantation. *Clin Transplantation*, 15 (Suppl 4): 29-35.
7. **Kılıç H, Sümerkan B, Koç AN, Ünal A, Sehmen E**, 1995. Bronkoalveolar karsinomlu bir olguda *Isoospora belli*. *Mikrobiyol Bült*, 29: 410-413.
8. **Lindsay DS, Dubey JP, Blagburn BL**, 1997. Biology of *Isoospora* spp. from humans, nonhuman primates, and domestic animals. *Clin Microbiol Rev*, 10: 19-34.
9. **Özbel Y, Özensoy S, Yurdağül C, Özbilgin A**, 1994. Bir *Isoospora belli* enfeksiyonu olgusu. *Enfeksiyon Derg*, 8:197-201.
10. **Soave R, Johnson WD**, 1988. *Cryptosporidium* and *Isoospora belli* infections. *J Infect Dis*, 157: 225-229.
11. **Türk M, Kaptan F, Ayaydın A, Ural S, Türkler M**, 2003. Kronik ishali olan AIDS hastasında saptanan ve TMP-SMX dirençli olan Primetamin ile tedavi edilen *Isoospora belli* olgusu. 13. Ulusal Parazitoloji Kongresi, 8-12 Eylül 2003, Konya.
12. **Yazar, Tokgöz B, Yaman O, Şahin İ**, 2006. Renal transplantlı bir hastada *Isoospora belli* enfeksiyonu. *Türk Parazitol Derg*, 30: 22-24.