

A New Species of *Henneguya*, a Gill Parasite of a Freshwater Fish *Anabas testudineus* (Bloch) Affected with Ulcerative Disease Syndrome from Manipur, India

Th. HEMANAND¹, N. Mohilal MEITEI¹, Probir K. BANDYOPADHYAY², Amlan K. MITRA²

¹Department of Life Sciences, Manipur University, Canchipur, Imphal 3, India

²Parasitology Laboratory, Department of Zoology, University of Kalyani, Kalyani, West Bengal, India

SUMMARY: A new species of *Henneguya* parasitizing tissues affected by the ulcerative disease syndrome of a freshwater fish *Anabas testudineus* (Bloch) from Khiodum and Pumlen lakes of Manipur state is described. Of the fishes examined 75% were found to be infested with this myxozoan parasite. Mature spores of the new species are elongated, biconvex, and oval with bluntly rounded anterior end and gradually tapering posterior end with a caudal prolongation, measuring 12.6-15.4 (14.0± 1.1) µm in length. Length of the caudal prolongation is 11.2-12.6 (11.7± 0.6) µm. The width of the spores is 5.6-7.0 (6.3± 0.5) µm. The length of the polar capsules is 5.6-6.3 (5.5± 0.3) µm.

Key words: Myxozoa, *Henneguya manipurensis* sp. nov., freshwater fish, *Anabas testudineus*, Manipur

Hindistan Manipur'da Ülseratif Hastalık Sendromundan Etkilenen Tatlısu Balığı *Anabas testudineus*'un Solungaç Paraziti, *Henneguya*'nın Yeni Bir Türü

ÖZET: Bu çalışmada, Manipur Eyaleti'nin Khiodum ve Pumlen göllerinde bulunan ve ülseratif hastalık sendromundan etkilenmiş tatlısu balığı *Anabas testudineus*'un parazitli dokularında *Henneguya*'nın yeni bir türü tanımlanmıştır. İncelenen balıkların %75'inin bu myxozoan parazitte enfeste olduğu görülmüştür. Yeni türün olgunlaşmış sporları, uzun, bikonkav, ön ucu belirgin şekilde yuvarlağımsı oval ve arka ucu gittikçe sivrilen 12.6-15.4 (14.0± 1.1) µm ölçülen bir kaudal uzantılıdır. Kaudal çıkıntının uzunluğu 11.2-12.6 (11.7± 0.6) µm'dir. Sporların genişliği 5.6-7.0 (6.3± 0.5) µm'dir. Polar kapsülün uzunluğu 5.6-6.3 (5.5± 0.3) µm'dur.

Anahtar Sözcükler: Myxozoa, *Henneguya manipurensis* sp. nov., tatlısu balığı, *Anabas testudineus*, Manipur, Hindistan

INTRODUCTION

The genus *Henneguya* was described by Thélohan (15). The importance of this genus as a pathogen of freshwater fish has been described by several authors (4-7, 11-13).

In order to investigate the myxozoan parasites associated with the fishes affected by ulcerative disease syndrome, an ichthyoparasitological survey was carried out in two lakes, Khiodum and Pumlen of Manipur, India. During the study several species of *Henneguya* Thelohan, 1892 were encountered from the ulcerated muscle tissue of *Anabas testudineu*. The

present paper deals with taxonomy, systematic of *H. manipurensis* sp. nov.

MATERIALS AND METHODS

24 specimens of *Anabas testudineus* affected with Ulcerative Disease Syndrome were collected from Khoidum pat and Pumlen pat lakes (Latitude 24.4 N, longitude 98.5 S) and examined for the presence of myxozoans. Since any sign for the presence of cyst was not seen, smears were made from the infected parts of the body and observed under Phase Contrast microscope as fresh preparation. As the slides were found to be positive for myxozoan parasites, the infected parts of the fishes were flushed with distilled water. The flushed materials were centrifuged at 1000 rpm for 5 minutes and the sediment was collected by discarding the supernatant. Dry smears were made from the sediment for permanent preparation. Some of the slides were treated with Indian ink and Lugols' Iodine for

Makale türü/Article type: **Araştırma/Orijinal Research**

Geliş tarihi/Submission date: 10 Eylül/10 September 2007

Düzeltilme tarihi/Revision date: -03 Kasım/03 November 2007

Kabul tarihi/Accepted date: 03 Kasım/03 November 2007

Yazışma /Corresponding Author: Probir K. Bandyopadhyay

Tel: (+90) (332) 582 04 32 Fax: -

E-mail: prabir0432@hotmail.com

observation of the presence of mucus envelope and iodophilous vacuole while others were fixed in methanol, stained with Giemsa solution. The slides were then washed with buffer solution, dried and mounted in DPX. Measurements of 20 spores were taken by using calibrated Olympus microscope. Illustrative drawings were made with the aid of camera lucida and photomicrographs were taken with the help of "OLYMPUS" made camera fitted to a computer. The descriptions of these three myxosporeans are in accordance with the guidelines of Lom and Arthur (9) and Lom and Dyková (10).

RESULTS

Henneguya manipurensis sp. nov. (Figs. 1-5, Tables 1-2).

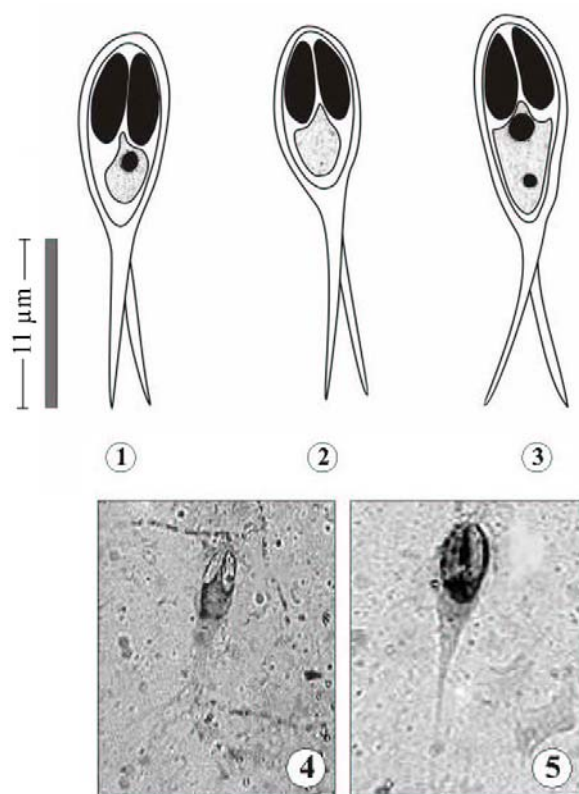
Mature spores are elongated, biconvex, and oval with bluntly rounded anterior end and gradually tapering posterior end with a caudal prolongation. The length of the spore without prolongation is 12.6 – 15.4 μm (14 ± 1.1) and breadth of the spore is 5.6 – 7.0 μm (6.3 ± 0.5). Length of the caudal prolongation is 11.2 – 12.6 μm (11.76 ± 0.68). The caudal prolongation bifurcated at the tip. The total length of the spore is 23.8 – 28.0 μm (25 ± 1.5).

There are two polar capsules which are equal in length. It looks pyriform in shape and is bluntly pointed at both end. The length of the polar capsule is 5.6 – 6.3 μm (5.8 ± 0.3) and breadth is 2.1 – 2.8 μm (2.3 ± 0.3), occupying nearly half of the spore body.

The extra capsular region is occupied with granular sporoplasm. The sporoplasm rises up slightly between the two polar capsules. The size of the sporoplasm varies and contains 1 to 2 small sporoplasmic nuclei. In some spore there is no sporoplasmic nucleus. Iodophilous vacuole and mucus envelop are absent (Table 1).

Taxonomic Summary

Type species	: <i>Henneguya manipurensis</i> sp. nov.
Host	: <i>Anabas testudineus</i> (Bloch)
Site of infection	: Body tissue (ulcerated part)
Type locality	: Khoidum pat and Pumlen pat Lakes (Latitude 24.4 N, longitude 98.5 S)
Prevalence	: 18 out of 24 hosts examined (75 %)
Type specimen	: Two holotype slides HP1/2006, HP2/12 and other paratype slides are deposited at parasitology section, Life Sciences Dept. Manipur University
Etymology	: The species name is given after the type locality Manipur State



Figures. 1-3. Camera lucida drawings of spores of *Henneguya manipurensis* sp. nov.

1. Mature spore stained with Giemsa showing presence of only one sporoplasmic nucleus;
2. Mature spore stained with Giemsa showing absence of sporoplasmic nucleus;
3. Mature spore stained with Giemsa showing two sporoplasmic nuclei;
- 4-5. Photomicrographs of spores of *H. manipurensis* sp. nov. stained with Giemsa.

Table 1. Statistical analysis of measurement and ratio of *Henneguya manipurensis* sp. nov. (measurements are in micrometer)

Characters	Range	Mean	Standard Deviation
Length of the spore	12.6 – 15.4	14.0	1.1
Length of caudal prolongation	11.2 – 12.6	11.7	0.6
Length of spore with caudal prolongation	23.8 – 28.0	25.6	1.5
Breadth of the spore	5.6 – 7.0	6.3	0.5
Length of polar capsule	5.6 – 6.3	5.8	0.3
Breadth of polar capsule	2.1 – 2.8	2.3	0.3

DISCUSSION

The present myxozoa with two polar capsules at the anterior end and with caudal prolongation bifurcated at the tip belong to the genus *Henneguya* Thelohan, 1892.

The present species of *Henneguya* resembles in size/and or in shape *Henneguya chydadea* Barassa *et. al.*, 2003 (3) reported

Table 2. Comparative statements of *Henneguya manipurensis* sp. nov. with other closely related species of *Henneguya*. (measurements are in micrometer)

Characters	<i>H. chydadea</i>	<i>H. visceralis</i>	<i>H. lesteri</i>	<i>H. wenyoni</i>	<i>H. adherens</i>	<i>H. malbarica</i>	<i>Henneguya manipurensis</i> sp. nov.
Length of the spore	8.8 – 11.2	11 – 12	8 – 10.4 (9.1)	11 – 12	12.4	11.8 – 13.1 (12.6)	12.6 – 15.4 (14 ± 1.7)
Length of caudal prolongation	8.0 – 9.6	11 – 12	11.2 – 16 (12.6)	8 – 12	20.5	16.2 – 18.9 (17.1)	12.2 – 12.6 (11.76 ± 0.68)
Length of the spore with caudal prolongation	17.6 – 20.0	22 – 24	19 – 26.4	19 – 24	32.3	28 – 32	23.8 – 28 (25.67 ± 0.68)
Breadth of the spore	3.2 – 5.6	5 – 5.6	4 – 5 (4.7)	4.5 – 6.0	5.8	4.4	5.6 – 7 (6.3 ± 0.54)
Length of polar capsule	3.2 – 4.4	6.5 – 8	3.2 – 3.5	3.4 – 5.0	3.1	3.0 – 4.3 (3.7)	5.6 – 6.3 (5.88 ± 0.34)
Breadth of polar capsule	1.2 – 1.6	2	1.3 – 1.6 (1.6)	1.5	1.2	1.6 – 2.2 (1.8)	2.1 – 2.8 (2.31 ± 0.32)
Site of infection	Gill	Kidney, Liver, Hearth, Mesentery	Gill	Gill	-	Gill	Infected part of the muscle tissue
Host	<i>Astyanax altiparanae</i>	<i>Electrophorus electricus</i>	<i>Sillago analis</i>	<i>Tetragonopterus</i> sp	<i>Acestrorhynchus falcatus</i>	<i>Hoplias malabaricus</i>	<i>Anabas testudineus</i>
References	(3)	(6)	(5)	(14)	(1)	(2)	Present paper

from gills of *Astyanax altiparanae*; *H. visceralis* Jakowska and Nigrelli, 1953 (6) reported from kidney, liver, heart and mesentery of *Electrophorus electricus* of New York; *H. lesteri* Hallett *et al.*, 2001 (5) reported from gill of *Sillago analis* of Australia; *H. wenyoni* Pinto, 1928 (14) reported from gill of *Tetragonopterus* sp; *H. adherens* Azevedo *et al.*, 1995 (1) reported from Amazonian fish *Acestrorhynchus falcatus* and *H. malbarica* Azevedo *et al.*, 1996 (2) reported from gill of Amazonian fish *Hoplias malabaricus* (Table 2).

When the species under consideration is compared with *H. chydadea* (Barassa *et al.* (3) it resembles closely morphologically although the new species is much larger in size (Table 2). Moreover, the site of infection is different. *H. chydadea* has been reported from the gill lamellae of *Astyanax altiparanae*, although *H. manipurensis* has been reported from the infected part of the muscle tissue of *Anabas testudineus*.

H. manipurensis sp. nov. differs significantly from *H. visceralis* in the shape of the spore. *H. visceralis* is different from the new species in having curved spore body.

The new species shows marked differences in shape and size of the spore body when compared with *H. lesteri* and *H. wenyoni*. The new species shows greater ratios of LS, LCP, BS and LPC when compared with the same parameters of *H. lesteri* and *H. wenyoni*. *H. lesteri* and *H. wenyoni* have smaller spore body and shorter polar capsule than the species obtained from *Anabas testudineus*.

H. manipurensis when compared with *H. adherens* and *H. malbarica* shows great variation in size of the LCP, BS, LCP (Table 2). *H. adherens* and *H. malbarica* have longer caudal prolongations, narrower spore body, shorter polar capsule and breadth of polar capsules than the species under discussion.

Considering the above differences with the related species described from different areas, the present species is regarded as new to science and named as *Henneguya manipurensis* sp. nov.

Abbreviations: Length of the Spore (LS), Length of Caudal Prolongation (LCP), Breadth of the Spore (BS), Length of Polar Capsule (LPC)

ACKNOWLEDGEMENTS

The authors are grateful to Prof. G. A. Shantibala Devi (Head of Life Sciences Department, Manipur University) for providing necessary laboratory facilities and the first author acknowledges the financial assistance in the form Departmental Fellowship of Manipur University. Prof. W. Vishwanath Singh of the Department Life Sciences, Manipur University is also gratefully acknowledged for kindly identifying and taking photograph of the host species.

KAYNAKLAR

1. Azevedo C, Matos E, 1995. *Henneguya adherens* n.sp. (Myxozoa, Myxosporea), parasite of the Amazonian fish. *Acestrorhynchus falcatus*. *J Euk Microbiol*, 42: 515 – 518.
2. Azevedo C, Matos E, 1996. *Henneguya malbarica* sp. nov. (Myxozoa, Myxobolidae) in the Amazonian fish *Hoplias malabaricus*. *Parasitol Res*, 82: 222 – 224.

3. **Barassa B, Cordeiro NS, Arana S**, 2003. A new species of *Henneguya*, a gill parasite of *Astyanax altiparanae* (Pisces: Characidae) from Brazil, with comment on Histopathology and Seasonality. *Mem Inst Oswaldo Cruz Rio de Janeiro*, 98(6): 761 – 765.
4. **Dyková I, Lom J**, 1978. Histopathological changes in fish gills infected with myxosporidian parasites of the genus *Henneguya*. *J Fish Biol*, 12: 197-202.
5. **Hallett SL, Diamant A**, 2001. Ultrastructure and small – subunit ribosomal DNA sequence of *Henneguya lesteri* n. sp. (Myxosporidia), a parasite of sand whiting *Sillago analis* (Sillaginidae) from the coast of Queensland, Australia. *Dis Aquat Org.*, 46: 197 – 212.
6. **Jakowska S, Nigrelli RF** 1953. The pathology of Myxosporidiosis in the Electric Eel. *Electrophorus electricus* (Linnaeus), caused by *Henneguya visceralis* and *H. electrica* spp. nov. *Zoologica*, 38(16): 183 – 191.
7. **Kalavati C, Narasimhamurti CC** 1985. Histopathological changes in the gills of *Channa punctatus* BL. infected with *Henneguya waltirensis*. *Arch Protistenk*, 129: 199-202.
8. **Lom J, Arthur JR**, 1989. A guideline for the preparation of species descriptions in Myxosporidia. *J Fish Dis.*, 12: 151 – 156.
9. **Lom J, Dyková I**, 1992. *Protozoan Parasites of Fishes*. Development in Aquaculture and Fisheries Science, 26. Elsevier, Amsterdam
10. **Lom J, Dykova I**, 1995. In P. T. K. Woo (Ed.), *Fish Diseases and Disorders – Protozoan and Metazoan Infection*. Vol. 1. CAB International. Wallingford pp. 97 – 147.
11. **Martins ML, Souza VN**, 1997. *Henneguya piaractus* n. sp. (Myxozoa: Myxobolidae), a gill parasite of *Piaractus mesopotamicus* Holmberg, 1887 (Osteichthyes: Characidae), in Brazil. *Rev Bras Biol*, 57: 239-245.
12. **Martins ML, Souza VN, Moraes JRE, Moraes FR, Costa AJ**, 1999. Comparative evaluation of the susceptibility of cultivated fishes to the natural infection with myxosporidian parasites and tissue changes in the host. *Rev Bras Biol*, 59: 263-269.
13. **Pinto C**, 1928. *Henneguya wenyoni* n. sp. myxosporidii parasite des branchies des poissons d'eau douce du Brésil. *Comptes Rendus Soc Biol Paris*, 98: 1580.
14. **Thelohan P**, 1892. Observation sur les myxosporidies et essai de classification de ces organismes. *Bull Soc Philom*, 4: 165 – 178.