



Villous Adenoma with High-Grade Dysplasia of the Appendix: A Case Report

Appendiks Kaynaklı Yüksek Derecede Displazi İçeren Villöz Adenom: Olgu Sunumu

© Birgül Tok¹, © Duygu Demiriz Gülmez², © Mehmet Gülmez³

¹Akçaabat Haçkalı Baba State Hospital, Clinic of Pathology, Trabzon, Türkiye

²Op. Dr. Ergun Özdemir Görele State Hospital, Clinic of Anesthesia and Reanimation, Giresun, Turkey

³Op. Dr. Ergun Özdemir Görele State Hospital, Clinic of General Surgery, Giresun, Turkey

ABSTRACT

Villous adenomas of the appendix are rare and usually diagnosed incidentally after appendectomy due to acute appendicitis. Appendicular villous adenomas have potential risk for progression to invasive carcinoma, just as other adenomas located in colon and rectum. Appendectomy can be considered sufficient treatment if the tumor measures less than 2 cm, there is no mesoappendicular or nodal spread, and the resection margins are healthy. We present a patient diagnosed with villous adenoma with high-grade dysplasia detected in histopathological examination of appendectomy specimen.

Keywords: Appendix, villous adenoma, dysplasia

ÖZ

Appendiks kaynaklı villöz adenomlar oldukça nadirdir ve genellikle akut apandisit nedeniyle yapılan appendektomi sonrasında rastlantısal olarak tespit edilmektedir. Appendiks kaynaklı villöz adenomların kalın barsağın diğer villöz adenomları gibi invaziv karsinoma ilerleme riski mevcuttur. Tümör boyutu 2 cm'den küçük, mezoappendiks veya lenf nodu yayılımının olmadığı ve temiz cerrahi sınır sağlandığında tedavi için appendektomi yeterlidir. Biz de akut apandisit ön tanısıyla opere edilen ve histopatolojik inceleme sonucunda appendiks kaynaklı yüksek derecede displazi içeren villöz adenom saptanan hastayı sunmayı amaçladık.

Anahtar Kelimeler: Appendiks, villöz adenom, displazi

Introduction

Adenomas of the appendix account for approximately 0.02-0.14% of appendiceal lesions.¹ They are usually seen in individuals 60-80 years of age. Although most appendiceal adenomas are detected incidentally in appendectomy specimens, cases associated with intussusception, appendiceal perforation, and rectal hemorrhage have also been described in case reports.^{2,3} Here, we present a case of villous adenoma with high-grade dysplasia detected in histopathological examination following appendectomy due to acute appendicitis.

Case Report

A 41-year-old male patient was admitted to the emergency department of our hospital with abdominal pain, nausea, and vomiting. On physical examination his blood pressure was 130/70 mmHg, temperature 37.1 °C, and heart rate 98/min. Abdominal examination revealed tenderness and rebound in the lower right quadrant. Laboratory test results showed his leukocyte count was $12.5 \times 10^3/\mu\text{L}$ (95% neutrophils). Other biochemical markers were normal. The appendix was found to be noncompressible and dilated on ultrasonography and the findings were reported as consistent with acute appendicitis. The patient



Address for Correspondence/Yazışma Adresi: Mehmet Gülmez MD,

Op. Dr. Ergun Özdemir Görele State Hospital, Clinic of General Surgery, Giresun, Turkey

Phone: +90 532 656 66 81 E-mail: mehmetgulmez86@hotmail.com ORCID ID: orcid.org/0000-0001-8803-6160

Received/Geliş Tarihi: 27.05.2018 Accepted/Kabul Tarihi: 30.05.2018

was admitted for surgery with a preliminary diagnosis of acute appendicitis and underwent appendectomy. The patient was discharged on the first postoperative day with no complications. On histopathological examination of the specimen, the appendectomy material was 5 cm long, 0.9 cm in diameter with capillary vessels on the surface and areas of adipose tissue. There was sporadic shedding of the lumen epithelium, and a structurally complex focus of high-grade dysplasia characterized by an area of enlarged nuclei, pleomorphic appearance, and increased mitotic activity was noted (Figure 1). This area was limited to the mucosa, with no sign of wall invasion. The muscularis mucosa was intact (Figure 2). The patient provided consent for the publication of this case report.

Discussion

Adenomas of the appendix account for approximately 0.02-0.14% of appendiceal lesions.¹ They usually manifest clinically as acute appendicitis and most are diagnosed during histopathological examination of the appendectomy specimen. In addition, several cases of intussusception, appendiceal perforation, rectal hemorrhage, or incidental detection during colonoscopy have also been reported.^{2,3} Colon and appendiceal adenomas are dysplastic polypoid

lesions and are divided into three groups: tubular, villous, and tubulovillous. The potential for malignant conversion is associated with tumor size (<5% for those smaller than 1 cm; >50% for those larger than 2 cm) and pathological type (5% for tubular adenoma, 20% for tubulovillous adenoma, and 40% for villous adenoma).^{4,5} Villous adenomas usually develop in the rectum and sigmoid colon.⁶ The incidence of primary appendiceal villous adenoma was determined as approximately 0.006% in appendectomy series.³ Only 71 cases of villous adenoma have been reported in the literature.⁷ Appendiceal villous adenomas pose a risk of progression to invasive carcinomas such as other villous adenomas of the large bowel.² Appendectomy is sufficient when the tumor is less than 2 cm in size, mesoappendiceal and lymph node involvement is absent, and a clean surgical margin is achieved. Right hemicolectomy and lymph node dissection are recommended in cases with tumors larger than 2 cm, mesoappendiceal invasion, lymph node involvement, positive surgical margin, and lymphatic or vascular embolism.⁸ The follow-up approach for appendiceal adenomas is similar to those of the colon and rectum.⁹ Due to the relationship between adenomas of the appendix and colon adenocarcinoma, colonoscopy is recommended for patients with incidentally detected appendiceal tumors.¹⁰

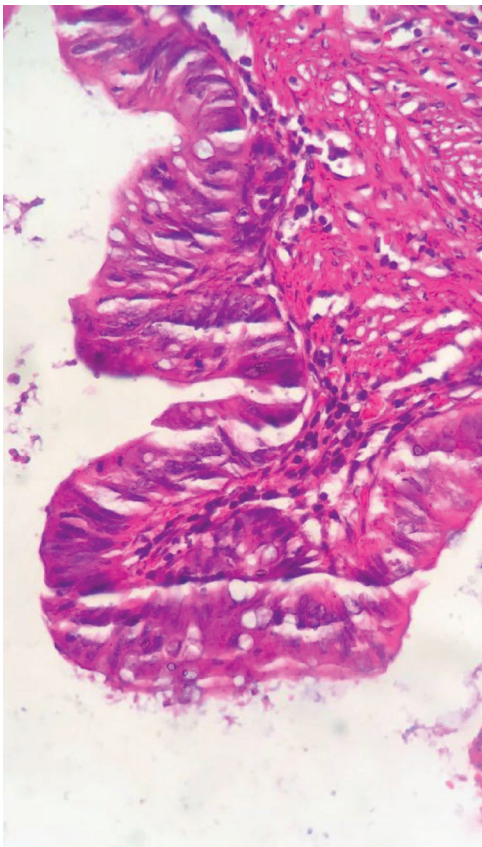


Figure 1. Villous adenoma with high-grade dysplasia

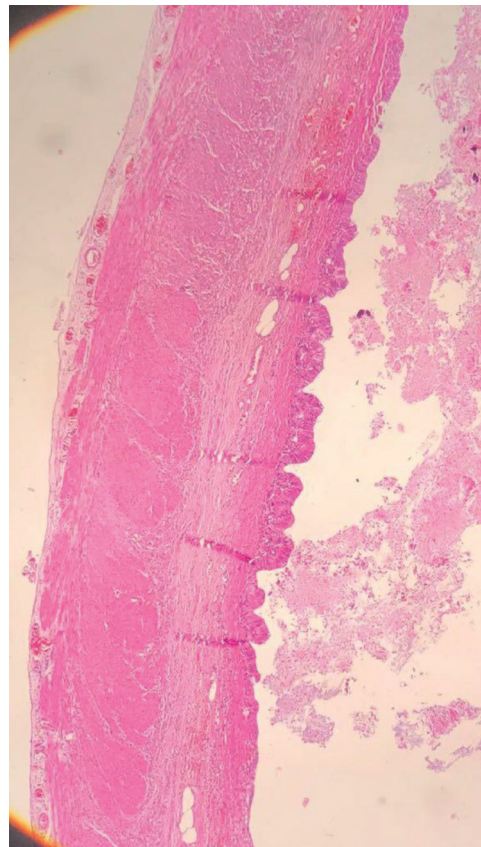


Figure 2. Villous adenoma with high-grade dysplasia

Ethics

Informed Consent: Informed consent was taken from the patient.

Peer-review: Externally peer-reviewed.

Authorship Contributions

Surgical and Medical Practices: B.T., D.D.G., M.G., Concept: B.T., D.D.G., Design: B.T., D.D.G., Data Collection or Procceeding: B.T., M.G., Analysis or Interpretation: M.G., Literature Search: B.T., M.G., Writing: M.G.

Conflict of Interest: No conflict of interest was declared by the authors.

Financial Disclosure: The authors declared that this study received no financial support.

References

1. Wolff M, Ahmed N. Epithelial neoplasms of the vermiform appendix II (exclusive of carcinoid). Cystadenomas, papillary adenomas, and adenomatous polyps of the appendix. *Cancer* 1976;37:2511-2522.
2. Ohno M, Nakamura T, Hori H, Tabuchi Y, Kuroda Y. Appendiceal intussusception induced by tubulovillous adenoma with carcinoma in situ: report of a case. *Surg Today* 2000;30:441-444.
3. Stroppa I, Lionetti R, Andrei F, Cocco A, Farinon AM, Pallone F. Large villous adenoma of the appendix: a case treated with sequential endoscopic-minimal surgical technique. *Dig Liver Dis* 2009;41:451-452.
4. Muto T, Bussey HJ, Morson BC. The evolution of cancer of the colon and rectum. *Cancer* 1975;36:2251-2270.
5. Fenoglio CM, Kaye GI, Lane N. Distribution of human colonic lymphatics in normal, hyperplastic, and adenomatous tissue. Its relationship to metastasis from small carcinomas in pedunculated adenomas, with two case reports. *Gastroenterology* 1973;64:51-66.
6. Hanley PH, Hines MO, Ray JE, McPherson F, Hibbert WA. Villous tumors: experience with 163 patients. *South Med J* 1962;55:233-238.
7. Eakin J, Ruiz OR, Fannin E. Villous adenoma of the appendix: management recommendations. *Am Surg* 2013;79:49-51.
8. Fernández Blanco CM, Fraguera JA, Gullías A, Sánchez Blas M, Freijoso C. Villous adenoma of the appendix. Diagnostic and therapeutic approach. *Rev Esp Enferm Dig* 2002;94:537-543.
9. Hata K, Tanaka N, Nomura Y, Wada I, Nagawa H. Early appendiceal adenocarcinoma. A review of the literature with special reference to optimal surgical procedures. *J Gastroenterol* 2002;37:210-214.
10. Chen YG, Chang HM, Chen YL, Cheng YC, Hsu CH. Perforated acute appendicitis resulting from appendiceal villous adenoma presenting with small bowel obstruction: a case report. *BMC Gastroenterol* 2011;11:35.