

Rectosigmoid Tumor Causing Rectal Prolapse: Case Report

Rektal Prolapsusa Neden Olan Rektosigmoid Tümörü: Olgu Sunumu

Barlas Sülü, Turgut Anuk, Tülay Diken Allahverdi, Kenan Binnetoğlu, Musa Sinan Eren, Mahmut Can Yağmurdur

Kafkas University Faculty of Medicine, Department of General Surgery, Kars, Turkey

ABSTRACT

Rectal prolapse is believed to develop secondary to anatomical defects. Rectosigmoid tumors are rare causes of this condition. This must be kept in mind in patients with prolapse; colonoscopic examination is recommended and biopsy should be performed when necessary. In this case report, we present an elderly patient with rectal prolapse. The mass that precipitated the prolapse was biopsied and identified as adenocarcinoma. The cancer was treated and patient was discharged.

Keywords: Rectal prolapse, colonoscopy, sigmoid cancer

ÖZ

Rektal prolapsusun anatomik bozukluk sonucu olduğu kabul edilmektedir. Rektosigmoid bölgenin kanserleri de bu duruma yol açan nadir faktörlerdendir. Prolapsuslu hastalarda bu faktör göz önünde bulundurulmalı ve kolonoskopik inceleme yapılarak gerekirse biyopsi alınmalıdır. Biz de bu olgu sunumunda rektal prolapsuslu yaşlı bir hastayı sunduk. Hastanın prolabe olan sigmoid mukozadaki kitleden biyopsi alındı. Biyopsi sonucu adenokanser saptandı. Tümöre yönelik cerrahi tedavi uygulanan hasta iyileşerek taburcu edildi.

Anahtar Kelimeler: Rektal prolapsus, kolonoskopi, sigmoid kanser

Introduction

Rectal prolapse is the protrusion of a full-thickness section of rectal through the anus. It can also be described as an intussusception of the rectum and rectosigmoid.¹ Its actual prevalence in the population is unknown. Among younger patients, rectal prolapse is more common in males, while in older patients it is more common among women.² Many risk factors have been identified in its etiology, but it is difficult to determine which actually causes the condition. The currently accepted theory is that these risk factors create an inclination toward anatomic defects which cause rectal prolapse. Adenocarcinoma of the rectum and sigmoid colon are also among the important but rare precipitating factors of rectal prolapse.

Case Report

A 71-year-old male patient presented to the outpatient clinic complaining that his intestines were protruding from his anal canal. The patient reported that the problem had started one month earlier and that on several occasions the

protruding intestine had spontaneously retracted. The patient was admitted to the clinic and physical examination revealed an approximately 10 cm section of intestine was protruding through the anus. Upon further examination it was determined to be a full-thickness mucosal prolapse, with three portions of the intestine showing tissue alterations and the appearance of a mass (Figure 1). The patient underwent a colonoscopy in sterile conditions and a biopsy was taken. Although no pathologic findings were observed in the colonoscopy, the pathology report from the mass biopsy indicated adenocarcinoma (Figure 2). Due to the patient's age and overall condition, a perineal approach was initially planned, but we instead performed an anterior procedure with sigmoid colon resection with end-to-end anastomosis (Figure 3). On the 5th postoperative day, the patient was discharged with full recovery.

Discussion

In a healthy individual, the intra-abdominal pressure increases and levator muscle contraction is inhibited during



Address for Correspondence/Yazışma Adresi: Barlas Sülü MD
Kafkas University Faculty of Medicine, Department of General Surgery, Kars, Turkey
Phone: +90 506 536 35 68 E-mail: barlas.sulu36@gmail.com
Received/Geliş Tarihi: 28.08.2016 Accepted/Kabul Tarihi: 22.10.2016

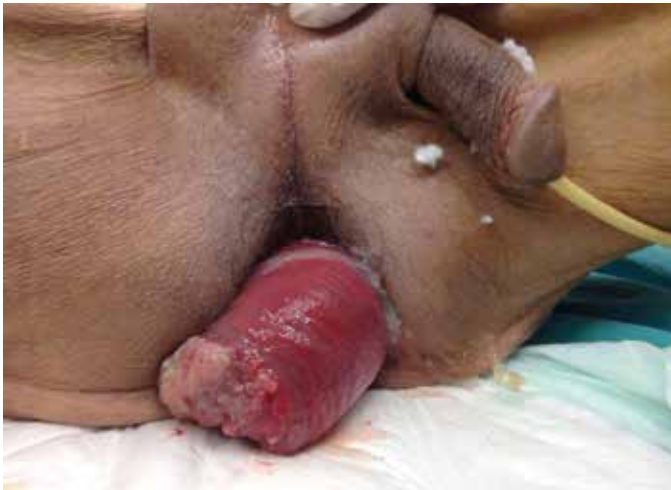

Figure 1. Preoperative appearance of the prolapsed portion of the bowel

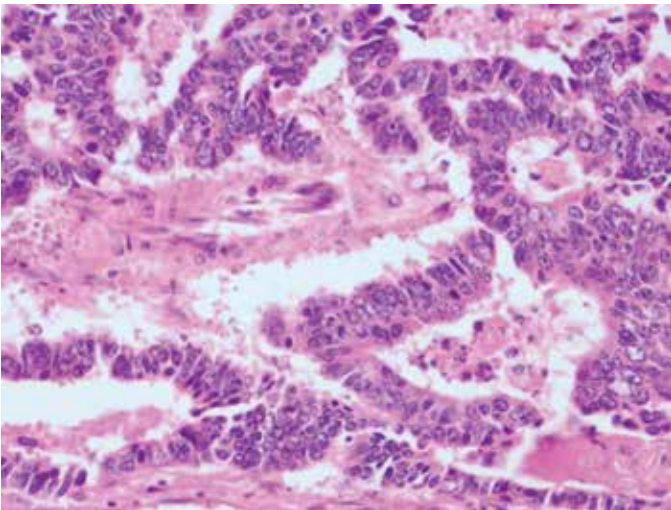


Figure 2. Histopathologic appearance of the biopsy obtained from the mass located at the end of the prolapsed bowel

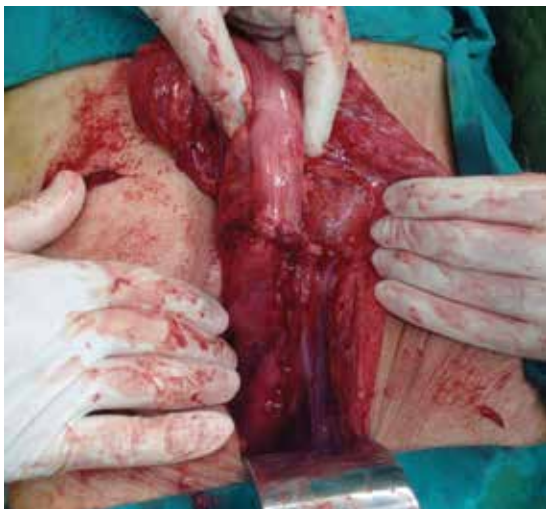

Figure 3. Postoperative appearance

defecation. The puborectal and external sphincter muscles also relax, allowing the pelvic floor to descend and the anorectal angle to straighten. A problem with one or more of these structures causes incontinence and prolapse.² The condition was first described on papyrus approximately 3500 years ago, but its etiology is still debated today. Despite the many identified etiological risk factors, there are different theories regarding its etiology. Some authors have claimed that anatomic factors and intussusception lead to the condition, while another proposed that prolapse is a sliding type of hernia.^{2,3} However, the most widely accepted theory is that rectal prolapse is caused by an anatomic defect resulting from various precipitating factors.⁴

Prolapse is more prevalent in women and older age, and major risk factors include a deep pouch of Douglas, long rectum and sigmoid colon, weak pelvic floor and/or anal sphincter muscles, loss of fixation of the rectum to the sacrum, and any trauma or surgery that compromised the anatomic integrity of the region.³ Presence of a long rectosigmoid colon was the most common risk factor according to a study conducted in the Cleveland Clinic.⁴

Adenocarcinoma of the rectum or sigmoid colon is an important but rare risk factor for rectal prolapse. Only a limited number of reports document sigmoid cancer as a cause for prolapse, as in our case.¹ Rectosigmoid carcinoma was not observed in any of the 44 rectal prolapse patients studied by Sun et al.⁴, while another study revealed the prevalence of rectosigmoid carcinoma was 5.7%.⁵ In adenocarcinomas of this region, the mass forms a leading point from which an intussusception develops. With constipation and straining, the intussusception progresses into prolapse.⁶ An important consideration is that degenerative changes occurring in the mucosa due to external exposure must be differentiated from tumoral masses. Furthermore, patients with rectal prolapse were reported to have a 4.2-fold higher risk of developing colorectal cancer compared to a control group.⁵ Therefore, the initial approach to patients with prolapse should include a colonoscopic examination and conducting a biopsy in sterile conditions of any mucosal changes observed on the prolapsed segment, as in our case. The results of that biopsy will determine the surgical approach. In our case, we biopsied the part of the prolapsed bowel showing mucosal changes. Upon receiving the biopsy report of adenocarcinoma, we decided against the original plan of perineal approach in favor of using an anterior approach and performing sigmoid colon resection with end-to-end anastomosis.

In summary, cancers of the rectum and sigmoid areas should be kept in mind as possible causes of prolapse. For this reason, colonoscopic examination should be performed prior to planning treatment. Any suspicious tissue observed in this area should be biopsied and the treatment plan should be based on the histopathologic results.

Ethics

Informed Consent: It was taken.

Peer-review: External and Internal peer-reviewed.

Authorship Contributions

Surgical and Medical Practices: Barlas Sülü, Mahmut Can Yağmurdur, Musa Sinan Eren, Concept: Barlas Sülü, Turgut Anuk, Tülay Diken Allahverdi, Kenan Binnetoğlu, Mahmut Can Yağmurdur, Design: Barlas Sülü, Data Collection or Processing: Barlas Sülü, Mahmut Can Yağmurdur, Analysis or Interpretation: Barlas Sülü, Literature Search: Barlas Sülü, Writing: Barlas Sülü.

Conflict of Interest: No conflict of interest was declared by the authors.

Financial Disclosure: The authors declared that this study received no financial support.

References

1. Yamazaki T, Sakai Y, Sekine Y, Nihei K, Hatakeyama K. Sigmoid colon cancer presenting as complete rectal prolapse: report of a case. *Surg Today* 1999;29:266-267.
2. Yoon SG. Rectal prolapse: review according to the personal experience. *J Korean Soc Coloproctol* 2011;27:107-113.
3. Çalışkan C, Korkut AM, Fırat Ö, Akgün E, Osmanoğlu H. Rektal prolapsus deneyimimiz: 27 yılda 68 vaka. *Ege Journal of Medicine* 2008;47:29-34.
4. Sun C, Hull T, Ozuner G. Risk factors and clinical characteristics of rectal prolapse in young patients. *J Visc Surg* 2014;151:425-429.
5. Rashid Z, Basson MD. Association of rectal prolapse with colorectal cancer. *Surgery* 1996;119:51-55.
6. Erikoğlu M, Tavli S, Tekin S. A rare case of rectal prolapse associated with rectal adenocarcinoma: case report. *Turk J Gastroenterol* 2004;15:266-267.