

Repair of Recurrent Rectovaginal Fistula after Low Anterior Resection with the Martius Flap Technique: Report of a Case

Aşağı Anterior Rezeksiyon Sonrası Gelişen Rekürren Rektovajinal Fistülün Martius Flep Tekniği ile Onarılması: Olgu Sunumu

FATMA AYÇA GÜLTEKİN¹, BÜLENT MENTEŞ², MEHMET OĞUZ²

¹Zonguldak Karaelmas Üniversitesi Tıp Fakültesi, Genel Cerrahi Anabilim Dalı, Zonguldak-Türkiye ²Gazi Üniversitesi Tıp Fakültesi, Genel Cerrahi Anabilim Dalı, Ankara-Türkiye

ÖZET

Rekürren rektovajinal fistüllerin (RRVF) tamiri, tamirde kullanılacak dokunun normal veya yeteri kadar sağlıklı olmaması nedeni ile büyük problem teşkil etmektedir. Yapılan cerrahinin başarısı daha önce yapılmış onarımların sayısı ve kullanılan yöntemlere göre değişmektedir. Biz burada rektum kanseri nedeni ile aşağı anterior rezeksiyon uygulanan ve sonrasında 4 kez rektovajinal fistül nedeni ile ameliyat edilen RRVF'li 54 yaşındaki kadın hastayı sunduk. Hastanın dikkatli bir şekilde değerlendirilmesinden sonra anal girimin 4 cm proksimalinde fistül olduğu tespit edildi. Fistül Martius tekniği ile tamir edildi. Hasta postoperatif dönemde komplikasyonsuz bir şekilde takip edildi.

Anahtar Kelimeler: Rektum kanseri, Rekürren rektovajinal fistül, Martius tekniği

ABSTRACT

Repair of recurrent rectovaginal fistulas (RRVFs) poses a challenging problem due to the fact that tissue used for repair may not be completely normal or in its maximum state of health. Success rate of surgery is severely reduced by number and method of prior repairs. We report the case of 54-year-old woman with RRVFs who was operated for the rectovaginal fistula for four times after low anterior resection for rectum cancer. Following detailed evaluation of the patient, RRVF was found 4 cm proximally to the anal verge. The fistula was repaired with the Martius technique. The patient had an uneventful postoperative course.

Key words: Rectum cancer, Recurrent rectovaginal fistula, Martius technique

Başvuru Tarihi: 10.01.2011, Kabul Tarihi: 03.02.2011

Dr. Fatma Ayça

Zonguldak Karaelmas Üniversitesi Tıp Fakültesi

Uygulama Araştırma Hastanesi Genel Cerrahi

Ad Kozlu 67600 Zonguldak - Türkiye

Tel: 0505.3194119

e-mail: faycagultekin@yahoo.com

Kolon Rektum Hast Derg 2011;21:70-73

Introduction

Although prior anorectal surgery is a frequent cause of rectovaginal fistula, it can rarely occur after low anterior resection. Repair of these simple fistulas with flap advancement techniques or local transrectal, transvaginal or transperineal approaches have been well documented.^{1,3} These same techniques when applied to recurrent rectovaginal fistulas (RRVFs) have high failure rates and poor functional outcomes.^{4,7} Primary repair of rectovaginal fistulas are associated with a success rate of 70 to 97%.^{1,8,10} The reported outcome is worse, 40 to 85%, when patients are undergoing rectovaginal fistula repair after one or more prior repairs have failed.^{6,8,10} The success of repair of RRVFs depends upon the health of the tissue, keeping in mind that it has been seriously effected by the underlying etiology and failed operations, and may therefore not heal.¹¹ In Martius flap technique, which is frequently used for repairing large urethrovaginal, vesicovaginal and rectovaginal fistulas, transposition of healthy and well-vascularized tissue from vaginal walls provides excellent healing for RRVFs.^{12,13} We report a case of rectovaginal fistula following low anterior resection, which was successfully treated with Martius technique after four failed repairs.

Case Report

A 54-year-old woman presented to our proctology unit with a 6-month history of vaginal discharge, and the passage of flatus and stool through the vagina. She

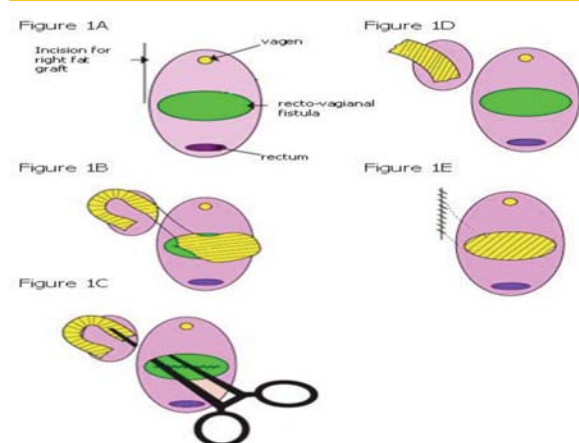


Figure 1. Diagram showing the stages in raising and applying the bulbocavernosus muscular fat pad graft (From Kelly J, Repair of obstetric fistula. *The Obstetrician and Gynaecologist* 2002;4:205-11.).

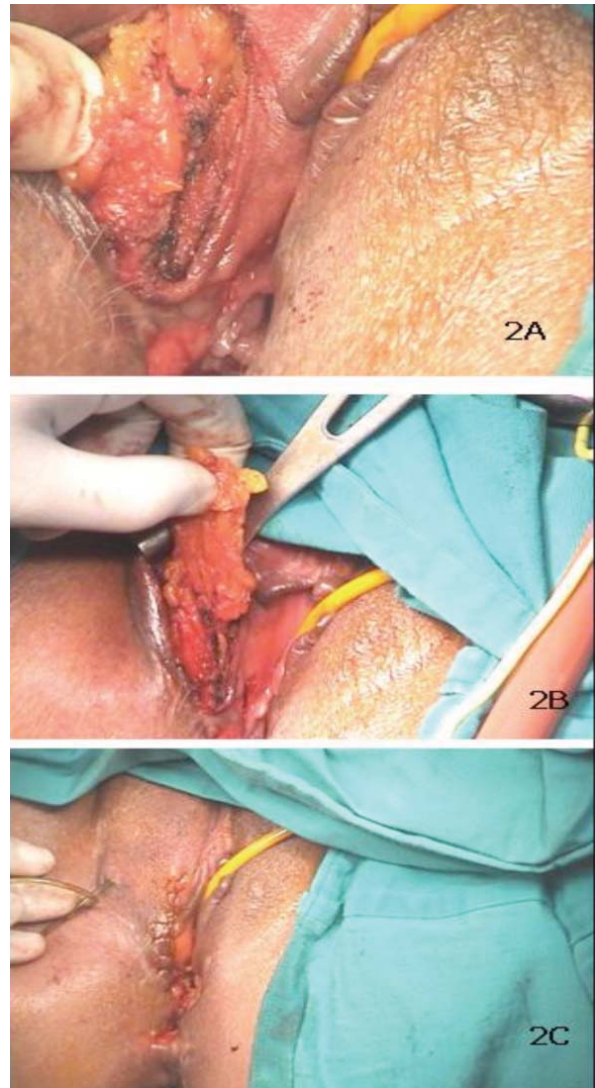


Figure 2. Figures showing the intraoperative stages of the Martius flap technique.

had a history of a stage I adenocarcinoma of the rectum diagnosed 18 months ago at a local hospital. Her metastatic workup was negative. She underwent low anterior resection. The passage of stool through the vagina was noted 7 days after operation, and loop colostomy was immediately performed at same hospital. Following the closure of the colostomy, her symptoms were occurred again, and rectovaginal fistula was defined. She underwent transrectal and transvaginal fistula repairs, both for two times, in 9 months period at different centers. Our physical examination revealed a recurrent rectovaginal fistula 4 cm proximally to the anal verge, which was confirmed by anoscopy. Her radiologic and blood tests

showed no signs for recurrence of malignancy. The patient underwent complete mechanical bowel preparation. After induction of general endotracheal anesthesia, metronidazole (500mg) together with cefoperazone (1000mg) was administered intravenously. She was operated on in the lithotomy position. A curvilinear incision, paralleling the outer edge of the superficial part of the external anal sphincter was used (Fig. 1A and 2A). The area of the incision was limited to 180 degrees anterolaterally to avoid pudendal nerve damage. The posterior vaginal wall was separated from the anterior rectal wall and cephalad mobilization was extended until the fistulous tract was reached and adequately mobilized. The fistulous tract was excised. A vertical incision was then made over the lateral part of the right labium majus. The bulbocavernosus muscular fat pad (pedicled muscular graft) was then separated from adjacent structures (Fig. 1B and 2B). After preserving its posterolateral vascular pedicle, the graft was rotated and tunneled subcutaneously tunnel to the space between vagina and rectum (Fig. 1C and 1D). The graft was sutured to adjacent structures with absorbable sutures (monocryl 2x0) (Fig. 1E and 2C).

At the end of the procedure the subcutaneous layer and the skin was closed. After hemovac drain was placed, the labial wound was closed with absorbable sutures.¹⁴ The patient was immobilized first 24 hours after operation. The hemovac drain was removed second postoperative day. After the operation metronidazole and cefoperazone were administered intravenously twice a day for 5 days. Before releasing from the hospital, she was instructed to take frequent sitz-baths and to refrain from the activities that could harm the flap. Follow-up at 4 months revealed uneventful recovering and no symptoms for RRVFs.

Discussion

Recurrent rectovaginal fistulas are a difficult problem for surgeons. Lowry *et al.*⁸ observed a success rate of 88% in patients without a previous attempt at repair.

The success rate dropped to 55% in patients with two previous attempts at repair.⁵ Similar findings have been reported, both by Watson and by Tsang.^{5,16} Decreased success rate with subsequent repairs may be attributed to poor blood supply and scarring of the rectovaginal septum. According to these observations, it might be possible that interposition of well-vascularised tissue in the rectovaginal septum can improve the success rate of repair. In Martius flap technique, bulbocavernosus muscular fat pad graft brings healthy, well-vascularized tissue to the region. Pinedo and Philips performed an advancement flap with simultaneous labial fat pad graft in small number of patients.¹² They also, performed defunctioning stoma to all these subjects. Unfortunately, they did not specify the healing rate among the patients in whom an advancement flap was used with simultaneous labial fat flap transposition.¹² However, in their series McNevin *et al.*¹⁵ concluded that selected RRVFs can be reliably repaired with good functional outcomes using the Martius flap with anal sphincter reconstruction. In our case, the patient had no sphincter dysfunction, and Martius flap technique was used without concomitant sphincteroplasty. Although some authors recommended defunctioning stoma, the study of Halverson *et al.*⁷ did not demonstrate an advantage in using it. In addition to patient's previous history, since the value of protective stoma remains unclear, we did not create a stoma. At the end of the 4 months follow-up period, excellent wound healing was observed, and no functional deficits related to the flap were noted. The Martius flap technique offers excellent results even after failure of previous RRVFs repair. In our case, patient almost had no healthy tissue, because of the breakdown of prior repairs, and using the bulbocavernosus muscular fat pad graft achieved successful functional outcome. We conclude that the Martius flap technique can be used for repairing complex low rectovaginal fistula with minimal morbidity.

References

1. Kodner IJ, Mazor A, Shemesh EI, *et al.* Endorectal advancement flap repair of rectovaginal and other complicated anorectal fistulas. *Surgery* 1993;114:682-9.
2. Baig MK, Zhao RH, Yuen CH, *et al.* Simple rectovaginal fistulas. *Colorectal Dis* 2000;15:323-7.
3. Sonoda T, Hull T, Piedmonte MR, *et al.* Outcomes of primary repair of anorectal and rectovaginal fistulas using the endorectal advancement flap. *Dis Colon Rectum* 2002;45:1622-8.
4. Khanduja KS, Padmanabhan A, Kerner BA, *et al.* Reconstruction of rectovaginal fistula with sphincter disruption by combining rectal mucosal advancement flap and anal sphincteroplasty. *Dis Colon Rectum* 1999;42:1432-7.
5. Tsang CB, Madoff RD, Wong WD, *et al.* Anal sphincter integrity and function influences outcome in rectovaginal fistula repair. *Dis Colon Rectum* 1998;41:1141-6.
6. McRae HM, McLeod RS, Cohen Z, *et al.* Treatment of rectovaginal fistulas that have failed previous repair attempts. *Dis Colon Rectum* 1995;38:921-5.
7. Halverson AL, Hull TL, Fazio VW, *et al.* Repair of recurrent rectovaginal fistulas. *Surgery* 2001;130:753-8.
8. Lowry AC, Thorson AG, Rothenberger DA, *et al.* Repair of simple rectovaginal fistulas: influence of previous repairs. *Dis Colon Rectum* 1988;31:676-8.
9. Mazier WP, Senagore AJ, Schiesel EC. Operative repair of anovaginal and rectovaginal fistulas. *Dis Colon Rectum* 1995;39:4-6.
10. Ozuner G, Hull TL, Cartmill J, *et al.* Long-term analysis of the use of transanal rectal advancement flaps for complicated anorectal/vaginal fistulas. *Dis Colon Rectum* 1996;39:10-4.
11. Saclarides TJ. Rectovaginal fistula. *Surg Clin North Am* 2002;82:1261-72.
12. Pinedo G, Phillips R. Labial fat pad grafts (modified Martius graft) in complex perianal fistulas. *Ann R Coll Surg Engl* 1998;80:410-12.
13. Chitrathara K, Namratha D, Francis V, *et al.* Spontaneous rectovaginal fistula and repair using bulbocavernosus muscle flap. *Tech Coloproctol* 2001;5:47-9.
14. Zimmerman DD, Gosselink MP, Briel JW, *et al.* The outcome of transanal advancement flap repair of rectovaginal fistulas is not improved by an additional labial fat flap transposition. *Tech Coloproctol* 2002;6:37-42.
15. McNevin MS, Lee PY, Bax TW. Martius flap: an adjunct for repair of complex, low rectovaginal fistula. *Am J Surg* 2007;193:597-9.
16. Watson SJ, Phillips RK. Non-inflammatory rectovaginal fistula. *Br J Surg* 1995;82:1641-3.