



Amiodaron Kullanımına İkincil Akciğer Toksisitesi

Pulmonary Toxicity Secondary to Amiodarone Use

© Didar Arslan¹, © Nagehan Aslan¹, © Dinçer Yıldızdaş¹, © Özden Özgür Horoz¹, © Fadli Demir², © Celal Varan²

¹Çukurova University Faculty of Medicine, Department of Pediatric Intensive Care Medicine, Adana, Turkey

²Çukurova University Faculty of Medicine, Department of Pediatric Cardiology, Adana, Turkey

Abstract

Amiodarone is an antiarrhythmic medication used for the treatment of ventricular tachycardia. In addition to unwanted effects in many tissues, one of the most important side effects of the drug is pulmonary toxicity. Toxicity may develop at any time after administration to the drug, and the risk increases depending on the dose and duration of the treatment. Clinical and laboratory findings are non-specific. In treatment, amiodarone is discontinued. In severe cases, corticosteroid therapy can be started. Here, we present the case of a patient who was followed up for two years for hypertrophic cardiomyopathy and presented to the pediatric emergency department with hemoptysis, dizziness, clouding of consciousness and numb tongue. Amiodarone was used for two years to treat ventricular arrhythmia. The findings of the patient at presentation were thought to be due to amiodarone pulmonary toxicity. Amiodarone was stopped and corticosteroid therapy was initiated. Non-invasive mechanical ventilation was applied for 3 days. On the 8th day of hospitalization, the patient was transferred to the ward. The aim of this case report was to draw attention to pulmonary toxicity due to amiodarone administration.

Keywords: Amiodarone, children, pulmonary toxicity

Öz

Amiodaron ventriküler aritmi tedavisinde kullanılan bir antiaritmiktir. Birçok dokuda yan etkiye neden olan ilacın en önemli yan etkilerinden biri akciğer toksisitesidir. İlaç başlandıktan sonra herhangi bir zamanda toksisite gelişebilir, doz ve süre bağımlı olarak bu risk artar. Klinik ve laboratuvar bulguları özgül değildir. Tedavide öncelikle amiodaron kesilir. Ciddi olgularda kortikosteroid tedavisi başlanabilir. Biz burada 3 yıldır hipertrofik kardiyomiyopati nedeni ile takip edilen ve çocuk acil servise hemoptizi, baş dönmesi, bilinç bulanıklığı ve öksürük şikayeti ile başvuran ve 2 yıldır ventriküler aritmi için amiodaron kullanan 16 yaşındaki erkek hastayı sunduk. Hastanın başvurusundaki bulgular bize amiodarona bağlı akciğer toksisiteyi düşündürdü. Amiodaron kesildi. Kortikosteroid tedavisi başlandı. Üç gün non-invazif mekanik ventilasyon tedavisi uygulandı. Hasta, yatışının 8. gününde servise devredildi. Bu olgu amiodaron ilişkili akciğer toksisiteye dikkat çekmek için sunuldu.

Anahtar Kelimeler: Amiodaron, çocuk, akciğer toksisitesi

Introduction

Amiodarone is an antiarrhythmic used in the treatment of recurrent ventricular tachycardia and ventricular fibrillation. Due to its iodine content, it has side effects involving the cornea, liver, lung, neuromuscular system, skin, and thyroid. It has a long elimination half-life (up to 6 months).¹ Amiodarone-related pulmonary toxicity is the most serious and life-threatening side effect associated with the drug. Patients usually present with shortness of breath, fatigue, cough, fever, and chest pain. Laboratory findings indicate leucocytosis and elevated erythrocyte sedimentation rate (ESR). Amiodarone-

related pulmonary toxicity is associated with the total cumulative dose rather than plasma concentration. There are a few reported cases of children with amiodarone pulmonary toxicity.² Here, we discuss this life-threatening side effect and the treatment approach in the light of the literature by presenting a case of amiodarone-related pulmonary toxicity.

Case

A 16-year-old male patient with an implantable cardioverter defibrillator (ICD) who has been under follow-up for

Address for Correspondence/Yazışma Adresi: Nagehan Aslan MD, Çukurova University Faculty of Medicine, Department of Pediatric Intensive Care Medicine, Adana, Turkey

Phone: +90 505 549 99 86 **E-mail:** nagehan_aslan@hotmail.com **ORCID ID:** orcid.org/0000-0002-6140-8873

Received/Geliş Tarihi: 05.03.2018 **Accepted/Kabul Tarihi:** 16.07.2018

©Copyright 2019 by Society of Pediatric Emergency and Intensive Care Medicine
Journal of Pediatric Emergency and Pediatric Intensive Care published by Galenos Yayınevi.

hypertrophic cardiomyopathy (CMP) for three years presented to the pediatric emergency department with the complaints of sudden dizziness, unconsciousness, numbness of tongue and cough. Due to clouding of consciousness in initial evaluation, cranial computed tomography was taken and interpreted as normal. Echocardiography (ECO) showed ejection fraction (EF) measurement of 45%; electrocardiography (ECG) was normal. Due to clouding of consciousness, hemoptysis and tachypnea, he was admitted to the pediatric intensive care unit for further diagnosis and treatment.

When the patient's medical history was further explored, it was seen that he has been under cardiology follow-up for 3 years due to hypertrophic CMP, he had suffered a myocardial infarction 1 year ago and had ICD, and has been receiving amiodarone 200 mg daily for 2 years due to ventricular arrhythmia. Physical examination revealed drowsiness, a body temperature of 37.8 °C, pulse rate of 79/min, arterial blood pressure of 118/84 mmHg, glasgow coma score (GCS) of 11, respiratory rate of 32/min, oxygen saturation rate of 80-85%, and bilateral crepitant rales. System examinations and laboratory tests were unremarkable. Arterial blood gas testing showed a PaO₂/FiO₂ ratio of 130. Bilateral pulmonary infiltration was present on the posteroanterior (PA) chest radiograph (Figure 1). Non-invasive mechanical ventilation therapy with full-face mask was started in the patient whose tachypnea persisted and who had low oxygen saturation. Since infection could not be eliminated, antibiotic therapy was started. Milrinone and lasix infusions were administered due to low ejection fraction. Clinical symptoms of the patient did

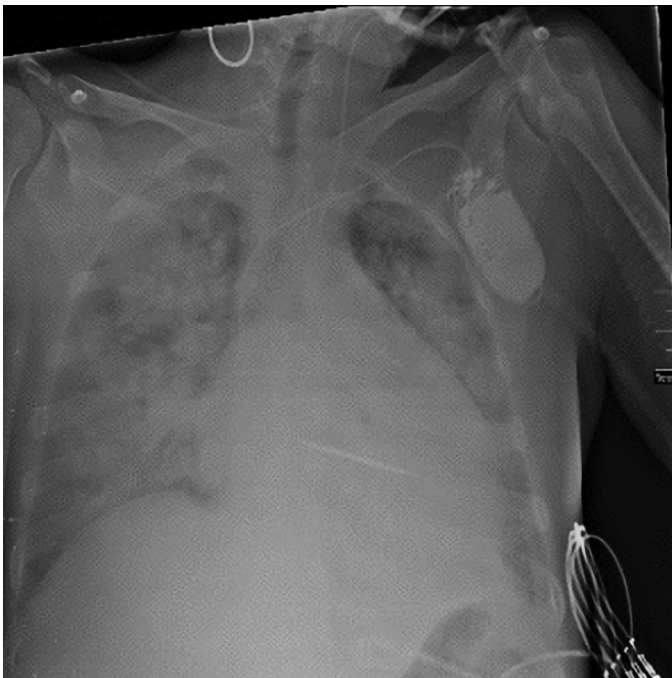


Figure 1. Bilateral pulmonary infiltration on posteranterior chest graphy at admission

not recover with the current therapies but ECG findings got better. The patient was diagnosed with amiodarone-related pulmonary toxicity and, amiodarone therapy was discontinued and methylprednisolone therapy was started. Sotalol was initiated as an antiarrhythmic instead of amiodarone. Oxygen saturation was >92%, blood gases were normal, PaO₂/FiO₂ ratio rose to 255, and chest radiography symptoms regressed (Figure 2). In follow-up, non-invasive mechanical ventilation was stopped. Oxygen was administered using a non-rebreathing mask with an oxygen reservoir bag attached. On the eighth day of the hospitalization, he was transferred to the general ward. Verbally informed consent was obtained from the patient's family.

Discussion

The most serious side effect of amiodarone use is pulmonary toxicity, and it is also the most important cause of drug withdrawal. The risk of toxicity increases in time and the highest risk is within the 6-12 months of therapy.³ The increased risk of toxicity over time can be explained by the long half-life. There are no diagnostic criteria for amiodarone-related pulmonary toxicity; diagnosis is based on the exclusion of diagnoses that may cause the same clinical symptoms (heart failure, pneumonia, tuberculosis or pulmonary fibrosis secondary to systemic lupus erythematosus SLE, and use of drugs such as bleomycin, methotrexate, etc.).⁴ In our case, heart failure and pneumonia were excluded and amiodarone-related pulmonary toxicity was considered.

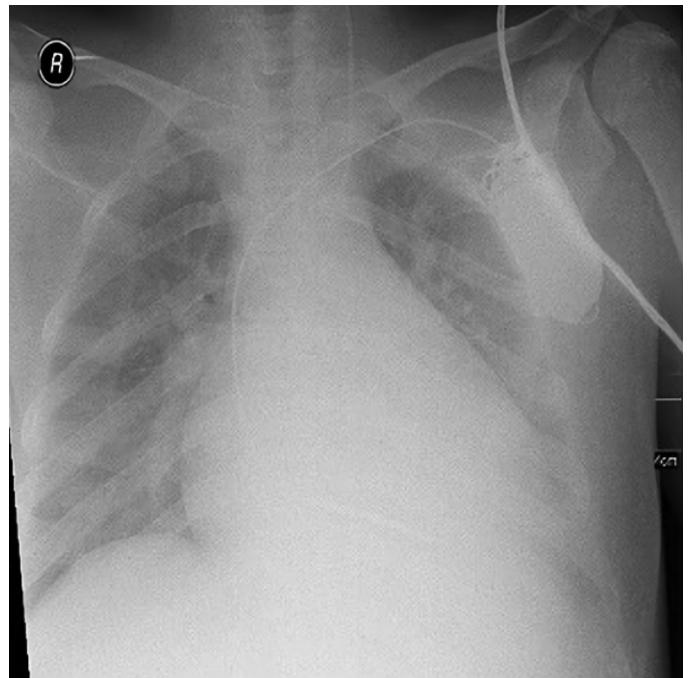


Figure 2. Posteroanterior chest graphy at the 72nd hour of hospitalization

Two mechanisms that are addressed in amiodarone-associated pulmonary toxicity are direct toxicity and hypersensitivity reactions. After starting amiodarone treatment, toxicity may develop at any time, but the risk increases significantly with a daily dose of 400 mg for more than 2 months, or a daily dose of 200 mg for more than 2 years. The incidence of pulmonary toxicity in patients taking 400 mg or more per day is 5-15%. In our case, the patient has been receiving amiodarone 200 mg daily for 2 years.

Frequent manifestations of amiodarone-related pulmonary toxicity include subacute diffuse interstitial pneumonia, eosinophilic pneumonia, and pulmonary fibrosis while multiple lung nodules, diffuse alveolar injury, AC edema with/without ARDS, diffuse alveolar hemorrhage, bronchospasm, and pleural effusion are rare manifestations.⁵ Risk increases in parallel with the increasing dose, therefore, patients should be treated with low doses. Patients need to be informed with regards to respiratory symptoms during drug use. Routine diagnosis is not recommended in follow-up and when pulmonary toxicity is suspected, PA chest radiograph should be taken first which usually reveals bilateral and diffuse infiltrates.⁵

Amiodarone should be discontinued in patients with pulmonary toxicity. Recurrence can be seen within 8 months of drug withdrawal.⁶ Corticosteroid therapy should be administered, despite the lack of studies on its effectiveness in severe cases. There are pediatric amiodarone-induced pulmonary toxicity cases where recovery was achieved through corticosteroid therapy.⁷ 40-60 mg prednisolone per day should be started orally and should be tapered and discontinued within 4-12 months.⁵ Due to the accumulation in the fat tissues, patients with a high body mass index are more susceptible to recurrence with rapid steroid withdrawal.⁸

Every drug used in pediatric practice should be monitored for side effects. Suspicion and early identification of pulmonary toxicity in patients receiving amiodarone treatment and presenting with respiratory signs is of vital importance. The drug should be discontinued after differential diagnosis.

Ethics

Informed Consent: Verbally informed consent was obtained from the patient's family.

Peer-review: Externally peer-reviewed.

Authorship Contributions

Surgical and Medical Practices: D.Y., F.D., C.V., Concept: D.A., D.Y., Design: D.A., N.A., D.Y., Data Collection or Processing: D.A., Ö.Ö.H., N.A., Analysis or Interpretation: D.A., Ö.Ö.H., Literature Search: D.A., N.A., Writing: D.A., N.A.

Conflict of Interest: Yazarlar tarafından çıkar çatışması bildirilmemiştir.

Financial Disclosure: Yazarlar tarafından finansal destek almadıkları bildirilmiştir.

References

1. Vassallo P, Trohman RG. Prescribing amiodarone. *JAMA*. 2007;298:1312-22.
2. Bowers PN, Fields J, Schwartz D, Rosenfeld LE, Nehgme R. Amiodarone induced pulmonary fibrosis in infancy. *Pacing Clin Electrophysiol*. 1998;21:1665-7.
3. Ernawati DK, Stafford L, Hughes JD. Amiodarone-induced pulmonary toxicity. *Br J Clin Pharmacol*. 2008;66:82-7.
4. Stelfox HT, Ahmed SB, Fiskio J, Bates DW. Monitoring amiodarone's toxicities: recommendations, evidence, and clinical practice. *Clin Pharmacol Ther*. 2004;75:110-22.
5. Wolkove N, Baltzan M. Amiodarone pulmonary toxicity. *Can Respir J*. 2009;16:43-8.
6. Joelson J, Kluger J, Cole S, Conway M. Possible recurrence of amiodarone pulmonary toxicity following corticosteroid therapy. *Chest*. 1984;85:284.
7. Labombarda F, Ou P, Stos B, de Blic J, Villain E, et al. Acute Amiodarone-induced Pulmonary Toxicity: An Association of Risk Factors in a Child Operated by Arterial Switch Operation. *Congenit Heart Dis*. 2008;3:365-7.
8. Okayasu K, Takeda Y, Kojima J, Yoshizawa A, Kobayashi N, et al. Amiodarone pulmonary toxicity: A patient with three recurrences of pulmonary toxicity and consideration of the probable risk of relapse. *Intern Med*. 2006;45:1303-7.