

Pseudoexfoliative Glaucoma in a Patient with Toxic Optic Atrophy and Cupping

Toksik Optik Atrofi ve Disk Çukurlaşması Olan Bir Hastada Gelişen Psödoeksfolyatif Glokom

Ali Aydın, Ümit Aykan, Akın Çakır, Taner Kar, Dilaver Erşanlı

Gülhane Military Medical Academy, Haydarpaşa Training Hospital, Department of Ophthalmology, Istanbul, Turkey

Summary

A 57-year-old man, who had developed bilateral symmetric optic atrophy and cupping due to methanol intoxication nine years ago, noticed slowly progressive visual impairment in the left eye (OS). In ophthalmic examination, visual acuity was 20/60 in the right eye (OD) and 'hand motion' in OS. Intraocular pressure was 20 in OD and 28mmHg in OS. Anterior segment biomicroscopy showed bilateral pseudoexfoliation, more intense in OS. Ophthalmoscopy revealed bilaterally deep and wide cupping with cup-to-disc ratios of 8/10 in OD and approximately 10/10 in OS. Based on these findings, the diagnosis of left pseudoexfoliative glaucoma, in addition to bilateral toxic optic atrophy and cupping, was made. Pathological optic-disc cupping may be caused by many conditions other than glaucoma. In these cases, glaucoma may aggravate the both cupping and atrophy. (*Turk J Ophthalmol 2011; 41: 256-9*)

Key Words: Optic disc cupping, methanol intoxication, pseudoexfoliation glaucoma

Özet

Dokuz yıl önce geçirdiği metanol zehirlenmesine bağlı bilateral simetrik optik atrofi ve disk çukurlaşması olan 57 yaşında bir erkek hasta, sol gözünde yavaş gelişen ilerleyici görme azalması şikayetiyle başvurdu. Göz muayenesinde, görme keskinliği sağ gözde 3/10, sol gözde el hareketleri düzeyindeydi. Göz içi basıncı sağda 20 solda 28 mmHg olarak ölçüldü. Ön segment biyomikroskopik muayenesinde solda ileri olmak üzere her iki gözde psödoeksfolyasyon izlendi. Fundus muayenesinde her iki gözde geniş ve derin bir disk çukurlaşması olduğu görüldü; çukurluk-disk oranları sağda 8/10 solda ise yaklaşık 10/10 düzeyindeydi. Bu bulgularla hastaya, bilateral toksik optik atrofi ve disk çukurlaşmasına eklenmiş sol psödoeksfolyatif glokom tanısı konuldu. Patolojik disk çukurlaşması glokom dışında bir çok hastalığın etkisiyle de oluşabilir. Böyle durumlarda tabloya eklenen glokom, disk çukurlaşmasını ve optik atrofiyi ağırlaştırabilir. (*Turk J Ophthalmol 2011; 41: 256-9*)

Anahtar Kelimeler: Optik disk çukurlaşması, metanol zehirlenmesi, psödoeksfolyatif glokom

Introduction

Optic-disc cupping is most often caused by glaucoma, but may be seen in many infrequent neuro-ophthalmic and oncologic pathologies that are not associated with elevated intraocular pressure (IOP), such as congenital optic-disc anomalies (e.g. optic-disc coloboma, pits, hypoplasia, optic nerve head drusen and tilted disc), optic neuropathies (e.g. ischemic, traumatic,

hereditary and toxic) and compressing orbital, cerebral or optic nerve tumors.¹⁻⁵ Although seldom seen, methanol poisoning must be also considered in the group of toxic optic neuropathies causing non-glaucomatous optic-disc cupping with optic atrophy.⁶⁻⁸

In this article, we present a patient with toxic optic atrophy and cupping caused by methanol poisoning and pseudoexfoliative glaucoma which was added to this pathology.

Yazışma Adresi/Address for Correspondence: Dr. Ali Aydın, Gülhane Military Medical Academy, Haydarpaşa Training Hospital, Department of Ophthalmology, Istanbul, Turkey Tel.: +90 216 542 20 20/4406 E-posta: aliyaydin67@hotmail.com

Geliş Tarihi/Received: 09.01.2011 **Kabul Tarihi/Accepted:** 07.03.2011

This case report was presented as a poster in the 43rd National Congress of Turkish Society of Ophthalmology

Case Report

A 57-year-old man who had been diagnosed with bilateral advanced glaucoma was referred for glaucoma consultation. He noticed increasing visual impairment in his left eye over several months. In ophthalmic examination, visual acuities were 20/60 in the right (OD) and 'hand motion' in the left eye (OS). Pupillary light reflex was sluggish in both eyes and there was a relative afferent pupillary defect (RAPD) in OS. Anterior segment biomicroscopy showed bilateral pseudoexfoliation on the anterior lens surface and pupillary margin, more intense in OS. IOPs measured by Goldmann applanation tonometry were 20mmHg in OD and 28 mmHg in OS. Central corneal thickness was 534 μm in OD and 542 μm in OS. On funduscopy, there was bilateral striking cupping with cup-to-disc ratios of 8/10 in OD and approximately 10/10 in OS. The neuroretinal rim was pale and the brightness of the retinal nerve fiber layer (RNFL) was absent in both eyes (Figure 1).

Formal automated visual fields (Humphrey SITA-Standard 30-2) demonstrated total visual field defect in both eyes. So, a central 10-2 perimetry was performed using Humphrey Matrix FDT (Zeiss, Dublin, CA, USA). This test revealed diffuse visual field loss, severely in OS (Figure 2).

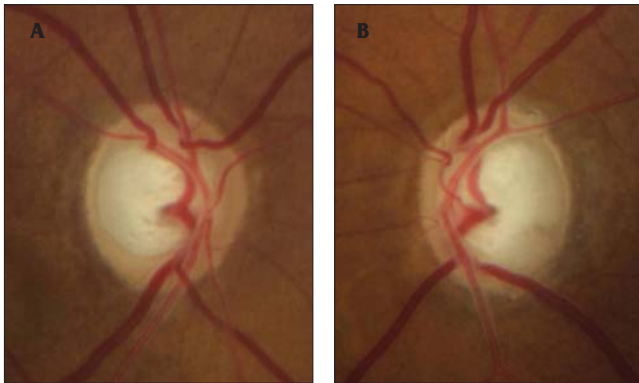


Figure 1. In a patient with a history of methanol intoxication, color fundus photography showed bilaterally deep and wide cupping with cup-to-disc ratios of 8/10 in the right (a) and approximately 10/10 in the left eye (b). The neuroretinal rim was pale and the brightness of the retinal nerve fiber layer was absent in both eyes

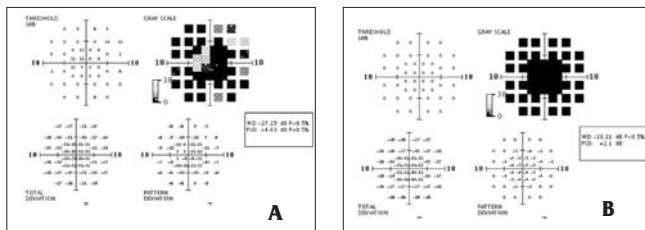


Figure 2. The central 10-2 perimetry testing performed with Humphrey Matrix FDT revealed diffuse visual field loss (a - OD, b - OS), being severe in OS (b)

In the optic disc topography obtained by the Heidelberg Retinal Tomograph (HRT II, Heidelberg Engineering GmbH, Germany), bilateral advanced neuroretinal rim damage was detected and the patient was diagnosed with bilateral glaucoma according to the Moorfields classification (Figure 3). The mean peripapillary RNFL thickness measured by a spectral optic coherence tomography device (spectral OCT/SLO, OTI Inc., Toronto, Canada) was 64 μm in OD and 39 μm in OS. The physiological "double-hump" appearance of the peripapillary RNFL was deteriorated bilaterally (Figure 4).

Despite these findings which may be associated with bilateral advanced glaucoma, we thought that the cupping, especially in OD, was not glaucomatous, based on the signs such as the pallor of rims, horizontal elongation of cup-disc ratio, RAPD and severely impaired visual acuity. Detailed investigation revealed that the patient had methanol intoxication caused by counterfeit raki (a Turkish alcoholic drink) consumption nine years ago. According to patient's records of examination performed 8 months after

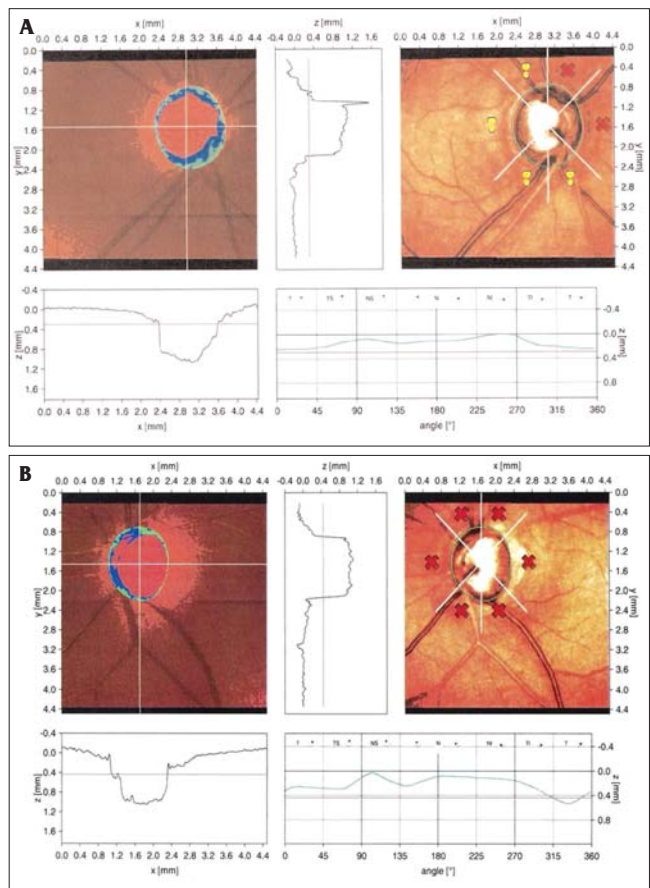


Figure 3. In the optic disc topography obtained by the Heidelberg Retinal Tomograph II, an advanced neuroretinal rim damage with an extensive cupping was detected in both eyes (A - OD, B - OS) and the patient was diagnosed as having bilateral glaucoma according to the Moorfields classification

the intoxication, he had bilateral symmetric optic atrophy and cupping: the C/D ratio was 0.8, IOP 12 mmHg and his visual acuity was 20/60 bilaterally. Based on these findings, the patient was diagnosed with bilateral optic atrophy and cupping due to methanol intoxication, and pseudoexfoliative glaucoma in OS.

Discussion

Methyl alcohol is used as a solvent-indicator and a reactant in ethyl alcohol denaturing processes in chemical industry. The substances containing methyl alcohol include adhesives, paint thinners, glass cleaner fluids, copier fluids, carburetor fluids and antifreezes. Because of its cheaper cost in our country, it is used in the production of counterfeit raki, and methyl alcohol poisonings often arise with oral intake of them. Its chemical structure, odor and taste are similar to ethyl alcohol. Not methanol itself but the metabolites like formaldehyde and formic acid have toxic effects in the body.⁹ Formic acid causes cell death by inhibiting the cytochrome oxidase complex in the mitochondrial respiratory chain.¹⁰

In animal studies, cell damage due to methyl alcohol intoxication has been shown in the white matter of the brain and in the optic nerve axons at the optic disc level.^{11,12} In the acute period, fundus examination shows an optic disc hyperemia similar to the papilloedema and sometimes peripapillary retinal edema. While fundus findings regress in a two-month process, a permanent optic atrophy appears, therefore, the visual prognosis is poor.¹³ On the other hand, necrosis in the putamen and subcortical areas of the central nervous system has been reported.¹⁴ It has been considered that methanol damage happens both in the optic disc and in the section of the optic nerve immediately behind the lamina cribrosa, due to high arterial flow. Retrograde retinal ganglion cell damage occurs because of axonal necrosis.^{9,11,12}

In the literature, there are only three publications about the optic disc cupping caused by methanol intoxication. In the first of them, Benton and Calhoun reported that optic disc cupping similar to glaucoma could also be seen rarely with optic atrophy in their large series of methanol intoxication.¹⁵ Stelmach and O'day presented a young female patient with methanol poisoning owing to counterfeit alcohol intake and observed that symmetric disc cupping could also occur with optic atrophy and some visual functions could be maintained by treatment.¹⁶ Also, Sharma et al.⁶ reported a 31-year-old male patient with methanol intoxication because of counterfeit alcohol consumption and noted that his visual acuity was decreased to light perception, and then a symmetric and deep cupping with optic atrophy emerged after a period of 8 months. In these studies cited above, there is no any theory about the mechanism by which the optic disc cupping occurs following the optic atrophy. Sharma et al. briefly connected this advanced cupping to the acute and excessive loss of ganglion cells.⁶ But most of the patients with methanol poisoning already have acute and excessive loss of ganglion cells; however, disc cupping is seen rarely. Consequently, it is not possible to explain the mechanism of the cupping with this theory.

In conclusion, although optic-disc cupping is one of the essential findings in glaucoma, it may also be seen in many less-common neuro-ophthalmic and oncological pathologies that are not associated with elevated intraocular pressure. So, we have to consider the distinctive signs of glaucomatous cupping in the patient with optic-disc cupping. Furthermore, the patients with toxic optic atrophy and non-glaucomatous cupping should be enrolled to a periodic follow-up program if they have the risk factors such as pseudoexfoliation, family history of glaucoma, age, etc., because they can completely lose their retinal ganglion cells, which have already been damaged in small number due to insidiously developing glaucoma, as seen in our case.

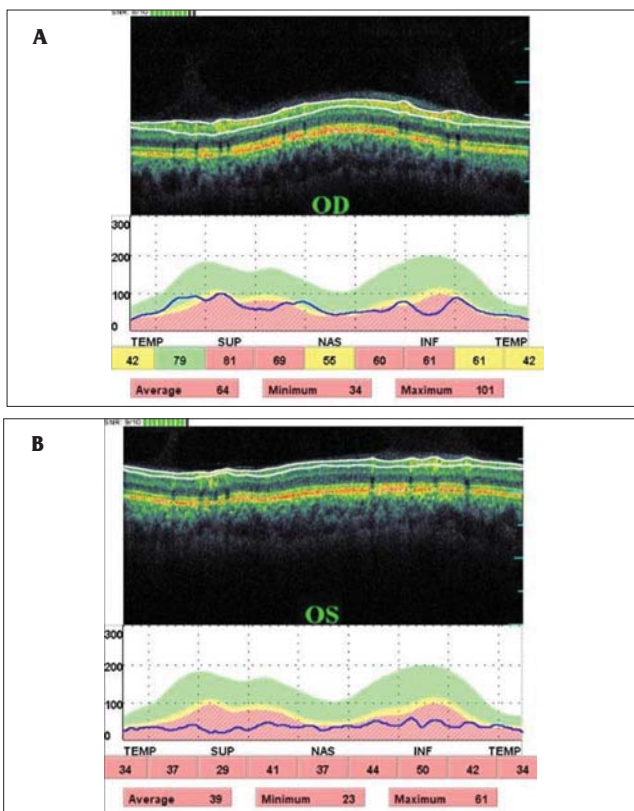


Figure 4. In a patient with a history of methanol intoxication, color fundus photography showed bilaterally deep and wide cupping with cup-to-disc ratios of 8/10 in the right (a) and approximately 10/10 in the left eye (b). The neuroretinal rim was pale and the brightness of the retinal nerve fiber layer was absent in both eyes

References

1. Sadun AA, Agarwal MR. Topical diagnosis of acquired optic nerve disorders. In: Miller NR, Newman NJ; Walsh and Hoyt's Clinical Neuro-Ophthalmology (6th Edition). Lippincot Williams and Wilkins, Philadelphia, PA, USA, 2004, vol 1 chap 4 P:197-236.
2. Moore M, Salles D, Jampol LM. Progressive optic nerve cupping and neural rim decrease in a patient with bilateral autosomal dominant optic nerve colobomas. *Am J Ophthalmol.* 2000;129:517-20.
3. Dutton GN. Congenital disorders of the optic nerve: excavations and hypoplasia. *Eye.* 2004;18:1038-48.
4. Sebag J, Thomas JV, Epstein DL, Grant WM. Optic disc cupping in arteritic AION resembles glaucomatous cupping. *Ophthalmology.* 1986;93:357-61.
5. Partney GL, Roth AM. Optic cupping caused by an intracranial aneurysm. *Am J Ophthalmol.* 1982;84:98-103.
6. Sharma M, Nicholas JV, Evan BD. Methanol-induced optic nerve cupping. *Arch Ophthalmol.* 1999;117:286.
7. Greenfield DS. Glaucomatous versus nonglaucomatous optic disc cupping: clinical differentiation. *Semin Ophthalmol.* 1999;14:95-108.
8. Piette SD, Sergott RC. Pathological optic-disc cupping. *Curr Opin Ophthalmol.* 2006;17:1-6.
9. Grant WM, Schuman JS. Toxicology of the eye (4th Edition). Charles C Thomas Publisher Ltd, Springfield, IL, USA, 1993.
10. Sharpe JA, Hostovsky M, Bilbao JM, Rewcastle NB. Methanol optic neuropathy: a histopathological study. *Neurology.* 1982;32:1093-100.
11. Martin-Amat G, Tephly TR, McMartin KE, Makar AB, Hayreh MS, Hayreh SS et al. Methyl alcohol poisoning.II. Development of a model for ocular toxicity in methyl alcohol poisoning using the rhesus monkey. *Arch Ophthalmol.* 1977;95:1847-50.
12. Hayreh MS, Hayreh SS, Baumbach GL, Cancilla P, Martin-Amat G, Tephly TR et al. Methyl alcohol poisoning III. Ocular toxicity. *Arch Ophthalmol.* 1977;95:1851-8.
13. Mutlu FM, Bayer A, Sobacı G, Kütükçü Y, Yıldırım E. Metil alkol intoksikasyonunda göz ve santral sinir sistemi bulguları. *Turk J Ophthalmol.* 1999;29:264-8.
14. Onder F, Ilker S, Kansu T, Tatar T, Kural G. Acute blindness and putaminal necrosis in methanol intoxication. *Int Ophthalmol.* 1998-1999;22:81-5.
15. Benton CD, Calhoun FP. The ocular side effects of methyl alcohol poisoning: report of a catastrophe involving 320 persons. *Trans Am Acad Ophthalmol Otolaryngol.* 1952;36:875-83.
16. Stelmach MZ, O'Day J. Partly reversible visual failure with methanol toxicity. *Aust N Z J Ophthalmol.* 1992;20:57-63.