

## Bullous Pemphigoid in Two Children

Okan Kızılyel,<sup>1\*</sup> MD, Mustafa Atasoy,<sup>1</sup> MD, Handan Bilen,<sup>1</sup> MD, Necmettin Akdeniz,<sup>1</sup> MD, Akın Aktaş,<sup>1</sup> MD, M. Sami Metin,<sup>1</sup> MD, Ömer Faruk Elmas,<sup>1</sup> MD

Address: <sup>1</sup>Department of Dermatology, Faculty of Medicine, Ataturk University, Erzurum, Turkey

E-mail: erester.34@hotmail.com

\* Corresponding Author: Dr. Okan Kızılyel, Ataturk University, Faculty of Medicine, Department of Dermatology, Erzurum, Turkey.

Published:

J Turk Acad Dermatol 2014; 8 (3): 1483c5

This article is available from: <http://www.jtad.org/2014/3/jtad1483c5.pdf>

**Key Words:** Bullous pemphigoid, case report, child, infant

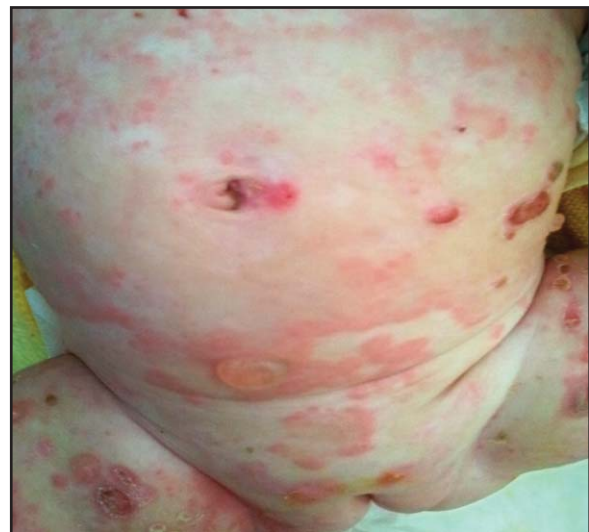### Abstract

**Observation:** Bullous pemphigoid is an autoimmune subepidermal blistering disease that most commonly arise in older adults. Bullous pemphigoid is extremely rare in children. Patients were 6-month girl and 6-year old boy admitted to the hospital because of diffuse erythematous plaques and blisters. Biopsies were taken. Topical and oral corticosteroid treatments were started. Childhood BP is similar to adult BP but differs in some features such as palm, soles, mucosal and genital involvement. Treatment may include local and systemic steroid with or without combination with dapsone, sulfapyridine and mycophenolate mofetil. BP should be in mind when a child with erythematous plaques, vesicles and blisters on the palm, soles and body.

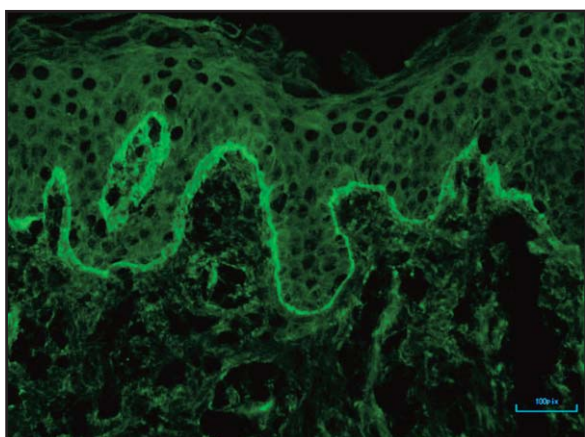
### Introduction

Bullous pemphigoid (BP) is a subepidermal blistering disease mostly seen elderly and extremely rare in children [1]. Over 50 cases of childhood BP have been described [2]. Clinical features of childhood bullous pemphigoid are similar to those of adult BP but involvement of mucous membrane, palm and soles are more common in childhood BP [3]. There appears to be no predilection for race or gender [3, 4]. Diagnosis is made on clinical, histological and immunofluorescence features. Histopathologic findings include subepidermal blisters as well as eosinophilic dermal infiltrations. Direct immunofluorescence shows linear deposition of IgG and C3 at the basement membrane zone [5, 6]. Systemic corticosteroid therapy is the treatment of choice in childhood BP [3]. In limited disease responses to topical corticosteroid therapy. Aside from corticosteroid, sulfapyridine and dapsone have often been used in childhood

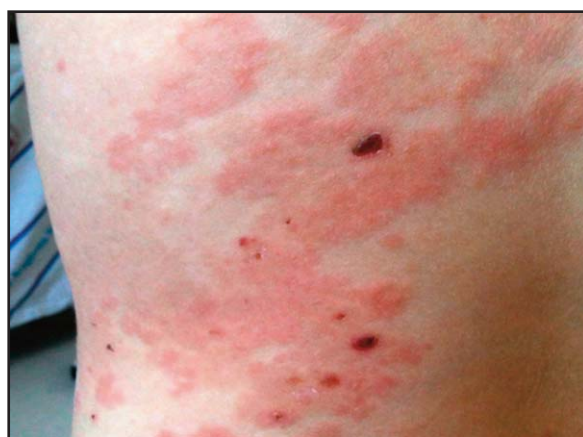BP as sole agents or in combination with corticosteroid, with variable success [7]. We decided to report these two cases because BP is



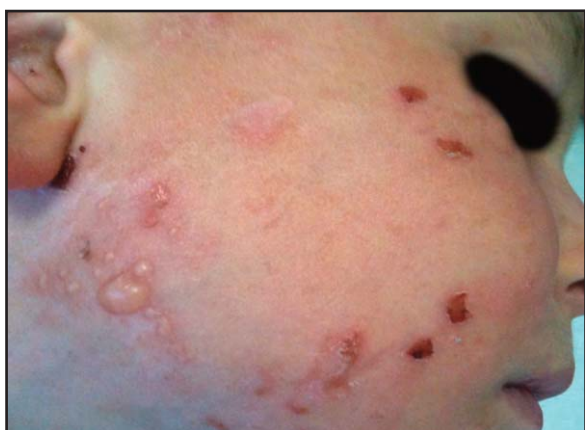**Figure 1.** Skin examination of infant showed diffuse erythematous plaques and blisters on her chest, back and extremities



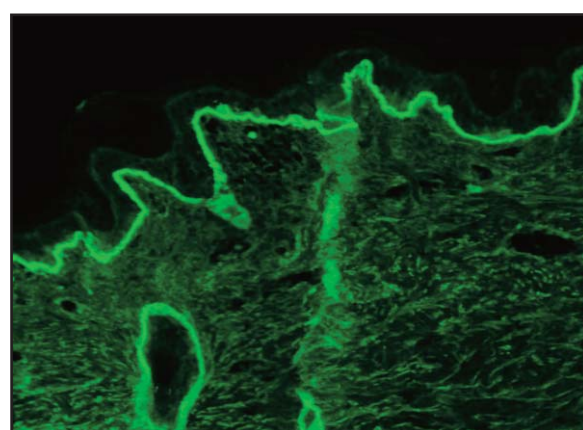
**Figure 2.** Direct immunofluorescence (DIF) test demonstrated linear IgG strongly but IgA and C3 mildly along the basement membrane zone



**Figure 3.** Skin examination of patient showed diffuse urticaria like erythematous plaques blisters on his chest, back and extremities



**Figure 4.** Skin examination of patient showed diffuse urticaria like erythematous plaques blisters on face



**Figure 5.** DIF test demonstrated linear IgG, IgA and C3c along the basement membrane zone

a very rare childhood disease and differs from classic BP in some clinical features and prognosis.

### Case 1

The patient is a 6-month girl admitted to the hospital because of diffuse erythematous plaques and blisters of 2 month duration. She was born after normal pregnancy. Mother was healthy. When patient admitted to hospital she had infected blisters and suffered from diarrhea. There weren't any history of vaccination or drug use before blisters. Skin examination of infant showed diffuse erythematous plaques and blisters on her chest, back and extremities (**Figure 1**). Mucous membrane was spared of lesions. Nikolsky's sign was negative. There were palmoplantar plaques and blisters also. Laboratory tests were normal except mild leukocytosis of 12.900 with 32% neutrophil. Skin biopsy specimen showed a subepidermal bulla, eo-

sinophil infiltrates in papillary dermis and spongiosis and neutrophil in epidermis. Direct immunofluorescence (DIF) test demonstrated linear IgG strongly but IgA and C3 mildly along the basement membrane zone (**Figure 2**). Oral corticosteroid treatment was initiated with methylprednisolone 10mg/day. There was clearing of blisters but when dose decreased to 5mg/day blisters occurred again.

### Case 2

Patient is a 6-year old boy admitted to the hospital because of diffuse erythematous plaques and blisters of 6 month duration. Parents are healthy. When patient admitted to hospital lesions were very itchy, erythematous and bullous. There weren't any history of vaccination, drug or chronic disease. Skin examination of patient showed diffuse urticaria like erythematous plaques blisters on his chest, back, extremities and face (**Figures 3 and**

4). Mucous membrane was spared of lesions. There were two ulcers on his wrists bilaterally. One was 3x2cm in diameter on his right wrist the other was 2x2cm in diameter on his left wrist. Nikolsky's sign was negative. All laboratory tests were normal. Skin biopsy specimen showed a subepidermal bulla. DIF test demonstrated linear IgG, IgA and C3c along the basement membrane zone (**Figure 5**). Oral corticosteroid treatment was initiated with methylprednisolone 20mg/day. Lesions were healed but when dose decreased lesions activated again. Then dapsone 25mg/day started. Skin spared of blisters but sometimes urticaria like plaques occurs again.

### Discussion

BP is characterized by large, tense blisters arising on normal or erythematous skin. BP has been reported to develop autoimmune process, after vaccination, drug intake and following several inflammatory skin diseases. Etiology of childhood BP is also unknown. However, drug intake and vaccination have been incriminated in some cases [8]. Baykal et al. reported a case who is 3.5-old boy presented generalized blisters 24 hours after the first tetracoq vaccine (diphtheria, tetanus-whooping cough-polio-myelitis) [9]. In our cases there was no vaccinations history. Mucous membrane involvement is about 10-35%. Sites of predilection are lower abdomen, inner thighs, flexor forearms or generalized. Blisters may have clear or hemorrhagic fluid. Nikolsky's sign is negative. There may be mild or moderate pruritus and early lesions tend to look like urticarial [10]. In our patients blisters generally arised on erythematous skin, there wasn't mucous membrane involvement and Nikolsky's sign was negative. Childhood BP shows similar clinical and histopathological features to adult form but differ in some aspects. Mucous membrane and palmoplantar involvement are seen in childhood BP more than adult BP [6]. A characteristic feature of childhood BP is the marked involvement of palms and soles described in infants under 1 years of age [6]. Oranje reported mucosal findings in almost 50% of patients studied but Nemeth found mucosal involvement 72% of children [11, 12]. The majority of patients with genital involvement are girls and their disease is limited to genital area [7]. Kawachi and et all. demonstrated a strong eosinophil-cholony stimulating activity in blister fluid

from BP lesions, which should responsible for the eosinophilia observed in these patients [13]. In our cases there weren't eosinophilia but there was eosinophil infiltrate in dermis and bulla in 6 month infant case. BP blood IgE level may be high. Immunofluorescence testing is necessary for distinguishing BP from other bullous diseases. Zinman et.al study showed that DIF testing shows IgG about 95%, C3 about 95%, IgM about 10% and IgA about 12% [7]. In our cases there were IgG, IgA and C3 involvement. This study also showed acral distribution is about 79%, facial distribution about 62%, generalized involvement 59%, mucosal involvement 15% and genital involvement about 5% [7]. In our case there were generalized involvements but spared mucosal areas. Systemic corticosteroid therapy is the treatment of choice in childhood BP [3]. Limited form of BP revealed with topical corticosteroid therapy. Aside from corticosteroid, sulfapyridine and dapsone have often been used in childhood BP as sole agents or in combination with corticosteroid, with variable success [7]. Zinman and et al. compared rate of response in treatment with systemic steroids response rate is 85%, with dapsone 25%, sulfapyridine 13% and mycophenolate mofetil 6% [7]. The disease has a good prognosis and remission is achieved within several weeks to a few months [7].

BP should be in mind when a child with erythematous plaques, vesicles and blisters on the palm, soles and body. Childhood BP is similar to adult BP but differs in some features such as palm, soles, mucosal and genital involvement. Treatment may include local and systemic steroid with or without combination with dapsone, sulfapyridine and mycophenolate mofetil.

### References

1. Fisler RE, Saeb M, Liang MG, Howard RM, McKee PH. Childhood bullous pemphigoid: a clinicopathologic study and review of the literature. *Am J Dermatopathol* 2003; 25: 183-189. PMID: 12775979
2. Chimanovitch I, Hamm H, Georgi M, et al. Bullous pemphigoid of childhood: autoantibodies target the same epitopes within the NC16A domain of BP180 as autoantibodies in bullous pemphigoid of adulthood. *Arch Dermatol* 2000; 136: 527-532. PMID: 10768652
3. Nemeth AJ, Klein AD, Gould EW, Schachner LA. Childhood bullous pemphigoid. Clinical and immunologic features, treatment, and prognosis. *Arch Dermatol* 1991; 127: 378-386. PMID: 1998369

4. Weston WL, Morelli JG, Huff JC. Misdiagnosis, treatments, and outcomes in the immunobullous diseases in children. *Pediatr Dermatol* 1997; 14: 264-272. PMID: 9263305
5. Amos B, Deng JS, Flynn K, Suarez S. Bullous pemphigoid in infancy: case report and literature review. *Pediatr Dermatol* 1998; 15: 108-111. PMID: 9572692
6. Sáenz AM, González F, Cirocco A, Tacaronte IM, Fajardo JE, Calebotta A. Childhood bullous pemphigoid: a case report and 10-year follow up. *Int J Dermatol* 2007; 46: 508-510. PMID: 17472685
7. Waisbourd-Zinman O, Ben-Amitai D, Cohen AD, et al . Bullous pemphigoid in infancy: Clinical and epidemiologic characteristics. *J Am Acad Dermatol* 2008; 58: 41-48. PMID: 17945382
8. Erbagci Z. Childhood bullous pemphigoid following hepatitis B immunization. *J Dermatol* 2002; 29: 781-785. PMID: 12532044
9. Baykal C, Okan G, Sarica R. Childhood bullous pemphigoid developed after the first vaccination. *J Am Acad Dermatol* 2001; 44: 348-350. PMID: 11174412
10. Mallory SB, Bree A, Chern P. *Illustrated Manual of Pediatric Dermatology Diagnosis and Management* First edition 2005; 85-86.
11. Oranje AP, Van Joost T. Pemphigoid in children. *Pediatr Dermatol* 1989; 6: 267-274. PMID: 2694126
12. Nemeth AJ, Klein AD, Gould EW, Schachner LA. Childhood bullous pemphigoid. Clinical and immunologic features, treatment, and prognosis. *Arch Dermatol* 1991; 127: 378-386. PMID: 1998369
13. Kawachi Y, Otsuka F. Eosinophil-colony stimulating activity in blister fluid of bullous pemphigoid. *J Dermatol Sci* 1997; 15: 51-54. PMID: 9186812