

## Two Cases with Vesicular Pityriasis Rosea

Serap Güneş Bilgili,\* MD, Ayşe Serap Karadağ, MD, Ömer Çalka, MD,  
Gülçin Güler Şimşek,<sup>1</sup> MD

Address: Yüzüncü Yıl University, Faculty of Medicine, Department of Dermatology, Van, Turkey and <sup>1</sup>Ankara Keçiören Research and Training Hospital, Department of Pathology, Ankara, Turkey

E-mail: drserapgunes@yahoo.com

\* Corresponding Author: Serap Güneş Bilgili MD; Assistant Professor, Department of Dermatology, Yüzüncü Yıl University, Faculty of Medicine, Van, Turkey

Published:

J Turk Acad Dermatol 2012; 6 (4): 1264c1

This article is available from: <http://www.jtad.org/2012/4/jtad1264c1.pdf>

**Key Words:** Pityriasis rosea; vesicular pityriasis rosea; varicella.

### Abstract

**Observation:** Pityriasis rosea (PR) is a self-limited, mild, inflammatory skin disease characterized by scaly lesions, possibly due to an unidentified infectious agent. It may occur at any age, but is seen most frequently in young adults. Many atypical forms of the disease have been reported in the literature. Typical PR is much easier to diagnose than the rare atypical forms. Herein we presented two male patients diagnosed as vesicular PR.

### Introduction

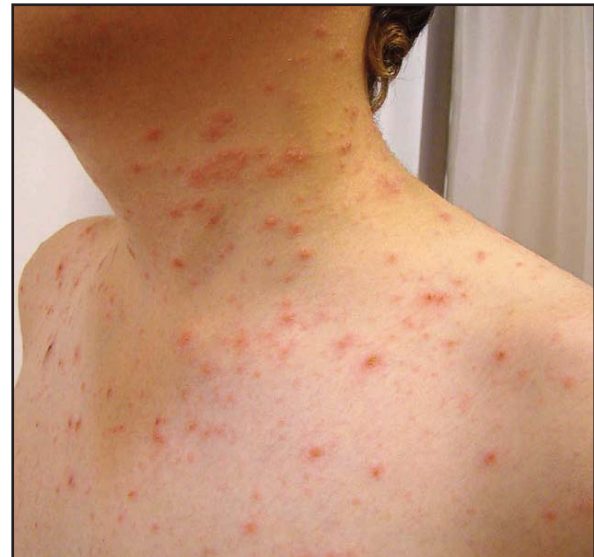Pityriasis rosea (PR) is an acute and self limited dermatosis usually localized in the proximal part of the trunk and extremities parallelly to skin clivages, characterized with oval, erythematous plaques [1]. Etiology of the disease is not known. Infectious agents, atopic background and autoimmunity have been suggested in development of the disease however it is not clear [1, 2]. Making a diagnosis is easy in typical forms of the disease however it may be difficult in atypical forms.

Two patients who had widespread vesicles in the trunk and diagnosed as PR clinically and histopathologically are reported due to rarity of vesicular variant.

### Case Reports

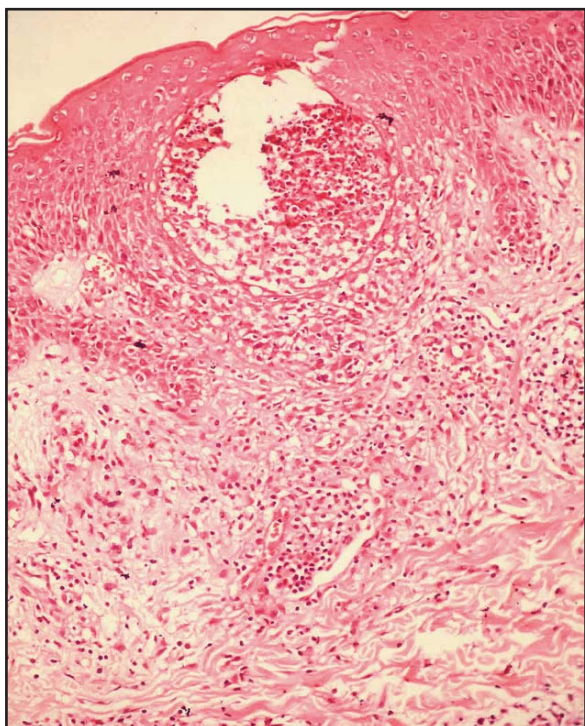
#### Case 1

Fifteen years old male patient was admitted to our clinic with complaint of itching, red rashes and ve-



**Figure 1.** Erythematous papulosquamous lesions, intact vesicular lesions and few ruptured vesicles on the neck and trunk

sicles appeared approximately 5 days ago in the anterior and posterior side of the trunk, thighs and palms of the hands. His general condition was well



**Figure 2.** There is spongiosis and intraepidermal vesicle formation (200 x H&E)

and he was afebrile. All lesions were learned to begin concurrently and spreaded gradually. He had no history of infections or drug use prior to emergence of the lesions. Other physical examination findings were normal. On his dermatologic examination, multiple vesicles and excoriations were detected besides erythematous papulosquamous eruptions. Oral mucosa was not involved. A few vesicles were seen also in palmoplantar region of the patient (**Figure 1**). Hemogram, routine biochemical parameters, urinary examination, C-reactive protein, erythrocyte sedimentation rate, ASO (antistreptolysin O) titer were in normal ranges. Throat culture, IgM and IgG for varicella, VDRL and TPHA were negative.

Histopathologic examination of the biopsy material taken from the lesions on the trunk and palms showed that spongiosis, minimal acanthosis and focal parakeratosis in the epidermis, dyskeratotic eosinophilic keratinocytes, mononuclear inflammation and rare eosinophil and histiocytes and, extravasated erythrocytes in the upper dermis (**Figure 2**). Periodic acid schiff stain and native preparation were negative. The patient was diagnosed as PR based on the clinical and histopathological findings.

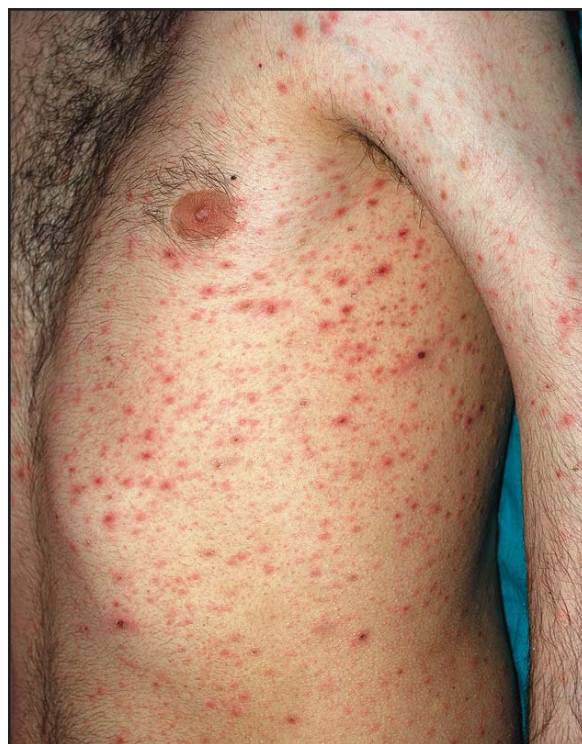Intramuscular corticosteroid injection (triamcinolone acetate) was done as the lesions did not regress

with topical corticosteroid and oral antihistamine treatment and the lesions were seen to regress within five weeks with parenteral treatment.

### Case 2

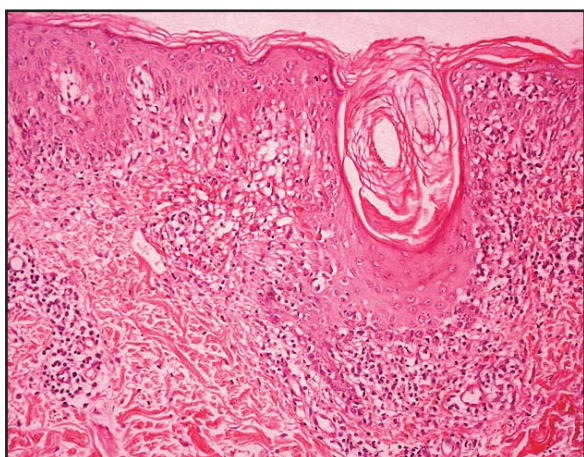
Twenty one-year-old male patient was admitted to our clinic with itching red rashes and vesicles in the anterior and posterior sides of the trunk, in both arms and legs. General condition of the patient was well and he was afebrile. Lesions were learned to begin on the trunk and gradually spreaded to arms and legs. There was no history of infection or drug use prior to emergence of the lesions. There were no family members with similar complaints. Other physical examination findings were normal. On his dermatologic examination, there were erythematous, hemorrhagic crusted papules and vesicles 3-5 mm in diameter mainly on the trunk and neck, both upper and lower extremities (**Figure 3**). There was no sign of a herald patch, and mucosal examination was normal.

Hemogram, routine biochemical parameters, urinary examination, C reactive protein, erythrocyte sedimentation rate were normal. Histopathologic examination of the skin biopsy taken from the trunk of the patient revealed basket orthokeratosis



**Figure 3.** Erythematous, hemorrhagic crusted papules and vesicles on the trunk and arm

including focal parakeratosis and neutrophilic microabscess foci, follicular plugging, thinning and localized loss in granular layer, lymphocyte exocytosis and necrotic keratinocytes, mild acanthosis, mild spongiosis and one spongiotic vesicle formation in epidermis, vacuolar degeneration, destruction and mild pigmentation increase in basal layer, edema, melanin pigment incontinence and melanophages in epidermis, perivascular mixed type inflammation and sparse extravasated erythrocytes in dermis consistently with PR (Figure 4).



**Figure 4.** Mild spongiosis and spongiotic vesicle formation in epidermis (200 x H&E)

Lesions completely regressed within a couple of months with topical corticosteroids and oral antihistamines.

## Discussion

Classical PR lesions are characterized with characteristic lesions localized parallelly to skin clivages and medallion shaped plaques however atypical forms may be difficult to diagnose. Atypical PR cases form 20% of all PR cases [3, 4].

Atypical forms are classified as cephalic PR, inverse PR, unilateral PR, localized PR and Vidal's pityriasis circinate et marginate according to distribution of the lesions and as generalized papular PR, purpuric (hemorrhagic) PR, pustular and vesicular variants according to its morphology [1, 4, 5].

Vesicular PR is mainly seen in children and young adults. Vesicular lesions may be generalized, on the face and mimic varicella. Sometimes it may mimic dyshidrosis being located on only hands and feet [4]. However generally

classical PR lesions may accompany. There were mildly erythematous and squamous lesions although medallion shaped plaques were not present in both cases. However appearance of the lesions was mimicking varicella primarily.

On histopathologic examination, subacute or chronic dermatitis, focal parakeratosis, mild acanthosis, spongiosis and mononuclear cell infiltration in epidermis are seen [1, 2, 3]. Severe spongiosis, exocytosis and intraepidermal vesicles are seen in vesicular lesions. Histopathologic examination of PR is not specific however may be beneficial for diagnosing atypical variants [1, 4].

Clinical appearance is usually adequate for making a diagnosis in typical forms of PR. Other papulosquamous diseases, secondary syphilis, guttate psoriasis, erythema dyschromicum perstans, lichen planus, nummular eczema, parapsoriasis (pityriasis lichenoides chronica), pityriasis alba, seborrheic dermatitis, tinea corporis and tinea versicolor, drug eruptions and viral exanthems are the diseases that should be taken into consideration in differential diagnosis [1, 2].

PR is not always needed to treat as it is a self limited disease, preventing itching and patient education are quite important [1]. Antihistamines may be administered for prevention of itching. Short acting systemic corticosteroids, UVB, oral erythromycin, doxycycline are the other drugs that have been tried and found satisfactory for treatment [1, 2, 4, 6].

In conclusion, PR may be presented with atypical forms and may be localized atypically. It should be kept in mind that vesicular form may be confused with many diseases like varicella infection.

## References

1. Gonzalez LM, Allen R, Janniger CK, Schwartz RA. Pityriasis rosea: An important papulosquamous disorder. *Int J Dermatol* 2005; 44: 757-764. PMID: 16135147
2. Parsons JM. Pityriasis rosea update. *J Am Acad Dermatol* 1986; 15: 159-167. PMID: 3528239
3. Traore A, Korsaga-Some N, Niamba P, Barro F, Sanou I, Drabo YJ. Pityriasis rosea in secondary schools in Ouagadougou, Burkina Faso. *Ann Dermatol Venereol* 2001; 128: 605-609. PMID: 11427793

4. Miranda SB, Lupi O, Lucas E. Vesicular pityriasis rosea: response to erythromycin treatment. J Eur Acad Dermatol Venereol 2004; 18: 622-655. PMID: 15324412
5. Polat M, Pelitli AÖ, Öztaş P, Gür G, Sevimli Dikicier B, Ercan H, Allı N. Palmoplantar tutulumu da olan pityriasis rosea. T Clin J Med Sci 2007; 27: 115-117.
6. Görpeliöglu C, Allı N, Erdal E, Uğurlu A. Pitiriazis roseada oral doksisisiklin ile topical mometazon furoat tedavisinin karşılaştırılması. T Klin Dermatol 2004; 14:128-131.