

Esophageal candidiasis in an immunocompetent child due to chronic gastroesophageal reflux: case report

Necati Balamtekin(*), Mustafa Gulgun(*), Sami Eksert(**)

ÖZET

İmmünkompetan olan bir adolesanda kronik gastroözefageal reflüye bağlı özefageal kandidiazis: olgu sunumu

Özefageal kandidiazis, immünitesi normal olan çocuklarda çok nadir bir durumdur. Biz burada, kronik gastroözefageal reflüye bağlı özefageal kandidiazis tanısı konan 13 yaşında erkek bir hasta sunduk. Hekimler, adolesanlarda kronik gastroözefageal reflünün nadir bir komplikasyonu olarak özefageal kandidiazis olabileceğinin farkında olmalıdırlar.

Anahtar Kelimeler: özefageal kandidiazis, gastroözefageal reflü, adolesan.

SUMMARY

Esophageal candidiasis is very rare in immunocompetent children. Here in, we presented an 13 year-old-boy with diagnosed as esophageal candidiasis due to chronic gastroesophageal reflux. Physicians should be aware of the possibility of esophageal candidiasis as a uncommon complication of chronic gastroesophageal reflux in adolescents.

Key words: esophageal candidiasis, gastroesophageal reflux, adolescent.

Introduction

Infections of the esophagus are rare and usually occur in immunocompromised patients. Fungus, herpes simplex virüs, and cytomegalovirus are frequently seen causative agents for esophageal infections. Among fungus, *Candida* species, especially *Candida albicans* and less frequently *Candida tropicalis*, *Candida krusei*, *Candida stellatoidea*, are usually the cause of fungal esophagitis (1).

Although esophageal candidiasis is rare, it is common in immunosuppressive children during malignancy, chemotherapy, chronic or some infectious diseases and in children on long-term antibiotic treatment (2). Herein, we described an adolescent with diagnosed as esophageal candidiasis due to chronic gastroesophageal reflux.

Case

A 13-year-old girl was presented with epigastric pain for 5 years. Although she told us getting well her symptoms a little with antacids, she has not been completely improved with antacids for 6 months. No history of any drug except antacids was found. Physical examination was normal. Laboratory studies including complete blood count, liver and kidney function tests, erythrocyte sedimentation rate were within normal limits. There was no blood in the stool. The abdominal ultrasound imaging was normal. Her immune system evaluation was normal. The 24-hour pH monitorization showed a moderate gastroesophageal reflux. The gastrointestinal endoscopy revealed exudate, obvious mucosal erythema and early ulceration in the mucosa (Figure 1). Histopathology corrected the diagnosis as candidiasis. Hyphae was detected with potassium hydroxide, and both hyphae and yeasts in the hyperkeratotic squamous epithelium of the esophagus were shown by Hematoxylin and eosin staining. *Helicobacter pylori* were not found in the histopathologic examination. The treatment of alginic acid oral suspension (4x10-20 ml), lansoprazole oral tablet (1x30 mg) and nystatin oral suspension (4x500.000 units) was started. On the 4th week of treatment, she was completely well and symptom-free and had no lesion in her gastrointestinal endoscopy.

Discussion

As with most fungal infections, candidal infections usually occur due to a defect in the host immune defense mechanisms such as damaged mucocutaneous barriers (wound, burns, ulcerations), granulocytopenia, chronic granulomatous disease, myeloperoxidase deficiency, hypocomplementemia, hypogammaglobulinemia, usage of immunosuppressive drugs, HIV infection, impaired mucocutaneous protective bacterial flora. Any condition affecting functions of the immune system as mentioned above are significant risk factors for fungal diseases. In our case, it is possible that the esophageal candidiasis

*Gülhane Medical Faculty, Department of Pediatrics, Ankara/Turkey.

**Gülhane Medical Faculty, Department of Anesthesiology, Ankara/Turkey

Ayrı Basım İsteği: Mustafa Gülgün
Gülhane Medical Faculty, Department of Pediatrics, Ankara/Turkey.
(mustafagulgun@yahoo.com)

Malakalenin Geliş Tarihi: Sep 08, 2014 • Kabul Tarihi: Nov 01, 2015 • Çevrim İçi Basım Tarihi: 30 Eylül 2016

occurred because of the altered mucosal integrity which is a part of innate defense system by the chronic gastric reflux over time (1).

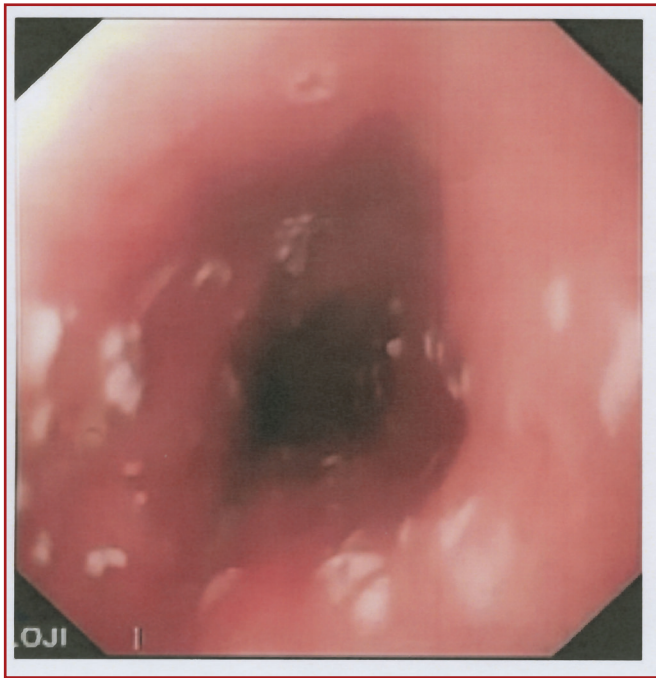


Figure 1. Whitish pseudo-membranes and erosions in esophagus by endoscopic examination

Esophageal candidiasis without underlying disease are not common. Simon et al. (3) reported an adult case with asthma complicated with esophageal candidiasis due to inhaled steroid treatment. Sood et al. (4) presented two case with esophageal candidiasis following omeprazole therapy. To the best of our knowledge, this is the first case with esophageal candidiasis due to chronic gastroesophageal reflux. It may be resulted from susceptibility to fungus due to chronic irritation via gastric ingredient.

In addition, esophageal candidiasis is not so innocent clini-

cal entity. Kimura et al. (5) determined a 74 years-old patient with esophageal candidiasis resulting in esophageal stricture despite antifungal treatment.

The treatment of esophageal candidiasis includes precautions and antifungal treatments. First, all the possible risk factors, such as immunosuppressives should be minimized. Antifungal therapy for esophageal candidiasis can be divided into topical treatment with nystatin, clotrimazole, and miconazole and oral or parenteral treatment with fluconazole, flucytosine, itraconazole, and amphotericin B. The topical approach is not effective in the esophageal candidiasis and oral or parenteral fluconazole is the preferred treatment (1). We administered oral antifungal treatment for esophageal candidiasis in our case.

Although esophageal candidiasis is very uncommon in immunocompetent children, it should be in mind that esophageal candidiasis may be seen as a rare complication of chronic gastroesophageal reflux in immunocompetent adolescents.

References

1. Kang HR, Kwon YH, Kim YJ. A case of esophageal candidiasis in an adolescent who had frequently received budesonide nebulizing therapy. *Pediatr Gastroenterol Hepatol Nutr.* 2013; 16: 185-9.
2. Hasosah MY, Showail M, Al-Sahafi A, Satti M, Jacobson K. Esophageal candidiasis in an immunocompetent girl. *World J Pediatr.* 2009; 5: 152-4.
3. Simon MR, Houser WL, Smith KA, Long PM. Esophageal candidiasis as a complication of inhaled corticosteroids. *Ann Allergy Asthma Immunol.* 1997; 79: 333-8.
4. Sood A, Sharma M, Jain NP, Chawla LS, Kumar R. Esophageal candidiasis following omeprazole therapy: a report of two cases. *Indian J Gastroenterol.* 1995; 14: 71-2.
5. Kimura H, Kurachi M, Tsukioka Y, Minami M, Itou M, Fujii H, Nakanishi K. Esophageal stricture secondary to candidiasis without underlying disease. *JGastroenterol.* 1995; 30: 508-11.