

Bypassing the cuffing effect in adult hypospadias surgery diversion

Hasan KOCOĞLU (*), Bilal Fırat ALP (**), Ercan MALKOÇ (***), Sami UGUZ (****)

SUMMARY

Urethral stents are frequently used for urinary diversion after hypospadias surgery. In this study, we aim to compare the results of no-balloon catheter (nelaton catheter) and modified foley catheter usage after TIPU operations in adults.

The medical records of 53 adult patients who applied TIPU for subcoronal or midpenile hypospadias between November 2008 and September 2012 were evaluated retrospectively. Patients were evaluated in two groups based on the performed urinary diversion. Group 1 was composed of 29 patients to whom 16 F nelaton catheter was used for urinary diversion between November 2008-December 2010, whereas Group 2 consisted of 24 patients to whom 12 F foley catheter coated by 16 F nelaton catheter by half was used for urinary diversion between February 2011 – September 2012.

There was no statistically significant difference between Group 1 and Group 2 in terms of age, the location of the meatus, the number of secondary cases, the length of the neourethra, fistula and urethral stricture ($p>0.05$). Surgery success rate was 79.3% in Group 1 and 79.1% in Group 2 ($p>0.05$). At the 6th month follow-up, no statistically significant difference was found between two groups regarding fistula and urethral stricture. In terms of postoperative patient comfort, Group 2 were better than Group 1 ($p<0.05$).

Twelve F foley catheter, half of which is coated with 16 F nelaton catheter, could be used for diversion in TIPU operations in adult patients with distal and mid-shaft penile hypospadias to reduce postoperative patient discomfort.

Key words: Cuffing effect, Foley, Adult Hypospadias

Introduction

Hypospadias is believed to result from arrested penile development, leaving a proximal urethral meatus (1). The incidence of hypospadias is 1/300 in male children (2). But there is an increase of its incidence with considerable variation in different countries (3). Various surgical procedures have been described to correct this congenital condition. Since its introduction in 1994 by Snodgrass (4), the tubularized incised-plate urethroplasty (TIPU), a modification of the Thiersch-Duplay technique, has become a very popular repair for hypospadias; it is associated with very good functional and cosmetic results (5,6,7). Almost all the current published studies on TIPU encompassed pediatric series and are usually treated before school age in developed countries. However, in developing countries it is not uncommon for adults to present with hypospadias that has not been treated in childhood (7,8). Although the studies of stent-free repair using the TIPU presents excellent results (9-12), urethral stenting following hypospadias surgery offers some advantages: avoidance of obstruction secondary to postoperative edema; supporting repair and achieving urinary drainage; and prevention of leakage through suture lines with forceful urination (13).

Urethral stents are frequently used for urinary diversion after hypospadias surgery. The foley catheter is not generally preferred, for the formation of a 'cuff' on deflation of the balloon of all foley catheters that causes difficulty in removal (cuffing effect of balloon). Problems with catheter removal cause discomfort to the patient, with the risk of urethral trauma leading to stricture formation (14,15). In the literature, there is not comprehensive study on the usage of foley catheter for adult hypospadias surgery. We have recently been using the modified foley catheter that we designed in our patients.

In this study, we aim to compare the results of no-balloon catheter (nelaton catheter) and modified foley catheter usage after TIPU operations in adults.

Patients and methods

The medical records of 53 patients who applied TIPU for subcoronal or midpenile hypospadias between November 2008 and September 2012 were evaluated retrospectively. The patients who underwent hypospadias surgery more than twice, those who did not have a urethral plate of sufficient width; those with proximal hypospadias; those with chordees (except minimal chordees) and those who did not come to the follow-ups in the first six month were excluded from the study. Patients were evaluated in two groups based on the performed urinary diversion. Group 1 was composed of 29 patients to whom 16 F nelaton catheter was used for urinary

*Gölcük Military Hospital, Department of Urology

**Gülhane Military Medical Academy, Military Medicine Faculty Department of Urology

*** Corlu Military Hospital, Department of Urology

**** Agri Military Hospital, Department of Urology

Reprint request: Hasan Kocoglu
Gölcük Military Hospital, Department of Urology
e-mail: perkutanci@yahoo.com

Makalenin Geliş Tarihi: Dec 13, 2013 • **Kabul Tarihi:** Mar 14, 2014 • **Çevrim İçi Basım Tarihi:** 30 Haziran 2015

diversion between November 2008-December 2010, whereas Group 2 consisted of 24 patients to whom 12 F foley catheter coated by 16 F nelaton catheter by half was used for urinary diversion between February 2011 – September 2012.

Preparation of the coated foley catheter: We vertically cut the nelaton piece that we obtained by dividing the 16 F nelaton catheter into two. Subsequently, we coated the half of the 12 F foley catheter with the 16 F nelaton piece (Figure 1). The half of one end of the new catheter we derived had a thickness of 12 F, while the half of the other end passing through the urethral scar line was 16 F thick. We determined that, at the end of one week after inflating the catheter balloon by 7-10 ml, the thickness of the balloon cuff was not more than 16 F (Figure 2).

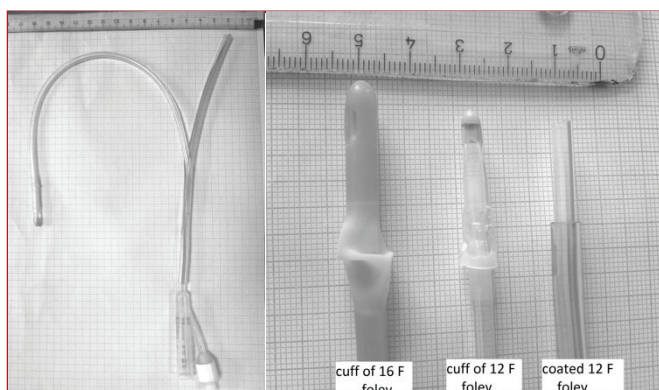


Figure 1. Coated 12 F foley catheter with the 16 F nelaton piece Figure 2. Comparison of cuff of 16 F foley, cuff of 12 F foley and coated 12 F foley

The TIPU surgery was performed under spinal anesthesia as explained by Snodgrass. The penis was degloved. During degloving the penis, special care was taken to create good vascularized pedicle. After dividing the urethral plate in the midline, new urethra was formed with subepithelial transitive running suture technique, where 5/0 polyglactin suture was used. The length of the new urethra formed was noted for each patient. In the formation of the new urethra, nelaton or coated catheter, which would remain on the patient after the operation, was used. The patient was not catheterized again after the formation of the new urethra. In this way, we abstained from a trauma that might have been developed on the suture line of the new urethra. The suture line of the new urethra was closed with good vascularized pedicle. Bleeding controls were held with 5/0 polyglactin suture. Electrocauterisation never used for bleeding. In the patients that nelaton was used, catheter was fixed to the glans penis by 3/0 silk suture. At the end of the operation, penis was taped semi-tightly with gummy bandage (Coban). Urinary diversion was performed for 7 days for every patient. All patients were given oral antibiotics (second generation cephalosporin). In order to reduce the bladder contraction in those who had urine leakage at the edge of the catheter, 4 mg tolteradine was given until the termination of the diversion.

The patients were called for follow-up at the 1st, 3rd and 6th month of the first year. Patients who did not have any complication were called for follow up once a year after then. In the follow-up examination, patients were examined for urination complaints, the outlook of the urethral meatus and urethrocutaneous fistula formation. In order to detect the urethral stricture, urethral calibration was performed with 14 F nelaton after

lubrication with lidocaine gel at the 6th month. Patients were evaluated in 8th day for urinary diversion derived distresses. These distresses were reviewed under three headings; 1- Urine leakage at the edge of the catheter, 2- Mobilization of a portion of the catheter out of the urethra and catheter not being able to drain the bladder, 3- Severe pain during morning erections. At the 8th day when urinary diversion was finalized, the existency of urethrocutaneous fistula formation was checked and the suture line was examined to detect whether it is detached or not. At the 6th month follow-up, patients were evaluated in respect to urethrocutaneous fistula existency and urethral stricture development. Statistical comparison of the success rates in Group 1 and Group 2 was evaluated by chi-square test. The p values < 0.05 were considered significant.

Results

There was 29 patients in Group 1 with a mean age 21.4 years. Urinary diversion was performed with nelaton catheter fixed to the glans penis. Twenty four of the cases were primary and 5 were secondary in this group. External urethral meatus were located subcoronal in 22 patients and midpenil in 7.

The mean age of the 24 patients in Group 2 were 22.5 and urinary diversion was performed with coated foley catheter. The number of primary and secondary cases in this group was 20 and 4, respectively. External urethral meatus were located subcoronal in 19 and midpenil in 5 patients. There was no statistically significant difference between Group 1 and Group 2 in terms of age, the location of the meatus, the number of secondary cases, the length of the neourethra, fistula and urethral stricture (p>0.05) (Table 1).

Table 1: The comparison of the patients in Group 1 and Group 2

	Group 1 (29)	Group 2 (24)	p
Age	21.4 (20-28)	22.5 (20-32)	>0.05
Follow-up	15.2 months (6 months -2.5 years)	12.4 months (6 months -2.2 years)	>0.05
Number of secondary cases	5 (17.2%)	4 (16.6%)	>0.05
Meatus localization	SC=22, MP=7	SC=19, MP=5	>0.05, >0.05
The length of neourethra	20.6 mm (16-35)	21.9 mm (14-38)	>0.05

SC: subcoronal, MP: midpenil

The detachment of neourethra was assessed in 2 patients in Group 1 and 1 in Group 2. These patients were not included in the statistical evaluation held in the 6th month. When both fistula formation at the 8th day and scar line detachment were

Table 2: The results of the patients at the 8th day postoperatively

	Group 1 (29)	Group 2 (24)	p
Fistula at the 8th day	4 (13.7%)	4 (16.6%)	>0.05
Detachment of suture lines	2 (6.8%)	1 (4.1%)	>0.05
Surgery success	79.3%	79.1%	>0.05

taken into consideration together, success rate was 79.3% in Group 1 and 79.1% in Group 2 that was not statistically significant (Table 2). At the 6th month follow-up, no statistically significant difference was found between two groups regarding fistula and urethral stricture (Table 3).

Table 3: The results of the patients at the 6th month post-operatively

Number of patients	Group 1 (27)	Group 2 (23)	p
Urethral fistula	4 (14.8%)	3 (13.04%)	>0.05
Urethral stricture	3 (11.1%)	2 (8.6%)	>0.05

Table 4: Complaints associated with diversion

Number of patients	Group 1 (29)	Group 2 (24)	P
Urine leakage at the edge of the catheter	20 (68.9%)	2 (8.3%)	0.0001
Mobilization of a portion of the catheter out of the urethra	9 (31%)	1 (4.1%)	0.0001
Severe pain during morning erections	21 (72.4%)	3 (12.5%)	0.0001

With respect to problems emerged in association with urinary diversion, Group 2 were better than Group 1 in the first 7 day following the operation (Table 4). In terms of the response to 4 mg tolteradine which was given to reduce the bladder contraction in those who had urine leakage at the edge of the catheter, 7 out of 20 patients in Group 1 and 1 out of 2 patients in Group 2 revealed partial response. Complete dryness could not be achieved in any of the patients given tolteradine treatment.

Discussion

Hypospadias is a congenital anomaly in which urethral meatus opens proximal and ventral to the glans penis. More than 200 operations have been described for reducing the complication rate subsequent to the surgical procedure (16). The presence of chordee, quality of the urethral plate, experience of the surgeon, use of urinary diversion and dressing are very important for surgical success (13,17).

In order to overcome fistula and detachment of suture lines that urine might cause, urinary diversion is performed in hypospadias surgeries (18). Snodgrass had used intraurethral stent for urinary diversion in TIPU operations (4). Recently, successful stent-free hypospadias surgery was reported in pediatric patients with distal and midpenil hypospadias (9-12).

According to the literature, there is no study on stent-free TIPU practice in adult patients with distal and midpenil hypospadias. In adult patients, mostly suprapubic or transurethral catheter is have been used for diversion (7, 8, 19-21). Nelaton catheter is generally preferred as a transurethral catheter however foley catheter has been used in selected patients. In our previous clinical practice, we had used transurethral nelaton catheter for diversion with distal and midpenil hypospadias in TIPU operations (Group 1). The most common complaints

were urine leakage at the edge of the catheter, insufficient drainage of the bladder due to the mobilization of a portion of the catheter out of the urethra and severe pain during morning erections. In order to reduce the aforementioned complaints during the period that the patient had a stent, we decided to use 16 F foley catheter. Between December 2010 – February 2011, we used 16 F foley catheter in 7 patients. In 4 patients, catheter was hooked up while taking out or catheter was removed hardly. In 2 patients out of these 4, urethral fistula was developed. Considering that, such drawbacks might be avoided if the cuff of the catheter has a thickness less than 16 F though we modified the 12 F foley catheter. We realized that patients, to whom we used modified catheter, had a relatively more comfortable time postoperatively.

For the patient group as the one in our study, we have not encountered another study in the literature, which presents the complaints of the patients, to whom no balloon catheter was used during the period they had stent postoperatively. In the same patient group, we neither found a study that reports problems occurred due to foley catheter balloon cuff.

In pediatric patients, indwelling foley catheters post hypospadias repair have been associated with significant postoperative discomfort and stent-related (cuffing effect of balloon) complications (9-12, 22-26). Cuffing effect does not only cause hard and painful removal of the catheter, but also may lead to disruption of the repair (12). To avoid the occurrence of cuffing effect of balloon in pediatric patients, the 5 ml balloon of the pediatric catheter is recommended to be inflated by 2 ml at maximum (27). Although the author suggests that the inflation of the balloon by 2 ml may prevent premature removal of the catheter in pediatric patients, we believe that this proposal should be verified by further studies. Using urethral stents without a balloon requires an anchoring suture at the glans, resulting in possible traction pain during daily care of the catheter and the need for further special care to avoid inadvertent slippage (12). These problems observed in pediatric patients were also seen in a high rate in our Group 1 patients. In adult patients, pain during morning erections was the main factor disturbing the patient comfort most.

Snodgrass has recommended stent placement for about a week (4). In addition, it has been shown that urethral stent usage for more than 12-14 days in patients who underwent deep plate incision is not beneficial in the avoidance of complication development (28). Although there has been no data reported on the stent usage period for adult patients, general approach on the period for stent usage is 7-10 days.

In our series, the complication rates of urethral fistula and urethral stricture occurrence were similar to other studies (7,8, 19-21). Although urethral fistula and urethral stricture development rates seem to be lower in the group of patients that we used the coated foley catheter, no statistically significant difference was detected. Nonetheless, the patient comfort was statistically improved in Group 2.

There were several limitations in this study. As a retrospective study, the evidence was not as strong as that in a prospective randomized trial. However, we believe that the results of our study would give hints for future prospective studies.

Conclusion

Based on our preliminary experiences, we conclude that 12 F foley catheter, half of which is coated with 16 F nelaton catheter, could be used for diversion in TIPU operations in

adult patients with distal and mid-shaft penile hypospadias to reduce postoperative patient discomfort. Further randomized multicenter studies are required to verify our data.

References

1. Warren T. Snodgrass. Campbell's Urology , 10th edn, Chapt 130, p:3503
2. Beck C: Hypospadias and its treatment. Surg Gynecol Obstet 1917; 24:511-532.
3. Thomas DFM. Hypospadiology: science and surgery. BJU Int 2004;93:470-3.
4. Snodgrass W. Tubularized, incised plate urethroplasty for distal hypospadias. J Urol 1994;151.
5. Duplay S (1880) Sur le traitement chimrgical de l'hypospadias et de l'epispadias. Arch Gen Med 145:257,
6. Zaontz MR. Thiersch-Duplay procedure. In Ehrlich RM, Alter GJ eds. Reconstructive and Plastic Surgery of the ExternalGenitalia. Adult and Pediatric Urology.1st edn. Chapt. 10. Philadelphia: WB Saunders, 1999: 48-53
7. Sharma G. Tubularized-incised plate urethroplasty in adults. BJU International 2005; 95 , 374 – 376
8. Senkul T, Karademir K, Işeri Cn, Erden Do, Baykal K, Adayener Cn.Hypospadias in adults. Urology. 2002 Dec;60(6):1059-62
9. Minevich E , Pecha BR , Wacksman J et al . Mathieu hypospadias repair: experience in 202 patients . J Urol 1999 ; 162 (6) : 2141 – 2142 ; discussion 2142 – 2143
10. Leclair MD , Camby C , Battisti S et al . Unstented tubularized incisedplate urethroplasty combined with foreskin reconstruction for distal hypospadias . Eur Urol 2004 ; 46 (4) : 526 – 530
11. Almodhen F , Alzahrani A , Jednak R et al . Nonstented tubularized incised plate urethroplasty with Y-to-I spongioplasty in non-toilet trained children . Can Urol Assoc J 2008 ; 2 (2) : 110 – 114
12. S. Turial , J. Enders , V. Engel , F. Schier. Stent-Free Tubularized Incised Plate (TIP) Repair of Distal and Mid-Shaft Hypospadias Irrespective of Age. Eur J Pediatr Surg 2011; 21: 168 – 170
13. Paul C.Y. Chang, Ming-Lun Yeh,Chun-Chih Chao, Chi-Jen Chang. Use of Double Pigtail Stent in Hypospadias Surgery. Asian J Surg 2011;34(1):28-31
14. Parkin J, Scanlan J, Woolley M, Grover D, Evans A, Feneley RC. Urinary catheter 'deflation cuff' formation: clinical audit and quantitative in vitro analysis. BJU Int. 2002 Nov;90(7):666-71.
15. Edwards L, Trott PA. Catheter induced urethral inflammation. J Urol 1973; 110 : 678-81
16. Razool M, Sheikh AH, Tabassum SA, et al. Hypospadias Repair. Prof Med J 2007;14:677-84.
17. Woodhouse CRJ, Christie D. Nonsurgical factors in the success of hypospadias repair. BJU Int 2005;96:22-7.
18. McCormack M, Homsy Y, Laberge Y: "No stent, no diversion" Mathieu hypospadias repair. CJS 36: 152-154, 1993.
19. Sahin C, Seyhan T. Use of buccal mucosal grafts in hypospadias-crippled adult patients. Ann Plast Surg. 2003 Apr;50(4):382-6.
20. Adayener C, Akyol I. Distal Hypospadias Repair in Adults: The Results of 97 Cases. Urol Int 2006;76:247-251
21. Sahin C, Kalkan M , Toraman A.R . Hypospadias repair in the adult age as a public health problem: our experience in 112 cases. Turkish Journal of Urology 2010;36(4):405-410
22. Buson H , Smiley D , Reinberg Y et al . Distal hypospadias repair without stents: is it better? J Urol 1994 ; 151 (4) : 1059 – 1060
23. El-Sherbiny MT . Tubularized incised plate repair of distal hypospadias in toilet-trained children: should a stent be left? BJU Int 2003 ; 92 (9) : 1003 – 1005
24. Mustafa NA , Lope RJ , Cheah FC . Spontaneous knot formation impeding the removal of a silicone urethral catheter . Arch Dis Child Fetal Neonatal
25. Lodha A , Ly L , Brindle M et al . Intraurethral knot in a very-low-birthweight infant: radiological recognition, surgical management and prevention . Pediatr Radiol 2005 ; 35 (7) : 713 – 716
26. Mayer E , Ankem MK , Hartanto VH et al . Management of urethral catheter knot in a neonate . Can J Urol 2002 ; 9 (5) : 1649 – 1650
27. Hardwicke J , Jones E , Wilson-Jones N . Optimization of silicone urinary catheters for hypospadias repair . J Pediatr Urol 2010 ; 6 (4) : 385 – 388
28. Lorenz C , Schmedding A , Leutner A et al . Prolonged stenting does not prevent obstruction after TIP repair when the glans was deeply incised . Eur J Pediatr Surg 2004 ; 14 (5) : 322 – 327