

## Anomalous Pattern of Tendinous Slips of Peroneus Tertius and Extensor Digitorum Longus Muscles in the Foot- A Clinically Important Variation

Abhinitha P(\*), Mohandas Rao KG(\*), Ashutosh S Rao(\*\*), Satheesha Nayak B(\*), Surekha Shetty(\*)

### SUMMARY

The peroneus tertius (PT) is a small muscle with a small single tendon which gets inserted to the dorsal surface of the 5<sup>th</sup> metatarsal base. Normally, the tendon of extensor digitorum longus (EDL) muscle divides into 4 slips on the dorsum of the foot which go to the lateral 4 toes. Variations in the tendons of these muscles are very rare. We observed a case where the tendon of EDL divided into only 3 slips which were inserted into the 2<sup>nd</sup>, 3<sup>rd</sup> and 4<sup>th</sup> toes through dorsal digital expansion. The PT tendon was quite thick and it divided into 2 slips. The lateral slip was getting inserted to the dorsal surface of the 5<sup>th</sup> metatarsal base and medial slip was continuing on to the little toe to form the dorsal digital expansion. This variation was observed during routine dissection on the left lower limb of about 55 year old female cadaver. Such anomalies are important clinically to the treating surgeon, being a tendon of importance in normal function and surgeries of the foot. Functional significance and the clinical relevance of the variations are discussed.

**Key words:** muscle variation; extensor digitorum longus; peroneus tertius; dorsiflexion; eversion

### Introduction

The peroneus tertius (PT) is a small muscle which is unique to humans. It arises from the distal part of medial surface of the fibula. The peroneus tertius is often referred to be a part of the extensor digitorum longus tendon and as the fifth tendon of this muscle (1). The tendon of the muscle gets inserted to the dorsal surface of the 5<sup>th</sup> metatarsal base. A thin expansion usually extends forwards along the medial border of the shaft of the bone. It is a weak dorsiflexor and an evertor of the foot 1. The extensor digitorum longus (EDL) muscle arises mainly from the upper part of medial surface of the fibula. The muscle becomes tendinous in the lower one third of the leg and divides into 4 slips on dorsum of the foot to end in the dorsal digital expansion of the lateral 4 toes [1]. Tendons of the extensor digitorum longus to the second and fifth toes are sometimes duplicated, and accessory slips may be attached to metatarsals or to the hallux [1]. It is one of the muscles described as an "extensor" which is involved in dorsiflexion of the toes and the ankle [2]. An unusual pattern in the tendons of these muscles is reported and its clinical and surgical importance is discussed.

### Case Report

During routine dissection for the undergraduate medical students, we observed an abnormal pattern in the tendons of EDL and PT muscles in the dorsum of the foot. This unusual case was observed in the left lower limb of about 55 year old female cadaver during routine dissection for undergraduate medical students. Though the origin of these muscles looked normal, the fleshy belly of the EDL appeared smaller and that of PT looked larger than the normal. Both the muscles were supplied by the branches from the deep peroneal nerve. The major variation was observed in the pattern of tendon formation of these muscles.

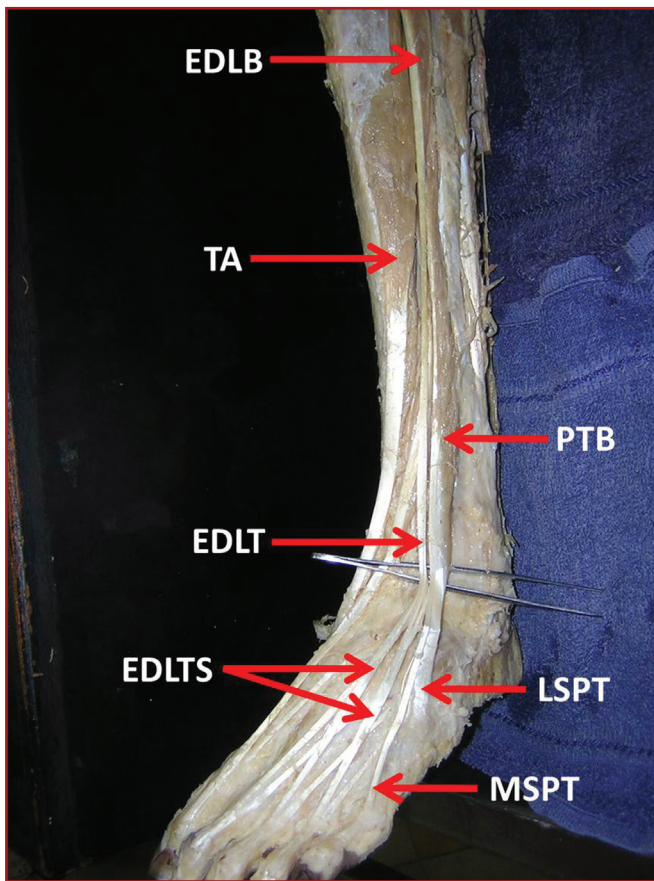
The tendon of EDL was unusually long and it divided into only 3 slips which were inserted into the 2<sup>nd</sup>, 3<sup>rd</sup> and 4<sup>th</sup> toes through dorsal digital expansion. The peroneus tertius tendon was quite thick and it divided into 2 slips. The lateral slip was inserted to the dorsal surface of the 5<sup>th</sup> metatarsal base and medial slip continued on to the little toe to form the dorsal digital expansion. In addition, the lateral slip of PT which was inserted into the dorsal surface of the 5<sup>th</sup> metatarsal base was receiving a thin fibrous slip from the EDL tendon [Figures 1 and 2].

\* Department of Anatomy, Melaka Manipal Medical College, Manipal University, Manipal, 576 104, India.

\*\* Department of Orthopedics, Faculty of Medicine, AIMST University, Semeling, Bedong-08100, Kedah, Malaysia.

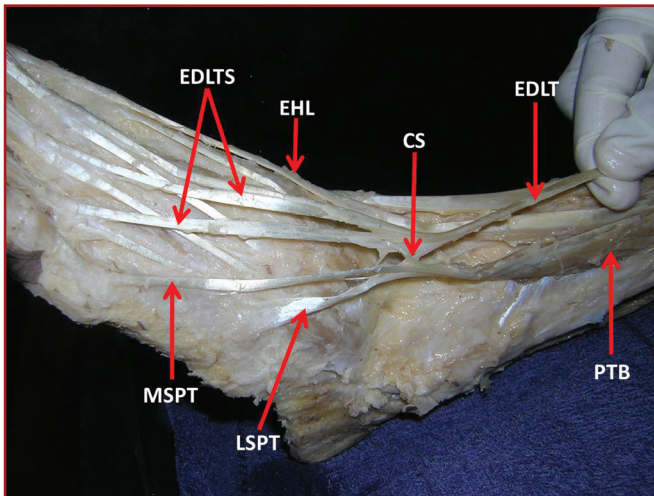
**Ayrı basım isteği:** Dr. Mohandas Rao K. G.  
Professor and Head  
Department of Anatomy  
Melaka Manipal Medical College (Manipal Campus),  
Manipal University,  
Manipal 576 104  
**Phone:** 91 984 438 08 39  
**Fax:** 91 820 2571905  
**E-mail:** mohandaskg@gmail.com

Date submitted: Feb 06, 2012 • Data accepted: Apr 23, 2012 • Online publication date: Sep 27, 2014



**Figure 1:** Dissection of the front of the leg and dorsum of the foot

The picture illustrates the muscles of the anterior compartment of the leg and tendons on the dorsum of the foot. It can be observed that extensor digitorum longus has a smaller belly (EDLB) and a long tendon (EDLT) which splits into only 3 slips on the dorsum of the foot (EDLTS). The peroneus tertius is having relatively larger belly (PTB) and a relatively thicker tendon which divides into a medial slip (MSPT) going to the 5<sup>th</sup> toe and a lateral slip (LSPT) getting inserted to 5<sup>th</sup> metatarsal base. (TA- tibialis anterior)



**Figure 2:** Dissection of the lower part of front of the leg and dorsum of the foot

The picture illustrates the muscles in the lower part of the anterior compartment of the leg and tendons on the dorsum of the foot. It can be observed that tendon of extensor digitorum longus (EDLT) splits into 3 slips on the dorsum of the foot (EDLTS) which go to the 2<sup>nd</sup>, 3<sup>rd</sup> and 4<sup>th</sup> toes and it also sends a connecting slip (CS) to the tendon of peroneus tertius. The peroneus tertius is having relatively larger belly (PTB) and a relatively thicker tendon which divides into a medial slip (MSPT) going to the 5<sup>th</sup> toe and a lateral slip (LSPT) getting inserted to 5<sup>th</sup> metatarsal base. (EHL- extensor hallucis longus)

Written informed consent could not be obtained from the subject's relatives as the origin of the cadaver was not known. However, an approval from the institutional ethical committee has been obtained for the publication of this case report.

## Discussion

Not many variations are reported about the tendon pattern of PT and EDL. Joshi et al. have reported a thicker PT tendon in 12% of cases compared to that of EDL. They also have reported abnormal insertion of PT in 5.5% of cases [3]. Origin of PT with 2 separate bellies and insertion with a common tendon is reported [4]. Taser et al., have reported a case where the PT was arising separately from fibula rather than as a slip from EDL [5]. Though the origin of the PT in these cases is somewhat similar to our observation, the insertion pattern of PT which we are reporting in the present case is unique. Abnormal origin of PT from the extensor hallucis longus has been reported [6]. Many reports of absence of PT are also available [3, 7, 8]. Considering these reports, it can be stated that PT tendon sending a slip to the fifth toe and receiving a fibrous slip from the EDL tendon is unique and has not been reported so far.

Variations in EDL tendons are less frequent compare to that of PT. An additional muscle and a tendon for the 2<sup>nd</sup> toe has been reported by Tezer and Cicekcibasi [9]. Absence of the of the extensor digitorum longus muscle tendon to the fourth toe in the right leg has been reported in a Japanese cadaver [10]. However, a case of absence of EDL tendon slip to the fifth toe and PT sending tendinous slip to the fifth toe is being reported for the first time.

According to Bhargava et al., frequency in the variations of attachments of leg muscles indicates that they have not yet reached their final stage of evolution [11]. Some of the muscles are still in the process of evolution, they are either degenerating like the plantaris or are appearing like the peroneus tertius. Extensor muscles of the leg are found in the human embryo early in its development. Peroneus tertius is considered as a separated part of EDL. Hence the variations in the insertion of these muscles may be either due to evolutionary factors or due to abnormal separation of PT from EDL.

## Clinical Importance:

Peroneus tertius muscle, when present, has been studied to be an equally sensitive and more specific indicator than the abductor hallucis in the diagnosis of mild length-dependent peripheral neuropathy, especially when more proximal muscles are not involved [12]. When the muscle is more muscular than normal and has an added insertion laterally (on to the lateral digit) as in the present case, it may be possible that in such individuals, it may lead to more evertor activities and become responsible for deformities or symptoms related to or of the foot. The peroneus tertius muscle has also been blamed as a possible cause for stress fractures of the base of the 5<sup>th</sup> metatarsal [7]. Again, this possibility increases in cases where the muscle is bulky and large. In a report by Sammarco, the peroneus tertius has been cited as a cause for snapping ankle [13]. PT has been also reliably and commonly used in local transposition flaps in the lower extremities [4]. The peroneal muscle and its relation to the superficial nerve is also of prime importance in placement of anterolateral portal in ankle arthroscopy to avoid inadvertent neuromuscular injuries [4]. In animal models, the PT has been observed to undergo more

fibrosis during distraction osteogenesis of the lower limb leading to deformities. With increased bulk of the muscle and additional insertions, the surgeon has to consider this to cause such deformities [14].

The EDL is a significant muscle in the dynamics of gait, being involved in all phases of gait as either an active or passive muscle. Between toe-off and heel strike it actively dorsiflexes the ankle and then additionally stabilizes the foot in dorsiflexion during heel strike. Later, in the support phases (heel strike to toe-off) it stabilizes the foot and also extends the toes during toe off [2]. This muscle is particularly important in long stride walking where it is involved in helping propulsion forces whereas in slow walking it is more involved as stabilizers [2]. When the muscle is thin, weak and lesser in insertion as in the present case these functions of the muscle might be affected. The EDL has been blamed for contractures and deformities especially of the fifth toe (contracture producing hyperextension and overlapping) [2]. In such conditions, it would be useful for the clinicians to be aware of the variations reported in the present case where the tendon for the fifth toe is derived from PT and not from the EDL. Surgically, the EDL is used in transmetatarsal surgeries to balance the remaining foot and correction of deformities of the toes [15, 16]. Its insertions are made use of in returning its functions of extension of the toes in correction of foot drop [17]. In such events the transferred tendon would be sutured on to the common tendon of the muscle before its division into slips. When an abnormality such as the one that has been found in this case exists, such transfers would fail to act on the fifth toes having originated from a different muscle (peroneus tertius). Knowing anomalies related to structures hence becomes important to surgeons.

### Conclusion

Variations of the tendinous slips of PT and EDL and their abnormal insertions are less common. These abnormal patterns of insertions of these tendinous slips may affect the normal functioning of these muscles and are important for the clinicians and surgeons.

### References

1. Standring S, Borley NR, Collins P, Crossman AR, Gatzoulis MA, Healy JC, Johnson D, et al. *Gray's Anatomy: The Anatomical Basis of Clinical Practice*. 40th Edition, Elsevier, Churchill Livingstone, London. 2008; 1418-1419.
2. Doggett D. In [www.australiannaturaltherapistsassociation.com.au/downloads/bursary/2007/ANTA-Bursary\\_DeniseDoggett-Anatomy-for-Masseurs\\_Extensor-Digitorum-Longus.pdf](http://www.australiannaturaltherapistsassociation.com.au/downloads/bursary/2007/ANTA-Bursary_DeniseDoggett-Anatomy-for-Masseurs_Extensor-Digitorum-Longus.pdf) Retrieved on 3.6.2011.
3. Joshi SD, Joshi SS, Athavale SA. Morphology of peroneus tertius muscle. *Clin Anat* 2006; 19: 611-614.
4. Mehta V, Gupta V, Nayyar A, Arora J, Loh H, Suri RK, Rath G. Accessory muscle belly of peroneus tertius in the leg- a rare anatomical variation with clinical relevance utility in reconstructions. *Morphologie* 2011; 95:23-25.
5. Taşer F, Shafiq Q, Toker S. Coexistence of anomalous muscle peroneus tertius and longitudinal tear in the muscle peroneus brevis tendon. *Eklemler Hastalıkları* 2009; 20:165-168.
6. Yildiz S, Yalcin B. An unique variation of the peroneus tertius muscle. *Surg Radiol Anat*. 2012 Jan 6. [Epub ahead of print]
7. Das S, Haji Suhaimi F, Abd Latiff A, Pa Pa Hlaing K, Abd Ghafar N, Othman F. Absence of the peroneus tertius muscle: cadaveric study with clinical considerations. *Rom J Morphol Embryol* 2009; 50: 509-511.
8. Witvrouw E, Borre KV, Willems TM, Huysmans J, Broos E, De Clercq D. The significance of peroneus tertius muscle in ankle injuries: a prospective study. *Am J Sports Med* 2006; 34: 1159-1163.
9. Tezer M, Cicekcibasi AE. A variation of the extensor hallucis longus muscle (accessory extensor digiti secundus muscle). *Anat Sci Int* 2011 May 11 [Epub ahead of print].
10. Sakuma E, Kato H, Honda N, Mabuchi Y, Soji T. A rare anomaly of the extensor digitorum longus. *Anat Sci Int* 2004; 79: 235-238.
11. Bhargava KN, Sanyal KP, Bhargava SN. Lateral musculature of the leg as seen in hundred Indian Cadavers. *Ind J Med Sci* 1961; 15: 181-185.
12. Boon AJ, Harper CM. Electromyographic sensitivity of peroneus tertius relative to abductor hallucis in assessment of peripheral neuropathy. *Muscle Nerve* 2009; 40: 629-632.
13. Sammarco GJ, Henning C. Peroneus tertius muscle as a cause of snapping and ankle pain: a case report. *Am J Sports Med* 2007; 35:1377-1379.
14. Thorey F, Bruenger J, Windhagen H, Witte F. Muscle response to leg lengthening during distraction osteogenesis. *J Orthop Res* 2009; 27:483-488.
15. Roukis TS. Flexor hallucis longus and extensor digitorum longus tendon transfers for balancing the foot following transmetatarsal amputation. *J Foot Ankle Surg* 2009; 48:398-401.
16. Singh S, Singh T. A new and simplified functional tendon transfer for a dropped hallux. *Indian J Plast Surg* 2010; 43:76-78.
17. Vigasio A, Marcoccio I, Patelli A, Mattiuzzo V, Prestini G. New tendon transfer for correction of drop-foot in common peroneal nerve palsy. *Clin Orthop Relat Res* 2008; 466:1454-1466.