Letter to the Editor

Unusual usage of the automated stapler in gynecologic oncology: Method for diaphragmatic full thickness implant resection without entrance to pleural space

Kimyon Cömert et al. Diaphragmatic full thickness implant resection

Günsu Kimyon Cömert, Alper Karalok, Ciğdem Kılıç, Derman Başaran, Fatih Kılıç, Osman Türkmen, Taner Turan

Clinic of Gynecologic Oncology, University of Health Sciences Turkey, Etlik Zübeyde Hanım Women's Health Training and Research Hospital, Ankara, Turkey

Address for Correspondence: Günsu Kimyon Cömert
e-mail: gunsukimyon@gmail.com **ORCID:** orcid.org/0000-0003-0178-4196

DOI: 10.4274/jtgga.galenos.2020.2020.0008

Received: 06 February, 2020 **Accepted:** 16 June, 2020

To the Editor,

The improved survival impact of achieving to residue zero cytoreduction were proved in many studies for ovarian carcinoma (1, 2). In those, one of the most common involved site is diaphragm (up to 40%) which is one of the most common reasons for the failure to reach complete or optimal cytoreduction surgery (3). Although improvements in the techniques, experiences, and educations over the years, there are still concerns about complications and management of the diaphragmatic tumor resection especially in the presence of the full thickness implants. Therefore, we would like to point out a technique for resection of diaphragm full thickness implants without entrance to pleural space.

Firstly, liver was mobilized. The diaphragm striping was performed up to full thickness implant. When an unresectable area was reached, we performed these thecnique to resect the full thickness implant. Steps of the technique were as follows; (i) after identification of the full thickness implant borderlines; sutures placed to medial, middle and lateral edges of the full thickness implant to perform traction easier (figure 1), (ii) automated stapling devices such as thoraco-abdominal stapler DST seriesTM; figure 2) or gastro-intestinal anastomosis stapler DST seriesTM) were placed under the hauled full thickness implant transversally to diaphragm, (iii) for avoiding lung parenchymal injury, the ventilator was temporarily turned off after exhalation, while the stapler was locked up, (iv) the stapler was locked up to place the sutures automatically, (v) the full thickness implant above the staplers resected via scalpel for thoraco-abdominal stapler or by own automated scalpel for gastro-intestinal anastomosis stapler, and the stapler was opened, (vi) the resection completed without entrance to pleural space, (vii) control of the air leakage via the bubble test. There was no or minimal asymptomatic pleural effusion, no pneumothorax and also no need for thoracentesis at the postoperative period in both patients in our institution. Diaphragmatic muscle invasion of the high grade serous ovarian carcinoma was reported in pathologic results. (Institutional review board approval number: 07/2019/90057706-799).

One of the concerns related to diaphragmatic full thickness implant resection is pulmonary complications. Additionally, the entering to pleural cavity increases having a tendency to use prophylactic chest tube (4, 5). The presented technique may have an advantage to minimalize the occurrence of pneumothorax and the amount of pleural effusion by avoiding pleural entrance; thus, this may decrease the rate of impulsive tendency for using the chest tube, the need of thoracentesis, and also the postoperative morbidity. The presented technique may increase considering the diaphragmatic full thickness implant resection in the minimally invasive surgeries. The undeniable fact that the operation time is longer in the presence of diaphragmatic full thickness implant resection contrast to striping because of the need of manual closure by suture. This technique may have an advantage to decrease the operation time due to the having closure by automatically suturing. Kapnick et al showed that probability of pleural/parenchymal involvement was higher in the presence of more than 5 cm full thickness implant (6). Therefore, this technique can be a good option in the presence of the ≤4 cm full thickness implant.
According to our knowledge, this is the first report that describes usage of the thoraco-abdominal stapler for resection of diaphragmatic full thickness implant without entrance of the pleural space. Diaphragmatic full thickness implant resection with stapler is seem to be safe, practical and an easy to learn surgical technique. There is a need for large scale studies to evaluate the conclusions of this technique.

Conflict of interest statement

The authors declare that there is no conflict of interest. This research did not receive any specific grant from funding agencies in the public, commercial, or not for profit sectors.

References

1. Manning-Geist BL, Hicks-Courant K, Gockley AA, Clark RM, Del Carmen MG, Growdon WB, et al. Moving beyond "complete surgical resection" and "optimal": Is low-volume residual disease another option for primary debulking surgery? Gynecologic oncology. 2018;150(2):233-8.
2. Tseng JH, Cowan RA, Zhou Q, Iasonos A, Byrne M, Polcino T, et al. Continuous improvement in primary Debulking surgery for advanced ovarian cancer: Do increased complete gross resection rates independently lead to increased progression-free and overall survival? Gynecologic oncology. 2018;151(1):24-31.
3. Eisenkop SM, Spirtos NM. What are the current surgical objectives, strategies, and technical capabilities of gynecologic oncologists treating advanced epithelial ovarian cancer? Gynecologic oncology. 2001;82(3):489-97.
4. Franssen B, Tabrizian P, Weinberg A, Romanoff A, Tuvin D, Labow D, et al. Outcome of cytoreductive surgery and hyperthermic intraperitoneal chemotherapy on patients with diaphragmatic involvement. Ann Surg Oncol. 2015;22(5):1639-44.
5. Chereau E, Rouzier R, Gouy S, Ferron G, Narducci F, Bergzoll C, et al. Morbidity of diaphragmatic surgery for advanced ovarian cancer: retrospective study of 148 cases. Eur J Surg Oncol. 2011;37(2):175-80.
6. Kapnick SJ, Griffiths CT, Finkler NJ. Occult pleural involvement in stage III ovarian carcinoma: role of diaphragm resection. Gynecologic oncology. 1990;39(2):135-8.

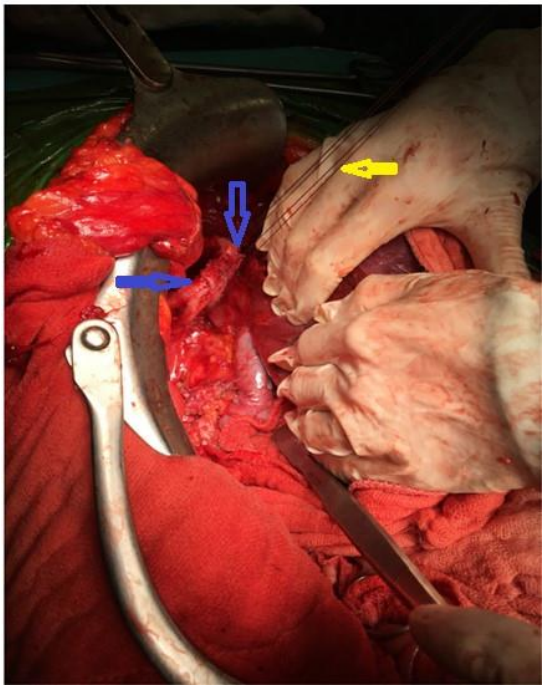

Figure 1. Sutures placed to the medial edge, the middle and the lateral edge of the full thickness implant to perform traction easier

Figure 2. Thoraco-abdominal stapler (DST seriesTM, 30 mm) was placed under the hauled full thickness implant transversally to diaphragm.