

Transluminal Nd: YAG Laser Embolysis for Branch Retinal Artery Occlusion: A case Report

Retinal Arter Dal Tıkanıklığında Transluminal Nd: YAG Lazer Embolizis, Olgu Sunumu

Nilüfer Koçak, Süleyman Kaynak, İlker Biçer*, Tülin Kaynak*, Gül Yucad*

Dokuz Eylul University, School of Medicine, Ophthalmology Department, İzmir, Turkey

**Izmir Retina Ophthalmic Research Center, İzmir, Turkey*

Summary

A 57-year-old, male, type 2 diabetic patient with the diagnosis of acute form of right eye inferotemporal branch retinal artery occlusion which occurred three days ago was reported. The patient complained of right eye visual field deficit (horizontal upper quadrant) with decreased visual acuity of finger counting from two meters. On fundus examination, calcific embolus was noted with inferotemporal branch artery occlusion and macular edema. The embolus was fragmented (embolysis) with the Nd:YAG laser technique. Subhyaloid hemorrhage developed and was drained by posterior hyaloidotomy with Nd:YAG laser at the same session. Visual acuity increased and hemorrhage gradually absorbed on follow-up period. Final visual acuity was 8/10 with eccentric fixation. Recovery of blood flow in the occluded arteriole both in fundus examination and fluorescein angiography were noted. (*Turk J Ophthalmol 2012; 42: 303-5*)

Key Words: Calcific embolus, branch retinal artery occlusion, Nd:YAG laser embolysis

Özet

Tip 2 diyabeti olan 57 yaşında erkek hasta, sağ gözünde üç gün önce akut gelişen horizontal üst kadran defekti ve azalmış görme keskinliği (2 mps) ile başvurdu. Fundus muayenesinde kalsifik emboli varlığında inferotemporal retinal arter dal tıkanıklığı ve maküler ödem görüldü. Emboli, Nd: YAG lazer tekniği ile parçalandı (embolizis). Aynı seansa subhyaloid hemoraji gelişti ve Nd: YAG lazer ile posterior hyaloidotomi yapılarak drene edildi. İzlem döneminde görme keskinliğinde artış, hemorajide çekilme görüldü. Son muayenesinde ekzantrik fiksasyon ile görme keskinliği 8/10 olarak ölçüldü. Hem fundus muayenesinde hem de florescein anjiyografide kan akımının düzeldiği izlendi. (*Turk J Ophthalmol 2012; 42: 303-5*)

Anahtar Kelimeler: Kalsifik emboli, retina arter dal tıkanıklığı, Nd: YAG lazer embolizis

Introduction

Recently, the neodymium:yttrium aluminum garnet (Nd:YAG) laser was used to perform transluminal Nd:YAG laser embolysis (TYE) in patients with central retinal artery occlusion (CRAO), branch retinal artery occlusion (BRAO) and a cilioretinal artery occlusion.¹⁻³ It has been hypothesized that it might be possible to selectively photodisrupt a solid embolus within a retinal arteriole without significant damage to the vessel wall. TYE resulted in photofragmentation of the emboli and immediate restoration of retinal blood flow.

Herein, we describe the evaluation of a patient who had BRAO and the clinical efficacy of the TYE on BRAO with visible embolus.

Case Report

A 57-year-old man presented with a history of sudden loss of vision in his right eye which occurred three days ago. At the time of ocular examination, his visual acuity was counting fingers from two meters in the right eye and 20/20 in the left eye. Moreover, the patient complained of visual field deficit (horizontal upper quadrant) of the right eye. Intraocular pressure (IOP) and the slit-lamp examination were normal in both eyes. He had no ocular history of disease, surgery, or trauma to either eye. He had well-controlled type 2 diabetes mellitus, diagnosed five years ago. On fundus examination, calcific embolus was noted with inferotemporal BRAO and narrowed arterioles with partial macular edema in the right eye (Figure 1). The fundus of the left eye was normal.

Address for Correspondence/Yazışma Adresi: Dr. Nilüfer Koçak, Dokuz Eylul University, School of Medicine, Ophthalmology Department, İzmir, Turkey
Phone: +90 232 412 30 62-3051 E-mail: nkocak@yahoo.com

Received/Geliş Tarihi: 04.05.2011 **Accepted/Kabul Tarihi:** 26.12.2011

After obtaining an informed consent for TYE for BRAO, the right eye was anesthetized with topical drops. A Goldmann fundus contact lens (Ocular Instruments, Bellevue, WA) was used to focus the Nd:YAG laser (Coherent 7970, Palo Alto, CA) on the embolus within the retinal artery. A 2.0 mJ pulse was initially delivered directly to the embolus which yielded no retinal tissue response. The energy was increased in 2-mJ increments without tissue response until the setting was placed at 6.0 mJ for embolysis. Although the laser energy was applied for embolysis, a small opening was made in the arteriolar wall at the same time and just after the laser application with 6.0-mJ, suddenly subhyaloid hemorrhage developed overlying the occluded vessel area (Figure 2). During the embolysis and opening the arteriolar wall, some part of the embolus could have been passed into the

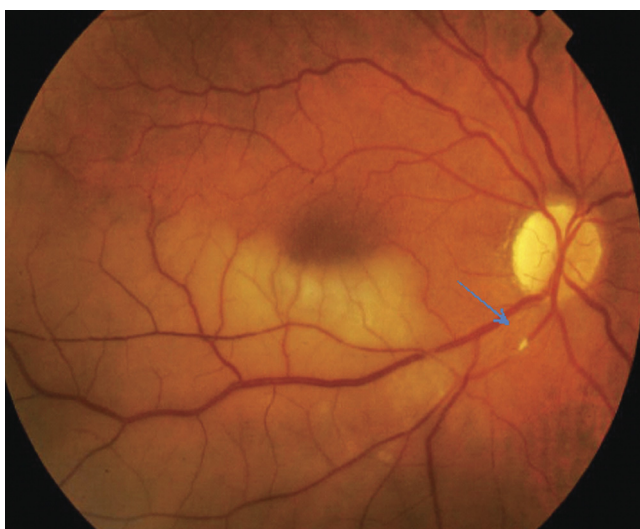

Figure 1. Color fundus photograph of the right eye demonstrating the transluminal calcific embolus (arrow), narrowed arterioles and retinal opacification

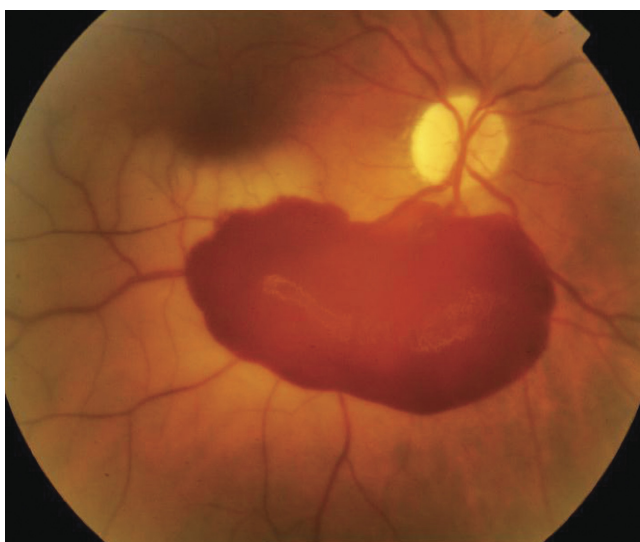


Figure 2. Color fundus photograph of the right eye, immediately following transluminal Nd:YAG embolysis with subhyaloid hemorrhage overlying the occluded vessel area

vitreous. Just after the subhyaloid hemorrhage, we pressed the eye with contact lens and continued to perform the laser application with the same energy level for draining the hemorrhage by posterior hyaloidotomy. One week after the TYE procedure, the patient's visual acuity did not change but he reported a significant subjective increase in his visual acuity. Fundus examination revealed that subhyaloid hemorrhage had decreased in size.

At the third month, his best-corrected visual acuity had improved to 8/10 with the help of head movement. Fluorescein angiography still demonstrated the presence of the embolus with a restoration of retinal arteriolar blood flow and regression of macular edema. Ophthalmoscopy demonstrated the evidence of a part of an intraluminal embolus with increased caliber of the arterioles (Figure 3). His condition did not change after 18 months.

Discussion

There is no known effective treatment for BRAO. Numerous treatment modalities have been attempted in both CRAO and BRAO without much success including low-intensity photocoagulation, intravenous prostaglandin E1 infusion, and enhanced external counter pulsation.^{1,3,4}

Recently, Opremcak and Benner⁵ used the Nd:YAG laser to perform TYE in two patients with BRAO and a cilioretinal artery occlusion. TYE resulted in disappearance of the emboli and immediate restoration of retinal blood flow. They suggested that this technique might be beneficial in eyes with RAO where an embolus is visible. Mason et al.¹ reported five patients with BRAO who were treated with TYE. They noted that all patients showed improvement in best-corrected visual acuity one day after TYE. Fluorescein angiography showed immediate and dramatic restoration in flow past the obstructed arteriole in all patients.

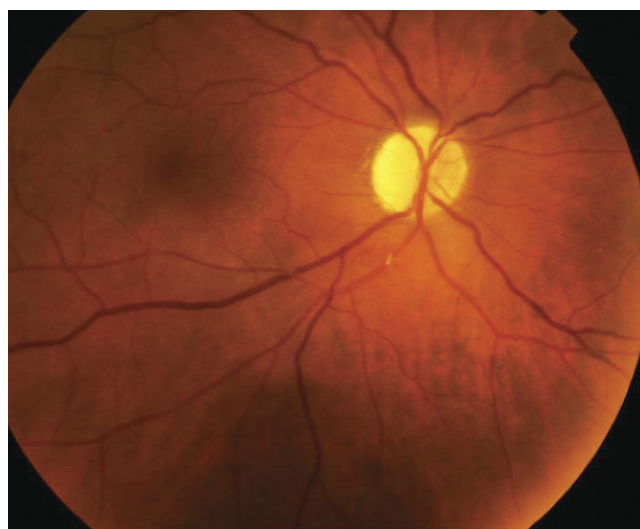


Figure 3. Color fundus photograph of the right eye with the evidence of a regressed form of an intraluminal embolus and increased caliber of arterioles, three months after transluminal Nd:YAG embolysis

After their pilot report, again Opremcak et al.³ reported their experience with TYE or embolectomy in 19 patients (9 BRAO and 10 CRAO) over a 5-year period. All of the patients had immediate and dramatic restoration of retinal blood flow following TYE or embolectomy as documented by fluorescein angiography. Furthermore, they mentioned that they did not find a correlation between duration of the RAO and vision recovery. Seven patients had vitreous hemorrhage at the time of the embolectomy.

One patient developed a large subhyaloid hemorrhage in an area corresponding to the vascular supply of the occluded BRA. Our patient also had a large subhyaloid hemorrhage at the time of the embolectomy. By this way, part of the embolus could pass into the vitreous. After performing posterior hyaloidotomy with Nd:YAG laser at the same session, we noted the regression of the embolus and an increase in the caliber of the arterioles during the follow-up period. Moreover, after performing TYE, photodisruption of the embolus could have supported the reflow of retinal blood through the recanalization of the embolus.

The potential risks of TYE include subhyaloid and vitreous hemorrhage, retinal tears, choroidal neovascularization, and epiretinal membrane formation.^{1,3,5} The risks of TYE need to be weighed against the permanent and often severe loss of vision due

to arteriolar occlusion. As mentioned in previous studies, it is possible that the improved visual acuities in patients with BRAO were unrelated to TYE or embolectomy.^{1,3-5} However, the synchrony of recirculation and restoration of vision immediately following TYE or embolectomy suggests a beneficial effect of this procedure. In light of our experience in this case, TYE can be taken into account and can be an option and feasible technique for restoring retinal blood flow and allowing for retinal recuperation and return of visual function in the majority of patients with BRAO.

References

1. Mason JO, Nixon PA, Albert MA. Trans-luminal Nd:YAG laser embolysis for branch retinal artery occlusion. *Retina*. 2007;27:573-7.
2. Feist R, Emond TL. Transluminal Nd:YAG laser embolysis for centralretinal artery occlusion. *Retina*. 2005;25:797-9.
3. Opremcak EM, Rehmar AJ, Ridenour CD, Borkowski LM, Kelley JK. Restoration of retinal blood flow via transluminal Nd:YAG laser embolysis/embolectomy (TYL/E) for central and branch retinal artery occlusion. *Retina*. 2008;28:226-35.
4. Dutton GN, Craig G. Treatment of a retinal embolus by photocoagulation. *Br J Ophthalmol*. 1989;73:580-1.
5. Opremcak EM, Benner JD. Transluminal Nd:YAG laser embolysis for branch retinal artery occlusion. *Retina*. 2002;22:213-6.