



Imaging Findings of Cyst Hydatid Lesions in a Patient with Multiorgan Involvement: A Case of Hydatid Cyst with Multiorgan Involvement

Multiorgan Tutulumu Olan Hastada Kist Hidatik Lezyonlarının Görüntüleme Bulguları *Multiorgan Tutulumu Olan Kist Hidatik Olgusu*

● Pinar Gündoğan Bozdağ, ● Ahmet Bozdağ*, ● Abdullah Büyük**

University of Health Sciences Turkey, Elazığ Fethi Sekin City Hospital, Clinic of Radiology, Elazığ, Turkey

*Firat University Faculty of Medicine, Department of General Surgery, Elazığ, Turkey

**University of Health Sciences Turkey, Elazığ Fethi Sekin City Hospital, Clinic of General Surgery, Elazığ, Turkey

Abstract

Hydatid disease (HD) is a zoonosis caused by the larval form of the *Echinococcus granulosus* parasites in which human is the intermediate host. Hydatid cysts mainly develop in the liver and lungs. However, they can be found in all anatomical locations, especially in endemic areas. Herein, we present a case of HD involving the liver, kidney and breast with the findings of mammography, ultrasonography and computed tomography.

Keywords: Hydatid cyst, multiorgan, breast, renal

Öz

Kist Hidatik Hastalığı (KHH), *Echinococcus granulosus* parazitinin larval formu tarafından oluşturulan insanın ara konak olduğu bir zoonozdur. Sıklıkla karaciğer ve akciğerde lokalize olur. Özellikle endemik bölgelerde, tüm anatomik lokalizasyonlarda bulunabilir. Biz eş zamanlı tanı konulan karaciğer, böbrek ve meme tutulumu olan bir KHH olgusunu mamografi, ultrasonografi ve bilgisayarlı tomografi görüntüleme bulguları ile sunduk.

Anahtar Sözcükler: Kist hidatik, multiorgan, meme, böbrek

Introduction

Hydatid disease (HD) is a zoonosis caused by the larval form of the *Echinococcus granulosus* parasites in which human is the intermediate host (1). Hydatid cysts mainly develop in the liver (75%) and lungs (15%) and less frequently (10%) in other internal organs (2). Hydatid cyst of the breast is very rare and patients usually present with painless swelling of the breast. Since it is usually asymptomatic, it is diagnosed during routine mammographic examinations (2,3). Herein, we present a case of HD involving the liver, kidney and breast with findings of mammography (MG), ultrasonography (USG) and computed tomography (CT).

Case

A 45-year-old woman was referred from the general surgery outpatient clinic to the radiology department

for routine breast screening and non-specific abdominal pain. On physical examination, there was no abnormal abdominal examination finding except for a scar of a previous right subcostal incision from a liver hydatid cyst surgery. Breast examination revealed a palpable mobile mass with an elastic consistency in the upper outer quadrant of the left breast. Breast USG examination revealed a heterogeneous hyperechoic lesion (Type 4) of approximately 2x2 cm in size in the left breast at the 2 o'clock position having smooth borders and a folded thick membrane view inside, with acoustic enhancement (Figure 1). Abdominal USG showed a heterogeneous hyperechoic lesion (Type 4) of approximately 5x3.5 cm in size in the upper part of the right kidney which located cortically, had smooth borders and a folded thick membrane view inside and acoustic enhancement. In the segment 4 of the liver, there was a cystic lesion (Type 2)

Address for Correspondence/Yazışma Adresi: Ahmet Bozdağ, Firat University Faculty of Medicine, Department of General Surgery, Elazığ, Turkey

Phone: +90 533 652 51 63 E-mail: abozdag80@hotmail.com ORCID: orcid.org/0000-0003-1973-2511

Received/Geliş Tarihi: 30 April 2019 **Accepted/Kabul Tarihi:** 11 March 2020

©Copyright 2020 by The Medical Bulletin of Istanbul Haseki Training and Research Hospital
The Medical Bulletin of Haseki published by Galenos Yayınevi.

©Telif Hakkı 2020 İstanbul Haseki Eğitim ve Araştırma Hastanesi
Haseki Tıp Bülteni, Galenos Yayınevi tarafından yayımlanmıştır.

of approximately 6.5x6 cm in size with separated thick membrane inside demonstrating acoustic enhancement (Figure 2). The patient had a history of surgery for a hepatic hydatid cyst. When the patient's previous radiological examinations were reviewed, her previous MG showed an opacity measuring approximately 2x2 cm with smooth borders and lucent folds inside (Figure 3) in the left upper quadrant of the left breast. Abdominal CT revealed a thick-walled cystic lesion of 6.5x6 cm in size with detached thick membrane inside in the segment 4 of the liver. Besides, there was a thick-walled heterogeneous lesion measuring approximately 5x3.5 cm with smooth borders and folded thick membrane inside in the upper part of the right kidney (Figure 4). Liver function tests and biochemical tests were within the normal limits. Hemagglutination test was negative for HD. Surgical treatment was recommended but the patient refused. Informed consent was obtained from the patient.

Discussion

Hydatid disease is still a serious public health problem in endemic areas. It is a tissue infestation caused by the larval stage of a parasite named *E. granulosus* (4). HD of the breast is very rare even in endemic areas and constitutes only 0.27% of all cases. The breast may be involved primarily or can be a part of disseminated hydatidosis (5). Since the primary disease presented as a hepatic lesion in our patient, the lesion in the breast was a part of disseminated hydatidosis. Hydatid cysts of the breast are usually caused by hematogenous spread, but there is also the possibility of retrograde passage of *E. granulosus* eggs from the milk ducts during breastfeeding (5). Cystic lesions of the breast, fibroadenoma, phyllodes tumor and breast abscess should be kept in mind in the differential diagnosis of HD. Clinically, HD of the breast is usually painless. There is no specific physical examination finding (2). Our patient also presented to the hospital for

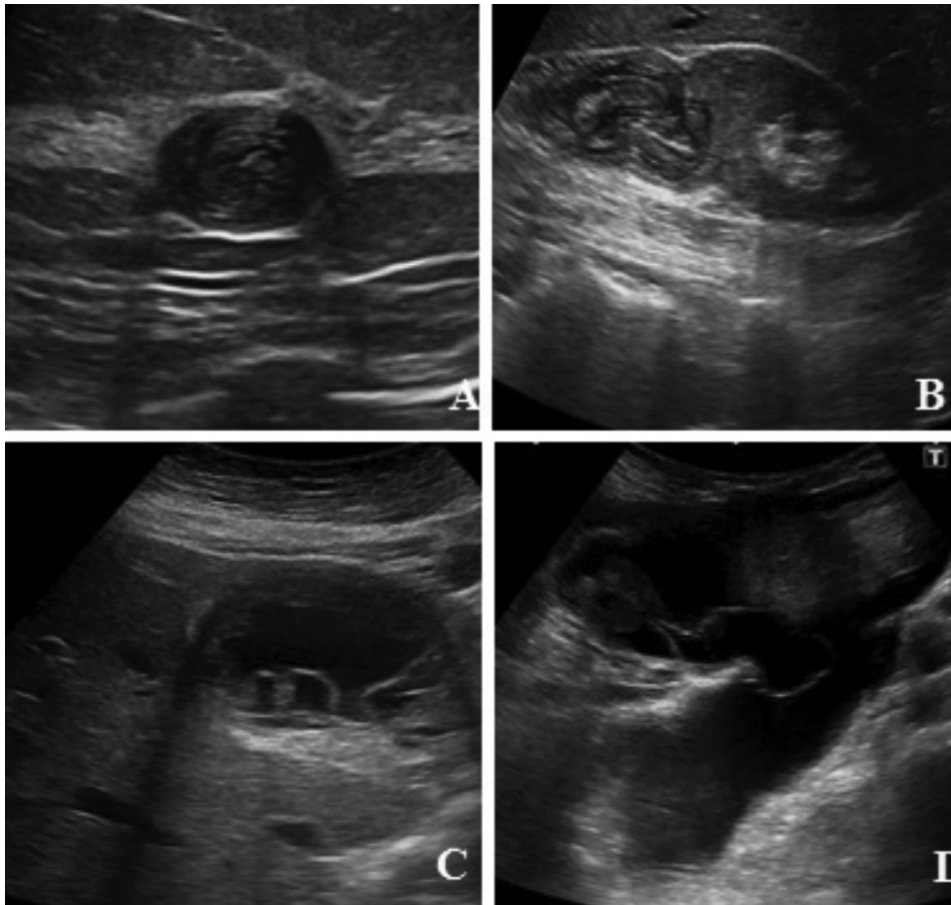


Figure 1. **A)** Breast US, heterogeneous hypoechoic solid lesion with acoustically strengthened and internal curved hypoechoic membranes in the left breast. **B)** Abdomen US, heterogeneous solid lesion with smoothly lobulated contours, exophytic extension, acoustic strengthening, internal curved hypoechoic membranes in the lower part of the kidney. **C)** Multiple septated cystic lesion with acoustic strengthening in the left lobe of the liver. **D)** Septal fluids in the lower quadrant of the abdomen

US: Ultrasonography

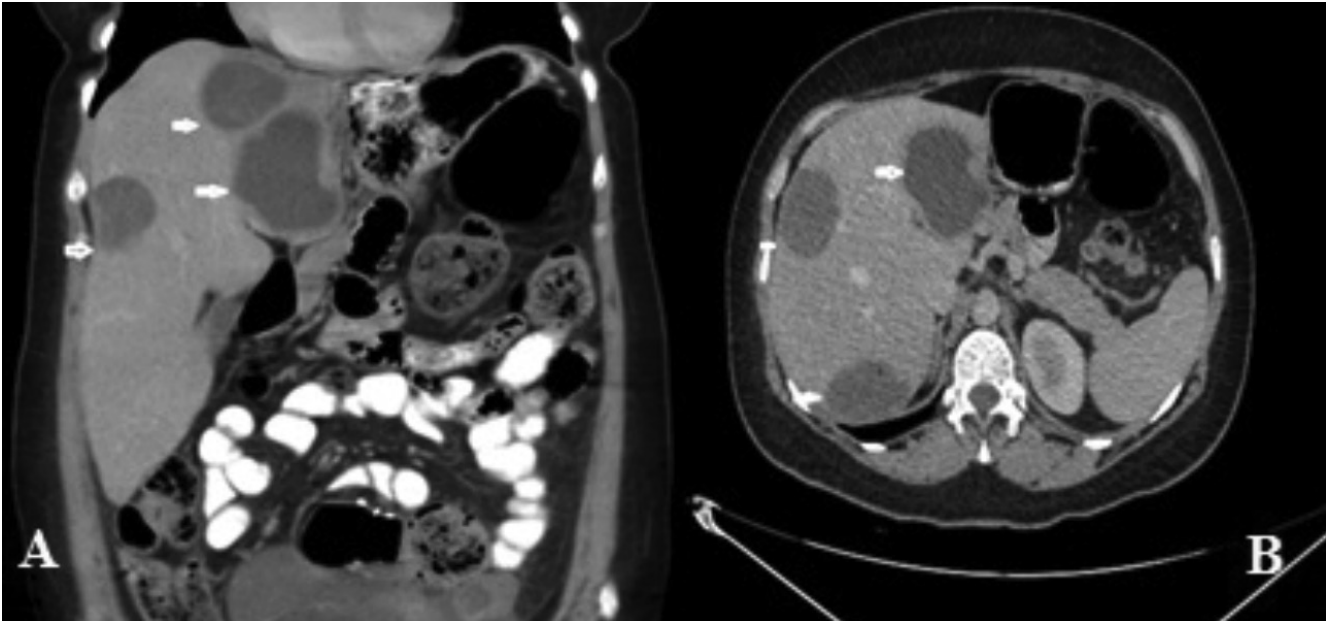


Figure 2. Upper abdomen CT **A)** Coronal and **B)** Axial, 3 cystic lesions of hypodense fluid density with smooth limited and internal hyperdense septations in liver

CT: Computed tomography

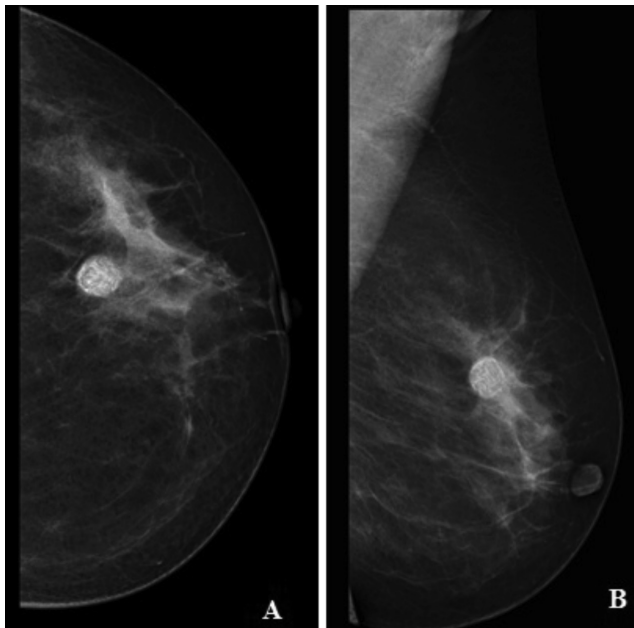


Figure 3. Mammography **A)** CC and **B)** MLO, opacity with smooth limited and internal lusen curved areas in the upper outer quadrant of the left breast

CC: Craniocaudal, MLO: Mediolateral oblique

routine screening and the hydatid cyst of the breast was incidentally detected.

Renal involvement is usually associated with systemic involvement, while isolated renal HD is a very rare

condition. However, the kidney is the most frequently involved organ in the genitourinary system (6).

USG shows complex cysts in all patients. USG is the primary imaging modality for classification of hydatid cysts. During USG examination, similar to that in other organs, hydatid cysts in the breast are evaluated as well-bordered structures with mixed echo characteristics containing multicystic and solid areas (2). They are difficult to diagnose unless cyst membranes or fluid levels are observed on USG images. On MG, they are demonstrated as homogeneous, non-specific, round lesions with smooth-contours. Annular structures around a radiopaque, well-counteracted lesion on MG are also indicative of HD. Presence of hydatid cysts in other organs supports the diagnosis of breast HD (7,8). There was no difficulty in diagnosing breast HD in our patient, because the appearance of the lesion on USG and on the previous MG was typical and she had a medical history of HD.

CT and USG provide similar information. However, CT shows the location and depth of the cyst in the liver more accurately. CT scans show the presence of daughter cysts and exogenous cysts. MRI provides the structural details of the hepatic hydatid cyst. MRI findings are non-specific. Cystic lesions are hyperintense on T₂-weighted images and hypointense on T₁-weighted images. Contrast MRI shows a cystic lesion with peripheral enhancement (9,10).

The common treatment options are surgical treatment, medical treatment, puncture, aspiration, injection, and re-aspiration. In medical treatment, praziquantel can

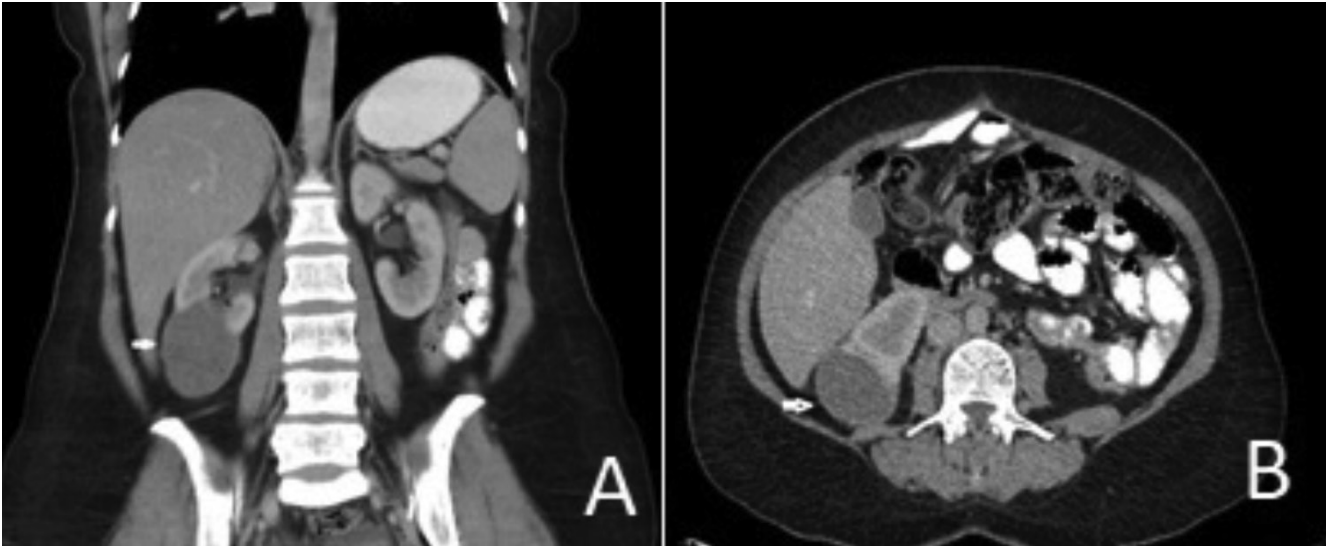


Figure 4. Upper abdomen CT. **A)** Coronal and **B)** Axial, cystic lesion in the right kidney with exophytic extension and internal hyperdense septations

CT: Computed tomography

be used with benzimidazoles such as mebendazole and albendazole. Medical treatment with albendazole and mebendazole is carried out prior to and after the surgery to ensure cyst sterilization, to reduce the risk of anaphylaxis and prevent recurrence after surgery.

In conclusion, HD is a serious public health problem in endemic regions. It affects many organs through intraoperative transmission or by hematogenous spread. Breast and renal hydatid cysts are rare; hence, the differential diagnosis is challenging. It should be kept in mind in patients with hepatic HD.

Authorship Contributions

Concept: P.G.B., A.B. Design: P.G.B., Ab.B. Data Collection or Processing: P.G.B., A.B. Analysis or Interpretation: P.G.B., Ab.B. Literature Search: P.G.B., A.B. Writing: P.G.B., A.B.

Conflict of Interest: No conflict of interest was declared by the authors.

Financial Disclosure: The authors declared that this study received no financial support.

References

1. Tali S, Aksu A, Bozdağ PG, Bozdağ A. Primary Retroperitoneal Hydatid Cyst. *Turkiye Parazitoloj Derg* 2015;39:241-3.

2. İnci E, Aydın S, Baysal N, ve ark. İzole primer meme hidatik kisti: Olgu sunumu. *Med J Bakirkoy* 2006;2:31-2.
3. Koc A, Sarici IS, Vurdem UE, Karabiyik O, Gumus UO. Unusual Presentation of Hydatid Cyst in Breast with Magnetic Resonance Imaging Findings. *Case Rep Med* 2017;2017:6237435.
4. Dziri C. Hydatid disease - Continuing serious public health problem: introduction. *World J Surg* 2001;25:1-3.
5. Micu BV, Jeican II, Micu CM, Pop TR. Breast Hydatid Cyst: Case Report. *J Bacteriol Parasitol* 2017;8:2.
6. Merdin A, Ögür E, Kolak ÇÇ, ve ark. Renal Kist Hidatik. *Turkiye Parazitoloj Derg* 2014;38:190-3.
7. Mujawar P, Suryawanshi KH, Nikumbh DB. Cytodiagnosis of isolated primary hydatid cyst of breast masquerading as a breast neoplasm: A rare case report. *J Cytol* 2015;32:270-2.
8. Malik A, Chandra R, Prasad R, Khanna G, Thukral BB. Imaging appearances of atypical hydatid Cysts. *Indian J Radiol Imaging* 2016;26:33-9.
9. Gümüş M, Gümüş H, Budak H, Teke M. Breast Cyst Hydatid: A Case Report. *Ann Clin Cytol Pathol* 2016;2:1017.
10. Dagli AF, Ozercan MR, Kocakoc E. Hydatid cyst of the breast mimicking inflammatory carcinoma and mastitis. *J Ultrasound Med* 2006;25:1353-6.