



Bilateral Serous Macular Detachment in Acute Myelogenous Leukemia

Akut Myeloid Lösemiye Bağlı Bilateral Seröz Maküla Dekolmanı

Müge Karataş, Rana Altan Yayıoğlu, Can Boğa*, Burak Ulaş

Başkent University Faculty of Medicine, Department of Ophthalmology, Adana, Turkey

*Başkent University Faculty of Medicine, Department of Hematology, Adana, Turkey

Summary

A 31-year-old woman, diagnosed and treated for acute myelogenous leukemia (AML) type M2, complained of blurred vision and general deterioration in vital signs in her fourth week of hospitalization for induction chemotherapy. Her ophthalmologic examination revealed bilateral serous macular detachment. Despite immediate institution of salvage therapy for refractory disease, extensive intraretinal and preretinal hemorrhages developed in both eyes. Three weeks after reinstitution of chemotherapy, the patient deceased. Bilateral serous macular detachment is rarely an ocular manifestation of AML. This may be a sign of leukemic infiltration of the choroid and worsening of the clinical symptoms. (*Turk J Ophthalmol* 2014; 44: 151-3)

Key Words: Acute myelogenous leukemia, blurred vision, serous macular detachment

Özet

Akut myeloid lösemi (AML) tip M2 tanısı koyulup takip edilen 31 yaşında bayan hasta indüksiyon kemoterapi tedavisinin dördüncü haftasında bulanık görme ve genel durumunda bozulma şikayeti ile kliniğimize refere edildi. Oftalmolojik muayenesinde bilateral seröz maküla dekolmanı tespit edildi. Hemen kurtarma tedavisi başlandığı halde, hastanın her iki gözünde yoğun intraretinal ve preretinal hemorajiler gelişti. Kemoterapinin yeniden düzenlenmesi sonrasında hasta üç hafta içinde kaybedildi. Bilateral seröz maküla dekolmanı AML'de çok nadir görülen bir bulgudur. Bu bulgu koroid infiltrasyonunu ve klinik bulguların kötüleşmesini işaret edebilir. (*Turk J Ophthalmol* 2014; 44: 151-3)

Anahtar Kelimeler: Akut myeloid lösemi, bulanık görme, seröz maküla dekolmanı

Introduction

Ocular involvement in acute leukemia has been reported in up to 90% of patients.¹ It can manifest either through direct leukemic infiltration or through secondary changes resulting from haematological abnormalities.² Typical ocular manifestation of leukemia is the presence of retinal hemorrhages, which are most commonly located at the posterior pole. The intraretinal hemorrhage may contain a white component that usually is a white dot in the center of the hemorrhage. Serous retinal detachment is a less common ocular manifestation.^{2,3}

Herein, we report a case with acute myeloid leukemia that developed severe bilateral serous macular detachment during her chemotherapy treatment.

Case Report

A 31-year-old woman complained of headache, fatigue, and weight loss for one month. Laboratory work-up revealed hyperchromic and normocytic anemia. Her complete blood count revealed low hemoglobin of 4.6 g/dL (normal range 12-16 g/dL), haematocrite of 12.7% (normal range 36%-46%), highly elevated leucocyte count of 124x10⁹/L leukocytes, and 150x10⁹/L platelets. There was an increase in C-reactive protein 19.7 mg/L (normal range 0-6 mg/L), and lactic dehydrogenase level of 700 IU/L (normal range 90-240 IU/L). Differential blood count revealed 75% monocytes, 14.9% lymphocytes, 6.18% neutrophils, 1.2% eosinophils, and 2.53% basophils. Serology for EBV, HIV, CMV, and Aspergillus galactomannan antigen was negative. Based on the above findings and flow cytometry,

acute myelogenous leukemia (AML) French-American-British classification type M2 was diagnosed. Induction chemotherapy with cytosine arabinoside and idarubicin was instituted. Fluoroquinolone and acyclovir were added for antimicrobial prophylaxis. She also received additional erythrocyte and thrombocyte suspensions. Although she received full treatment for 3 weeks, her thrombocyte and erythrocyte counts were not within normal limits ($80.4 \times 10^9/L$ and $2.8 \times 10^9/L$, respectively). She suffered from neutropenic fever. In the fourth week of her hospitalization, she had primary refractory disease and complained of blurred vision. The patient was referred to ophthalmology clinic.

Her ophthalmologic examination revealed best-corrected visual acuity (BCVA) of counting fingers at three meters in both eyes. Intraocular pressure measured with Goldmann applanation tonometry was 11 mmHg in both eyes. Slit lamp examination revealed no obvious inflammation in the anterior chamber or vitreous. Fundus examination revealed serous detachment of the macula, a small submacular hemorrhage in the right eye, and solitary serous detachment of the macula in the left eye (Figure 1A, left), and solitary serous detachment of the macula in the left eye (Figure 1A, right). Fundus fluorescein angiography showed bilateral diffuse submacular accumulation of fluorescein and multifocal hyperfluorescent dots, as well as hyperfluorescence of the left optic nerve head (Figure 1B). Optical coherence tomography (OCT) disclosed large amount of subretinal fluid in both eyes (Figure 1C). Salvage therapy for leukemia (FLAG-Fludarabine, Cytarabine and Filgrastim) was

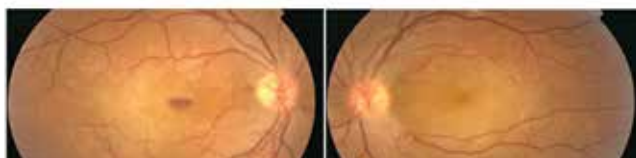

Figure 1A. Fundus examination revealed serous detachment of the macula, a small submacular hemorrhage in the right eye, and solitary serous detachment of the macula in the left eye

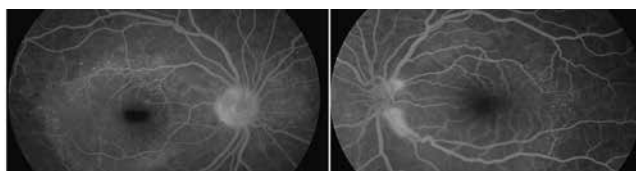


Figure 1B. Fundus fluorescein angiography showed bilateral diffuse submacular accumulation of fluorescein and multifocal hyperfluorescent dots, as well as hyperfluorescence of the left optic nerve head

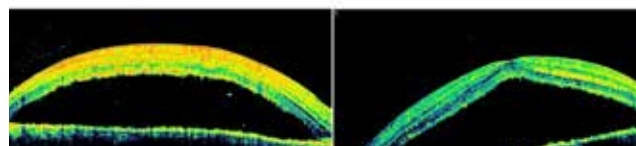


Figure 1C. Optical coherence tomography (OCT) disclosed large amount of subretinal fluid in both eyes. Central macular thickness of the right eye was 856 microns and that of the left eye was 997 microns

instituted immediately. Five days after the first examination, her BCVA improved to 0.16 in both eyes. Fundus examination and OCT findings revealed improvement in the serous detachment. However, extensive intraretinal and preretinal hemorrhages were observed in both eyes (Figure 2A and Figure 2B). Three weeks after reinstitution of chemotherapy, the patient deceased. The family denied forensic evaluation. Thus, post-mortem investigation was not possible.

Discussion

Ocular manifestations in leukemia may involve ocular and adnexal tissues.¹ Although cotton wool spots and intraretinal hemorrhages are common in leukemic patients, serous retinal detachments are rarely seen.⁴ Intraocular manifestations of leukemia are usually treated with systemic chemotherapy and resolve completely with full recovery of visual acuity.¹

The posterior manifestations of leukemia are probably due to leukemic infiltration of the choroid¹ or from hematological abnormalities associated with leukemia, such as anemia, thrombocytopenia, hyperviscosity states or opportunistic infections; or secondary to treatment of leukemia itself.^{5,6} The decrease in vision, serous detachment, and retinal hemorrhages may probably be the sign of ineffective treatment.

Contributing factors might be using chemicals, viral infections, and myelotoxic agents.⁷⁻⁹ Chemicals can contribute to macular detachment through direct toxic effects on retinal cells. Among these, acyclovir and fluoroquinolone have been reported to be responsible compounds for retinal detachment.^{7,8} Our patient received these compounds for viral and bacterial prophylaxis. It can be suggested that these drugs and probably myelotoxic agents may contribute to macular problem.

Serous retinal detachment may develop in consequence of choroidal involvement by leukemic cells causing retinal pigment epithelial disturbances or due to incompetence of the blood-retinal barrier inducing retinal pigment epithelial changes.^{3,10} Stewart et al³ postulated that leukemic infiltration of the choroid caused decreased blood flow in the choriocapillaris, resulting

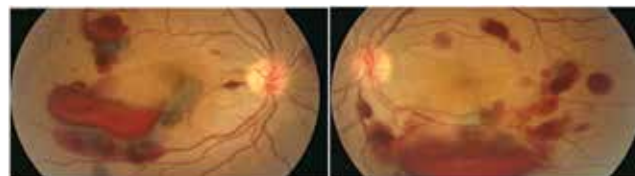


Figure 2A. Five days after the first examination, extensive intraretinal and preretinal hemorrhages were observed in both eyes

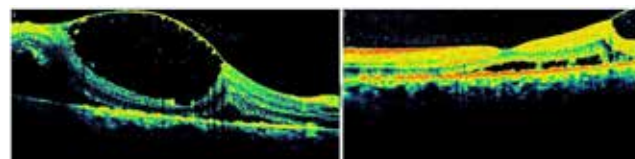


Figure 2B. OCT revealed improvement in the serous detachment with hemorrhagic cysts

in ischemia to the overlying retinal pigment epithelium and disruption of the intercellular tight junctions.

Several case reports revealed serous retinal detachment as a presenting sign of the acute leukemia. Visual symptoms of these patients were mostly improved with systemic chemotherapy.^{11,12} In another case, bilateral exudative retinal detachment was the first sign of relapsing AML. Because the systemic work-up in the beginning was negative, appropriate treatment was given with a delay of three months. The authors mentioned that it is unclear whether earlier detection and treatment of the relapse would have saved this patient's life.⁵ In our case, our patient was previously known to be healthy, and after the diagnosis of AML, she did not have any improvement in her symptoms with the induction chemotherapy. She suffered from visual symptoms 4 weeks after the induction chemotherapy along with general deterioration in vital signs. Unfortunately, despite immediate institution of salvage therapy, our patient deceased.

In conclusion, serous retinal detachment was rarely reported in leukemia patients and was not reported before during the course of treatment. Serous retinal detachment in a patient with AML should alert the hematologist and ophthalmologist that this may be a sign of leukemic infiltration of the choroid and/or worsening of the symptoms.

References

1. Kincaid MC, Green WR. Ocular and orbital involvement in leukemia. *Surv Ophthalmol.* 1983;27:211-32.
2. Sharma T Grewal J, Gupta S, Murray PI. Ophthalmic manifestations of acute leukaemias: the ophthalmologist's role. *Eye (Lond).* 2004;18:663-72.
3. Stewart MW, Gitter KA, Cohen G. Acute leukemia presenting as a unilateral exudative retinal detachment. *Retina.* 1989;9:110-4.
4. Miyamoto K, Kashii S, Honda Y. Serous retinal detachment caused by leukaemic choroidal infiltration during complete remission. *Br J Ophthalmol.* 2000;84:1318-9.
5. Wu L, Calderon M, Hernandez G, Marbis J, Ramirez V. Bilateral exudative retinal detachment as the first sign of relapsing acute myelogenous leukaemia. *Clin Experiment Ophthalmol.* 2006;34:623-5.
6. Schachat AP, Dhaliwal RS. Leukemias and lymphomas. In: Ryan SJ (ed). *Retina*, 2nd ed. CV Mosby:St Louis, 1994, pp 873-890.
7. Jeon S, Kakizaki H, Lee WK, Jee D. Effect of prolonged oral acyclovir treatment in acute retinal necrosis. *Ocul Immunol Inflamm.* 2012;20:288-92.
8. Etminan M, Forooghian F, Brophy JM, Bird ST, Maberley D. Oral fluoroquinolones and the risk of retinal detachment. *JAMA.* 2012;307:1414-9.
9. Giralt J, Rey A, Villanueva R, Alforja S, Casaroli-Marano RP. Severe visual loss in a breast cancer patient on chemotherapy. *Med Oncol.* 2012;29:2567-9.
10. Hine JE, Kingdam JD. Myelogenous leukemia and bilateral exudative retinal detachment. *Ann Ophthalmol.* 1979;11:1867-72.
11. Kim J, Chang W, Sagong M. Bilateral serous retinal detachment as a presenting sign of acute lymphoblastic leukemia. *Korean J Ophthalmol.* 2010;24:245-8.
12. Thill M, Schwartz R, Fiedler W, Linke S. Bilateral retinal pigment epithelial detachment as the presenting symptom of acute myeloid leukaemia. *Eye (Lond).* 2006;20:851-2.