

# A Rare Cause of Renal Vein and Inferior Vena Cava Thrombosis: A Case of Embryonal Testicular Carcinoma

## Renal Ven ve Inferior Vena Kava Trombozunun Nadir Bir Nedeni: Embriyonel Testis Karsinomu Olgusu

 Sevgi Aras<sup>1</sup>,  Murat Yakın<sup>1</sup>,  İsmail Şerifoğlu<sup>2</sup>,  İsmail Ulus<sup>3</sup>,  Abdülkadir Zengin<sup>3</sup>,  Şule Özsoy<sup>4</sup>,  Aslıhan Bayır<sup>1</sup>,  Ülkühan Köksal<sup>5</sup>,  Ahmet Engin Atay<sup>1</sup>

<sup>1</sup>University of Health Sciences Turkey, Bağcılar Training and Research Hospital, Clinic of Internal Medicine, İstanbul, Turkey

<sup>2</sup>University of Health Sciences Turkey, Bağcılar Training and Research Hospital, Clinic of Radiodiagnostic, İstanbul, Turkey

<sup>3</sup>University of Health Sciences Turkey, Bağcılar Training and Research Hospital, Clinic of Urology, İstanbul, Turkey

<sup>4</sup>University of Health Sciences Turkey, Bağcılar Training and Research Hospital, Clinic of Pathology, İstanbul, Turkey

<sup>5</sup>University of Health Sciences Turkey, Bağcılar Training and Research Hospital, Clinic of Oncology, İstanbul, Turkey

### Abstract

Thrombosis is rarely the manifestating symptom of testicular cancers. Patients are usually admitted with painless testicular mass or less frequently pain or hydrocele. Here, we present a young male with germ cell tumor of testis, referred with renal vein and inferior vena cava thrombosis.

**Keywords:** Germ cell tumor, inferior vena cava, renal vein, thrombosis

### Öz

Tromboz, testiküler kanserlerin nadiren ilk bulgusudur. Hastalar genellikle ağrısız testis kitlesi ya da nadiren ağrı veya hidrosel ile başvurur. Renal ven ve inferior vena kavada tromboz ile başvuran testis germ hücreli tümörü olan genç bir hastayı sunmaktayız.

**Anahtar kelimeler:** Germ hücreli tümör, inferior vena kava, renal ven, tromboz

### Introduction

The incidence of testicular germ-cell tumors is 3-10/100,000, which makes it the most frequent cancer among young males (1). It accounts %1 of all cancers but also the 95% of all testicular cancers (2). The most common presenting symptom is painless swelling of one testicle; however less frequently, patients may be admitted with pain, hydrocele or an incidentally found lesion in the retroperitoneum (3). Lack of symptoms in the early stages causes delays in the diagnosis of testicular cancer (TC) in young patients compared to patients older than 50 years (4). We report a

case who presented with incidentally found inferior vena cava vein thrombosis.

### Case Report

A 32-year-old young male had fatigue and night sweating for more than 3 months, accompanied by 4 kilogram weight loss in 3-4 weeks. Abdomen and thorax tomographic examination revealed out multiple lymphadenomegalies, and consequently renal doppler ultrasonography indicated thrombosis in the right renal vein and vena cava inferior which reached out inferior hepatic vein and totally occluded



**Address for Correspondence:** Ahmet Engin Atay, University of Health Sciences Turkey, Bağcılar Training and Research Hospital, Clinic of Internal Medicine, İstanbul, Turkey

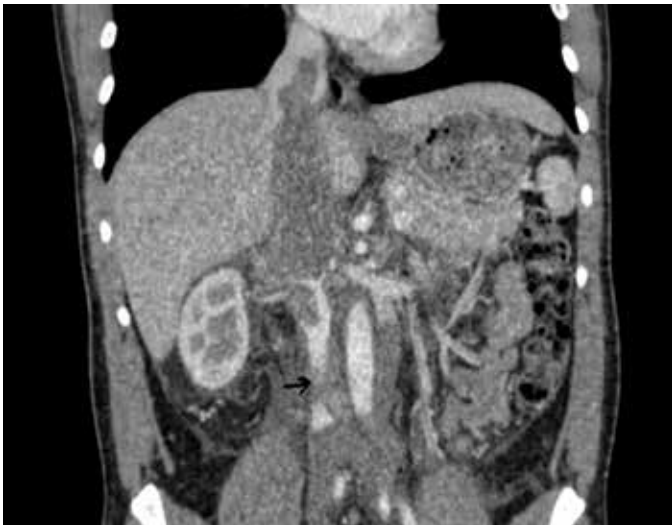**E-mail:** aeatay@hotmail.com **ORCID ID:** orcid.org/0000-0002-3711-5157 **Received:** 08.10.2019 **Accepted:** 18.09.2020

**Cite this article as:** Aras S, Yakın M, Şerifoğlu İ, Ulus İ, Zengin A, Özsoy Ş, Bayır A, Köksal Ü, Atay AE. A Rare Cause of Renal Vein and Inferior Vena Cava Thrombosis: A Case of Embryonal Testicular Carcinoma. Bagcilar Med Bull 2020;5(4):229-231

©Copyright 2020 by the Health Sciences University Turkey, Bağcılar Training and Research Hospital  
Bagcilar Medical Bulletin published by Galenos Publishing House.

both veins (Figure 1). He was referred to our hospital after being initiated anticoagulant therapy in another hospital. Laboratory examination showed high sedimentation rate (55 mm/h), proteinuria (spot urine prot/cre: 1.4 gr) and lactate dehydrogenase: 979 U/L. Patients were hospitalized in internal medicine service and low molecular weight heparin therapy (Clexane® 0.8) was continued. Additional blood analysis indicated elevated levels of alpha fetoprotein (775 ng/m) and beta human chronic gonadotropin (11,011 IU/mL). On physical examination, no significant finding except painless irregular scrotal mass in 5x10 mm size and containing calcifications was observed. He consulted to urology department and underwent surgery.

After uneventful postoperative period, histopathologic examination indicated pure embryonal carcinoma (Figure



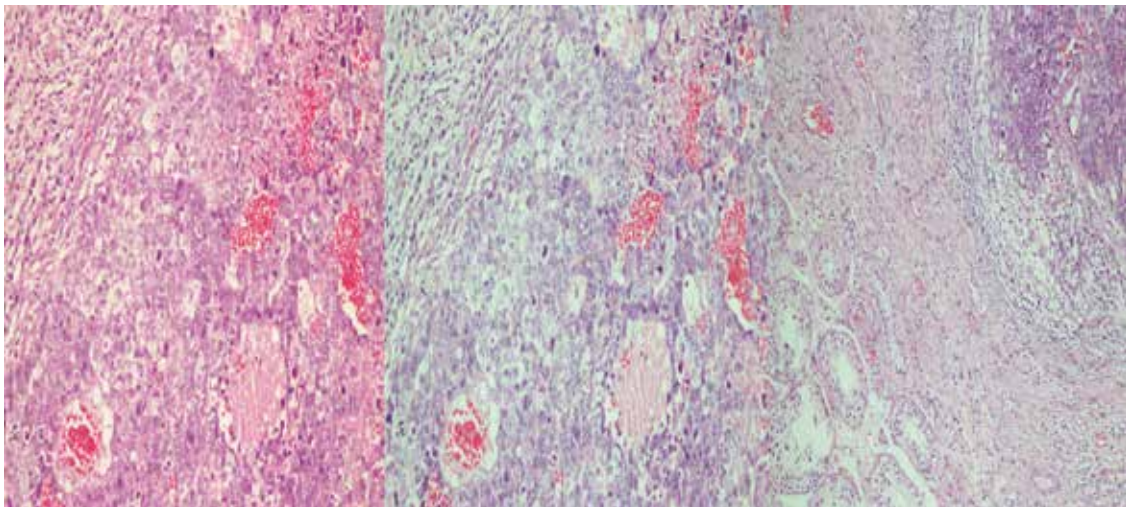
**Figure 1.** Tomographic examination indicating thrombosis in vena cava inferior

2, 3). The patient was referred to medical oncology, and chemotherapy was initiated. Control Doppler ultrasonographic examination pointed out the recovery of occlusion on the vena cava inferior and renal vein.

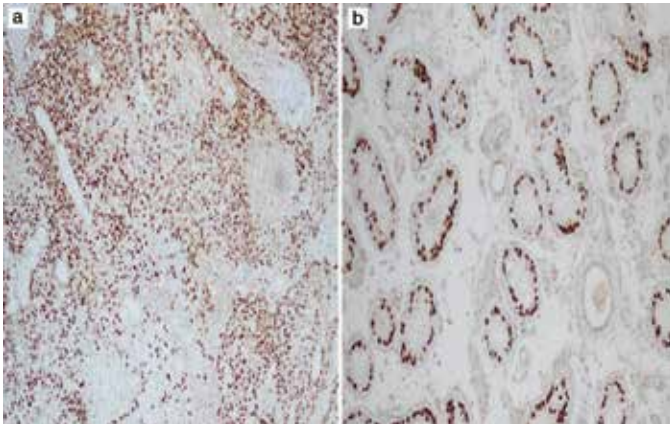
## Discussion

Because approximately 70% of TC are localized in the testicle at the time of diagnosis, thrombosis as a presenting sign of testicular lesion is extremely rare and usually seen in seminomatous cancers related to direct tumor invasion or neoplastic thrombosis (5). Urological cancers constitute approximately %5 of malignancy related thrombosis (6). Germ cell tumors (GCT) has higher tendency to hematogenous spread but inferior vena cava (IVC) invasion of GCT is seen less than %3 in an autopsy series (7). Masui et al. (8) defined risk factors of IVC thrombosis as; right sided testicular tumors with large abdominal mass greater than 5 cm, hepatic metastasis or receiving high dose corticosteroids. The diagnosis of IVC thrombosis is usually done by high index of suspicion in TC patients with retroperitoneal mass >5 cm (9).

The management of GCT associated IVC thrombosis may require multidisciplinary approach. Chemotherapy alone is rarely effective in the resolution of IVC thrombosis in GCT's, and antithrombotic therapy or even thrombectomy is usually required. A case report presented a patient with TC who experienced pulmonary thromboembolism during anticoagulant therapy (10). To minimize the risk of pulmonary thromboembolism, some authors perform IVC filter insertion prior to orchiectomy and chemotherapy (8). Our patient showed a rapid response to anticoagulant therapy, and IVC thrombosis recovered in 4-week period.



**Figure 2.** Tumoral tissue consisting of atypical pleomorphic cells showing mitotic activity (HE x 200)



**Figure 3.** a) OCT 3/4 expression on the tumor cells (OCT 3/4x100), b) OCT 3/4 expression on seminiferous tubules (OCT 3/4x100)

*OCT: Optical coherence tomography*

According to the Hidden study, venous thromboembolism (VTE) is the most frequent preventable cause of death in hospitalized patients (6). Thromboprophylaxis for cancer patients and antithrombotic therapies when a thrombus is detected play vital role to decrease the risk of pulmonary thromboembolism and sudden death.

TCs should be considered in young males presenting with VTE without an evident risk factor for thrombosis. Physical examination of young individuals that are referred with thrombosis plays crucial role, because before starting numerous radiologic interventions and hematologic tests, single scrotal examination may help to establish the diagnosis. Initiation of immediate therapy and collaboration of the departments of internal medicine, urology and cardiovascular surgery are essential in the management of TC patients VTE.

### Ethics

**Informed Consent:** Written consent was received from the patients.

**Peer-review:** Externally peer-reviewed.

### Authorship Contributions

Concept: S.A., A.E.A., Ü.K., Design: S.A., A.E.A., Ü.K., Data Collection or Processing: S.A., M.Y., İ.Ş., İ.U., A.Z., Ş.Ö., Analysis or Interpretation: S.A., A.E.A., Ü.K., A.B., Writing: A.E.A.

**Conflict of Interest:** The authors declare that there is no conflict of interest.

**Financial Disclosure:** No financial support was received from a person or a company.

## References

1. Heidenreich A, Paffenholz P, Nestler T, Pfister D. European Association of Urology Guidelines on Testis Cancer: Important Take Home Messages. *Eur Urol Focus* 2019;5(5):742-744.
2. Siegel RL, Miller KD, Jemal A. Cancer statistics, 2019. *CA Cancer J Clin* 2019;69(1):7-34.
3. Steele GS, Richie JP, Oh WK, Michaelson MD. Clinical manifestations, diagnosis, and staging of testicular germ cell tumors. Up to date, 2019.
4. Kawai T, Tanaka Y, Cancer Registration Committee of the Japanese Urological Association. Clinical characteristics of testicular germ cell tumors in patients aged 50 years and older: A large-scale study from the Cancer Registration Committee of the Japanese Urological Association. *Int J Urol* 2017;24(2):124-128.
5. Ghazarian AA, Trabert B, Devesa SS, McGlynn KA. Recent trends in the incidence of testicular germ cell tumors in the United States. *Andrology* 2015;3(1):13-18.
6. White C, Noble SIR, Watson M, Swan F, Allgar VL, Napier E, et al. Prevalence, symptom burden, and natural history of deep vein thrombosis in people with advanced cancer in specialist palliative care units (HIDDEN): a prospective longitudinal observational study. *Lancet Haematol* 2019;6(2):e79-e88.
7. Bredael JJ, Vugrin D, Whitmore WF Jr. Autopsy findings in 154 patients with germ cell tumors of the testis. *Cancer* 1982;50(3):548-551.
8. Masui S, Onishi T, Arima K, Sugimura Y. Successful management of inferior vena cava thrombus complicating advanced germ cell testicular tumor with temporary inferior vena cava filter. *Int J Urol* 2005;12(5):513-515.
9. Hassan B, Tung K, Weeks R, Mead GM. The management of inferior vena cava obstruction complicating metastatic germ cell tumors. *Cancer* 1999;85(4):912-918.
10. O'Brien WM, Lynch JH. Thrombosis of the inferior vena cava by seminoma. *J Urol* 1987;137(2):303-305.