

# Five-Year Disease-Free Follow-Up of a Borderline Breast Phyllodes Tumor in a 15-year-old Patient

## 15 Yaşında Memenin Borderline Filloides Tümörü Tanılı Hastanın 5 Yıllık Hastaliksız Takibi

Sertaç Ata Güler<sup>1</sup>, M. Ümit Uğurlu<sup>2</sup>, Bahadır M. Güllüoğlu<sup>2</sup>

<sup>1</sup>Department of General Surgery, Kocaeli University Faculty of Medicine, Kocaeli, Turkey

<sup>2</sup>Department of General Surgery, Marmara University Faculty of Medicine, İstanbul, Turkey

### ABSTRACT

Phyllodes tumors are large breast tumors representing only 1% of breast neoplasms and are rarely seen in young women. Histologically, phyllodes tumors are classified as benign, borderline, or malignant based on the characteristics of the stroma. Although wide local excision is recommended for the treatment modality, the recurrence rate after surgical excision varies between 36% and 65%, with recurrence more likely in those with the tumor at the margins of excision. Our aim was to report a case in a 15-year-old girl with a 115-mm borderline phyllodes tumor in her left breast mimicking a juvenile fibroadenoma. We presented a 5-year disease-free follow-up after wide local excision with negative margins.

**Keywords:** Phyllodes tumor, recurrence, breast

### ÖZ

Memenin filloides tümörü, tüm meme tümörlerinin %1'lik kısmını oluşturur ve ender olarak genç kadın hastalarda görülür. Histolojik olarak, filloides tümörleri stromal yapılarının karakteristik özelliklerine göre benign, borderline veya malign olarak sınıflandırılırlar. Tedavi olarak filloides tümörlerinde geniş lokal eksizyon önerilir. Geniş cerrahi lokal eksizyondan sonra nüks %36 ile %65 oranlarında görülebilmektedir. Bu yazıda 15 yaşında genç kadın hastanın sol memesindeki 115 mm boyutunda, juvenil fibroadenoma benzerlik gösteren borderline filloides tümörü olgusu sunulmaktadır. Ayrıca 5 senelik takipte, cerrahi lokal geniş eksizyon ile tedavi edilen borderline filloides tümörünün nüks etmediği, cerrahi sınırı negatif olarak geniş lokal eksizyon ile tedavisinin yeterli olabileceği gösterilmektedir.

**Anahtar sözcükler:** Filloides tümör, nüks, meme

### Introduction

The tumor initially named cystosarcoma phyllodes is now generally known as phyllodes tumor; it only represents approximately 1% of the breast neoplasms, and it is very rare in young women (1). Johannes Müller described it for the first time in 1893. Its name was derived from the Greek words "phyllon," meaning leaf and "eidos," meaning appearance because of its leaf-like pattern (2). The median size of the phyllodes tumors is around 4 cm (3). Twenty percent of tumors grow larger than 10 cm, which is the arbitrary cut-off point for the designation as a giant tumor. These tumors can reach sizes up to 40 cm in diameter (4). Phyllodes tumors represent a rare biphasic neoplasm composed of epithelial and stromal elements, which corresponds to a total of 1% of the breast cancers and around 2%-3% of the fibroepithelial tumors (5-7). Histologically, phyllodes tumors are classified as benign, borderline, or malignant based on characteristics of the stroma (8). They can be found as a breast lump at any age including adolescence. The peak incidence of this tumor in women is between 35 and 55 years of age, with only a few cases reported in men (9, 10). A large series from the M.D. Anderson Cancer Center reported the incidence of phyllodes tumors histologically as benign (58%), intermediate (12%), and malignant (30%) (11). Wide local excision of the lesion with clear margins is considered to be an adequate surgical therapy in benign phyllodes tumors. On the other hand, when the phyllodes tumors are large, a simple mastectomy is recommended. In the case of epithelial injury, size, location, and lymph node involvement are not considered in determining therapeutic approaches (12-14). It is sometimes difficult to preoperatively differentiate fibroadenoma from phyllodes tumor because their clinical features are similar. A phyllodes tumor has stromal hypercellularity, which is different from fibroadenoma, and tends to grow like a leaf as interstitium intensively grows into ducts (15).

The treatment of these types is quite different. Fibroadenomas are generally treated by observation without surgery, whereas phyllodes tumor needs to be removed (16).

Herein, we report a case with a 115 mm borderline phyllodes tumor and its 5-year follow-up without any recurrences.

*Bu çalışma 12. Uluslararası Meme Hastalıkları Kongresi'nde sunulmuştur, 24-27 Ekim 2013, Antalya, Türkiye.*

*This study was presented at the 12<sup>th</sup> International Breast Diseases Congress, 24-27 October 2013, Antalya, Turkey*

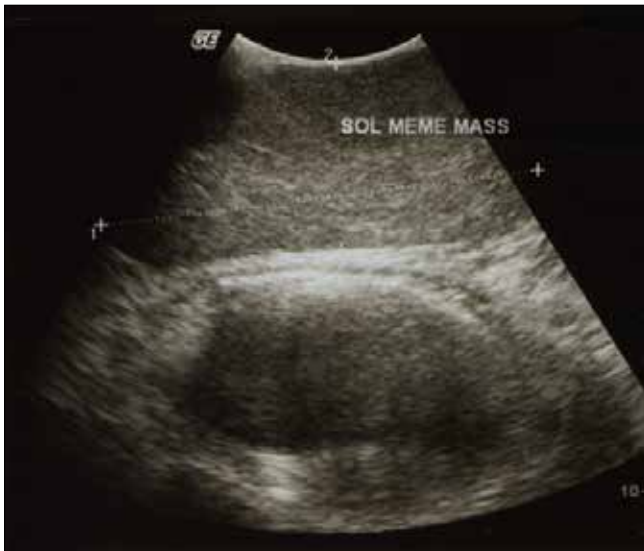### Address for Correspondence / Yazışma Adresi:

Sertaç Ata Güler, Department of General Surgery, Kocaeli University Faculty of Medicine, Kocaeli, Turkey

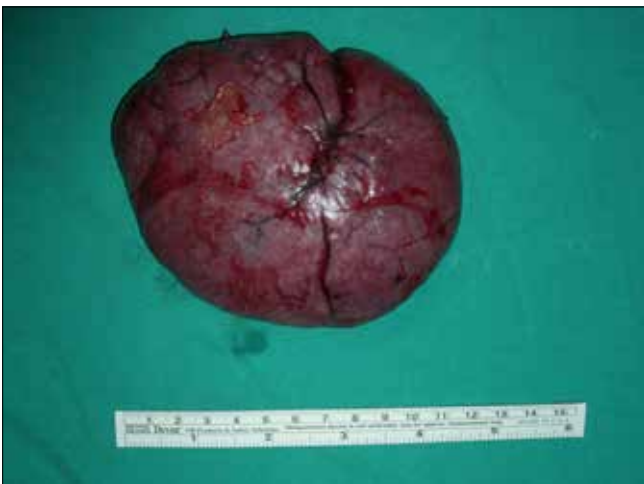Phone / Tel.: +90 505 393 52 40 e-mail / e-posta: drsataguler@me.com

Received / Geliş Tarihi: 11.08.2014

Accepted / Kabul Tarihi: 13.09.2014



**Figure 1.** Ultrasonography in October 2007 showed a regular-shaped hypoechoic mass measuring 100 × 43 mm in diameter

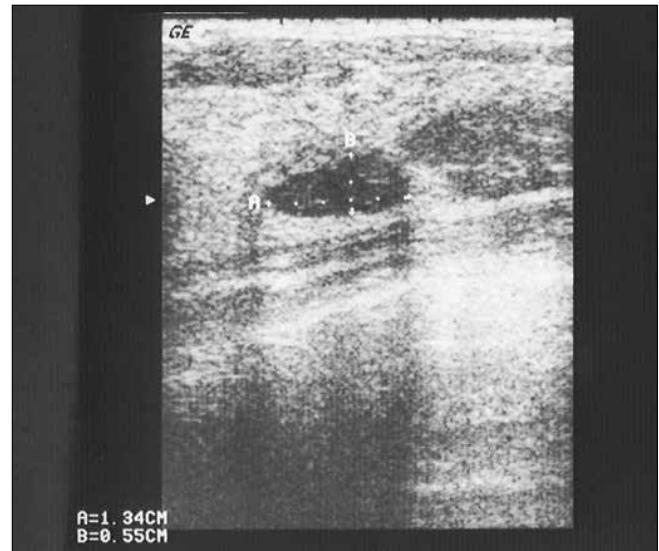


**Figure 2.** 100 mm phyllodes tumor excised from the left breast

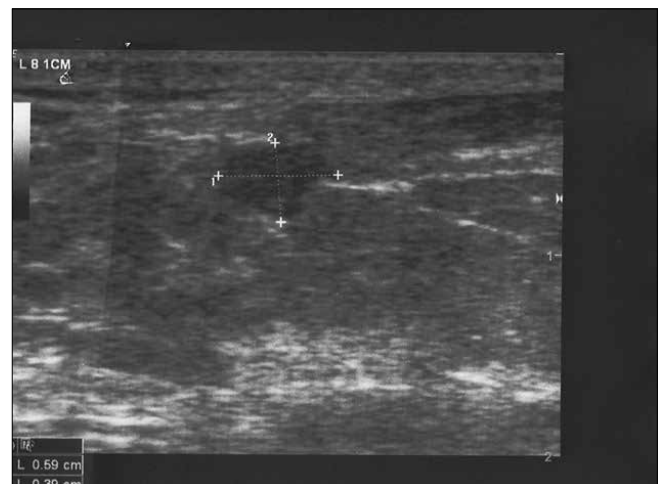
### Case Presentation

A 15-year-old girl was admitted to our breast center with a 3-month history of a left breast lump. Physical examination revealed a non-tender, mobile, and elastic hard mass (100 mm) in the left breast nearly covering all the quadrants. No palpable lymph nodes were present in the axillary and supraclavicular regions. Ultrasonography showed a 100 × 43 mm regular-shaped hypoechoic mass on the left breast nearly covering all quadrants (Figure 1). Core biopsy demonstrated a kind of fibroepithelial lesion having features of benign phyllodes tumor and juvenile fibroadenoma as the differential diagnosis. Based on the diagnosis, the size, and the location of the lesion, we decided to perform wide local surgical excision for the mass in the left breast. The final result showed the presence of a regular-shaped tumor in the left breast, which measured 115 mm in its longest axis with negative surgical margins (Figure 2). Histopathologic evaluation showed a borderline phyllodes tumor which showed three mitosis per 10 high power fields, with average stromal cellularity containing areas of adenosis.

According to the histopathology report, no further treatment was recommended and annual follow-up was performed. Her physical exami-



**Figure 3.** Ultrasonography in the third year follow-up showed a regular-shaped hypoechoic mass measuring 14 × 5 mm in diameter



**Figure 4.** Ultrasonography in the fifth year follow-up demonstrated multiple echogenic cystic lesions; the largest one was 6 mm in diameter in the left breast, which is mostly benign

nation and ultrasonographic investigation were performed every year. In her first ultrasonographic follow-up, there was no lesion observed in the bilateral breasts. In the second year follow-up, a 14 mm regular-shaped hypoechoic mass lesion was found in the contralateral breast (Figure 3). Core biopsy was performed on this contralateral breast lesion, which showed minimal fibrosis. Ultrasonographic follow-up for two more years showed no other lesions on both breasts. At the fifth year, ultrasonography demonstrated multiple echogenic cystic lesions in her left breast, with the largest being 6 mm in diameter, which was diagnosed as benign (Figure 4).

### Discussion and Conclusions

Phyllodes tumors are rare tumors, which account for 1% of all breast neoplasms (1). The tumor typically presents as a painless, well-circumscribed, and mobile mass in women between 35 and 55 years of age (9). They are histologically unique in that they are composed of epithelial and stromal components (17). Phyllodes tumor of the breast is classified as benign, borderline, or malignant subtypes based on features of the tumor such as necrosis, margins (pushing or infiltrative),

cellular atypia, stromal overgrowth, and number of mitoses per high power field (8, 18). Malignancy is determined by characteristics of the stroma, and approximately 30% of phyllodes tumors are diagnosed as malignant. Because phyllodes tumors have a tendency to recur locally and exhibit metastatic behavior, wide local excision or simple mastectomy is recommended as the treatment of choice. Malignant phyllodes tumors recur in the breast at a rate of 65% after local excision and 36% after wide local excision (16, 19).

Although fibroadenomas appear similar to phyllodes tumors, the difference is significant. However, it is often difficult to distinguish them clinically. Phyllodes tumors are larger and enlarge more rapidly than fibroadenomas. They also appear similar to each other on ultrasonographic and mammographic evaluation. In addition, it is not always easy to differentiate them histologically (15).

In our case, we presented a 15-year-old girl, with a phyllodes tumor that had low histopathological malignancy risk. These types of phyllodes tumors are classified as borderline in the literature (8, 18). Based on examples in the literature, we performed a wide local excision to the 100-mm long round-shaped mass in the left breast (19). Our histopathological evaluation described a borderline phyllodes tumor with a low malignancy potential based on histomorphological analysis of three mitosis per 10 high power fields. Malignant phyllodes tumors can behave in a similar manner as sarcomas and develop blood-borne metastases with a poor prognosis; therefore, these patients must be followed up (20).

In our case, the patient had no recurrence or a new primary lesion in the bilateral breast during our 5-year follow-up study. In the contralateral breast, we diagnosed a new mass at the second year follow-up; however, core biopsy revealed it as benign.

In conclusion, borderline phyllodes tumors have a good 5-year disease-free survival. Although they have a histopathologically malignant risk, wide local excision with negative margins and annual follow-up would be the appropriate management therapy for these types of breast pathologies.

**Informed Consent:** Written informed consent was obtained from patient who participated in this study.

**Peer-review:** Externally peer-reviewed.

**Author contributions:** Concept - S.A.G., B.M.G.; Design - S.A.G., B.M.G.; Supervision - B.M.G., M.Ü.U.; Funding - S.A.G., B.M.G., M.Ü.U.; Materials - S.A.G.; Data Collection and/or Processing - S.A.G., B.M.G.; Analysis and/or Interpretation - S.A.G., B.M.G., M.Ü.U.; Literature Review - S.A.G., B.M.G., M.Ü.U.; Writer - S.A.G.; Critical Review - S.A.G., B.M.G., M.Ü.U.

**Conflict of Interest:** No conflict of interest was declared by the authors.

**Financial Disclosure:** The authors declared that this study has received no financial support.

**Hasta Onamı:** Yazılı hasta onamı bu çalışmaya katılan hastalardan alınmıştır.

**Hakem değerlendirmesi:** Dış bağımsız.

**Yazar Katkıları:** Fikir - S.A.G., B.M.G.; Tasarım - S.A.G., B.M.G.; Deneleme - B.M.G., M.Ü.U.; Kaynaklar - S.A.G., B.M.G., M.Ü.U.; Malzemeler - S.A.G.; Veri toplanması ve/veya işlemesi - S.A.G., B.M.G.; Analiz ve/veya yorum - S.A.G., B.M.G., M.Ü.U.; Literatür taraması - S.A.G., B.M.G., M.Ü.U.; Yazıyı yazan - S.A.G.; Eleştirel inceleme - S.A.G., B.M.G., M.Ü.U.

**Çıkar Çatışması:** Yazarlar çıkar çatışması bildirmemişlerdir.

**Finansal Destek:** Yazarlar bu çalışma için finansal destek almadıklarını beyan etmişlerdir.

## References

1. McDaniel Md, Circhlow RW. Cystosarcoma phyllodes. In: Strombek SO, Rosato FE eds. *Surgery of the Breast*. New York Thieme Inc, 1986; 151-152.
2. Lewitan G, Goldberg C, Serro Rde S, Cabaleiro C, Espora SM. Phyllodes tumor in an 11 years-old girl: Report of a case. *Arch Argent Pediatr* 2010; 108:e41-43. (PMID: 20467699)
3. Rowell MD, Perry RR, Jeng-Gwang H, Barranco SC. Phyllodes tumors. *Am J Surg* 1993; 165:376-379. (PMID: 8383473) [CrossRef]
4. Reinfuss M, Mitus J, Duda K, Stelmach A, Rys J, Smolak K. The treatment and prognosis of patients with phyllodes tumor of the breast: an analysis of 170 cases. *Cancer* 1996; 77:910-916. (PMID: 8608483) [CrossRef]
5. Neto GB, Rossetti C, Souza NA, LA Fonseca F, Azzalis LA, Junqueira VB, Valenti VE, de Abreu LC. Coexistence of benign phyllodes tumor and invasive ductal carcinoma in distinct breasts: case report. *Eur J Med Res* 2012; 17:8. (PMID: 22534285) [CrossRef]
6. Sheen-Chen SM, Hsu W, Eng HL, Huang CC, Ko SF. Intratumoral hemorrhage of mammary phyllodes tumor after menstrual induction: a puzzling presentation. *Tumori* 2007; 93:631-633. (PMID: 18338504)
7. Ribeiro-Silva A, Zambelli Ramalho LN, Zucoloto S. Phyllodes tumor with osteosarcomatous differentiation: a comparative immunohistochemical study between epithelial and mesenchymal cells. *Tumori* 2006; 92:340-346. (PMID: 17036527)
8. Tse GMK, Niu Y, Shi H. Phyllodes tumor of the breast: an update. *Breast Cancer* 2010; 17:29-34. (PMID: 19434472) [CrossRef]
9. Salvadori B, Cusumano F, Del Bo R, Delledonne V, Grassi M, Rovini D, Saccozzi R, Andreola S, Clemente C. Surgical Treatment of Phyllodes Tumors of the Breast. *Cancer*; 1989; 63; 2532-2536. [CrossRef]
10. Benhassouna J, Damak T, Gamoudi A, Charqui R, Khomsi F, Mahjoub S, Slimene M, Ben Dhiab T, Hechiche M, Boussen H, Rahal K. Phyllodes tumors of the breast: a case series of 106 patients. *Am J Surg* 2006; 192:141-147. (PMID: 16860620) [CrossRef]
11. Chaney AW, Pollack A, Mcneese M, Zagers K, Pisters P, Pollock RE, Hunt KK. Primary treatment of cystosarcoma phyllodes of the breast. *Cancer* 2000; 89:1502-1511. (PMID: 11013364) [CrossRef]
12. Isimbaldi G, Sironi M, Declich P, Galli C, Assi A. A case of malignant phyllodes tumor with muscular and fatty differentiations. *Tumori* 1992; 78:351-352. (PMID: 1494810)
13. Van de Vijver MJ, Peterse H. The diagnosis and management of pre-invasive breast disease: pathological diagnosis-problems with existing classifications. *Breast Cancer Res* 2003; 5:269. (PMID: 12927038) [CrossRef]
14. Morrow PK, Zambrana F, Esteva FJ. Recent advances in systemic therapy: Advances in systemic therapy for HER2-positive metastatic breast cancer. *Breast Cancer Res* 2009; 11:207. (PMID: 19664181) [CrossRef]
15. Park HL, Kwon SH, Chang SY, Huh JY, Kim JY, Shim JY, Lee YH. Long-term follow-up result of benign phyllodes tumor of the breast diagnosed and excised by ultrasound-guided vacuum-assisted breast biopsy. *J Breast Cancer* 2012; 15:224-229. (PMID: 22807941) [CrossRef]
16. Tomimaru Y, Komoike Y, Egawa C, Motomura K, Inaji H, Kataoka TR, Koyama H. A case of phyllodes tumor of the breast with a lesion mimicking fibroadenoma. *Breast Cancer* 2005; 12:322-326. (PMID: 16286914) [CrossRef]
17. Noguchi S, Aihara T, Motomura K, Inaji H, Imoaka S, Koyama H, Kasugai T, Wada A. Phyllodes Tumor of the Breast: Pathology, Histogenesis, Diagnosis, and Treatment. *Breast Cancer*. 1996; 3:79-92. (PMID: 11091559) [CrossRef]
18. Grove A, Deibjerg Kristensen L. Intraductal carcinoma within a phyllodes tumor of the breast: a case report. *Tumori*. 1986; 72:187-190. (PMID: 3010519)
19. Barth RJ. Histological features predict local recurrence after breast conserving therapy of phyllodes tumors. *Breast Cancer Res Treat*. 1999; 57:291-295. (PMID: 10617306) [CrossRef]
20. Stebbing JF, Nash AG. Diagnosis and management of phyllodes tumor of the breast: experience of 33 cases at a specialist center. *Ann R Coll Surg Engl* 1995; 77:181-194. (PMID: 7598414)