

Possible Synchronous Lung Metastasis of Breast Mass Detected Using Breast Ultrasonography: A Report of Two Cases

Ultrasonografik olarak saptanan meme kitlesinden kaynaklanan eşzamanlı olası akciğer metastazı: İki olgu sunumu

Tümay Bekci

Ondokuz Mayıs Üniversitesi Tıp Fakültesi, Radyoloji Anabilim Dalı, Samsun, Türkiye

ABSTRACT

Ultrasonography (US), which is used for the diagnosis of breast cancer and the evaluation of its local metastasis, has proven its worth as a diagnostic method. In breast ultrasonographic examination peripherally localized metastatic lesions at the posterior of the screened breast tissue can also be detected. In this case report, two female patients whose breast ultrasonography showed lumps. Their peripheral lung metastases were screened ultrasonographically, and the patients were diagnosed in a timely manner. Ultrasonographic examination at a patient's first appointment – and especially during routine check-ups after the primary treatment – can allow an early diagnosis of peripherally localized lung metastasis at the posterior of the screened breast tissue and make a vital contribution to the patient's prognosis.

Keywords: Breast cancer, lung metastasis, breast ultrasound

ÖZ

Ultrasonografi meme kanserinin tanısında ve lokal yayılımının değerlendirilmesinde başvurulan ve etkinliği kanıtlanmış bir yöntemdir. Meme US incelemesinde görüntüleme alanına giren meme dokusunun posteriorundaki periferik yerleşimli metastatik akciğer kitleleri de ultrasonografi ile tespit edilebilir. Bu olgu sunumunda da meme ultrasonografik incelemesinde meme kitlesi tespit edilen iki kadın hastada periferik akciğer metastazları ultrasonografik olarak görüntülenmiş ve hastalığa zamanında tanı konmuştur. Hastanın ilk başvurusunda ve özellikle primer tedavinin ardından yapılan rutin kontroller esnasında yapılacak ultrasonografi incelemesi incelenen meme dokusunun posteriorunda göğüs duvarına komşu periferik yerleşimli akciğer metastazlarının erken saptanmasını sağlayabilir ve uygun tedavi ile hastaların prognozuna hayati katkıda bulunulabilir.

Anahtar sözcükler: Meme kanseri, akciğer metastazı, meme ultrasonografisi

Introduction

Despite significant developments in its diagnosis and treatment, breast cancer is still the second most common cause of death in women (1). Although mammography is the most widely used screening method in the general population, the clinical use of ultrasonography (US) and its contribution to the detection of breast cancer has been increasing daily (1). The size of a tumor determined through ultrasonographic examination can have significant effects on lymph node metastasis, and on the planning and prognosis of distant metastasis treatment (2). There is no information in the literature about the use of US in the detection of lung, or distant, metastasis although this has the potential to completely change the treatment schedule. This case report details how ultrasonography can also be used to detect peripheral lung metastasis of breast cancer, which is localized at the posterior of the screened breast tissue.

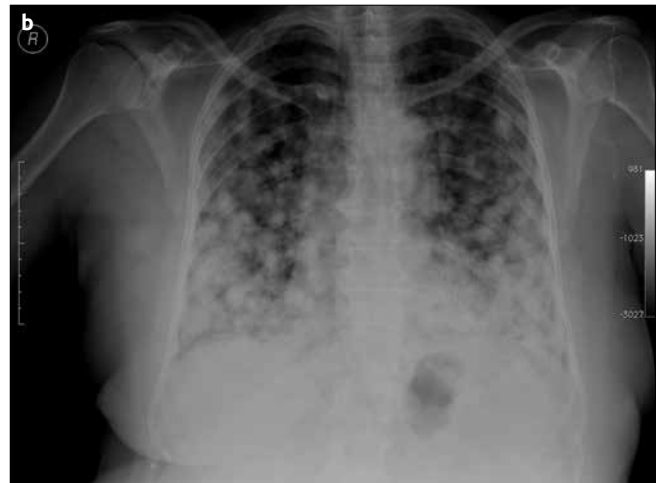
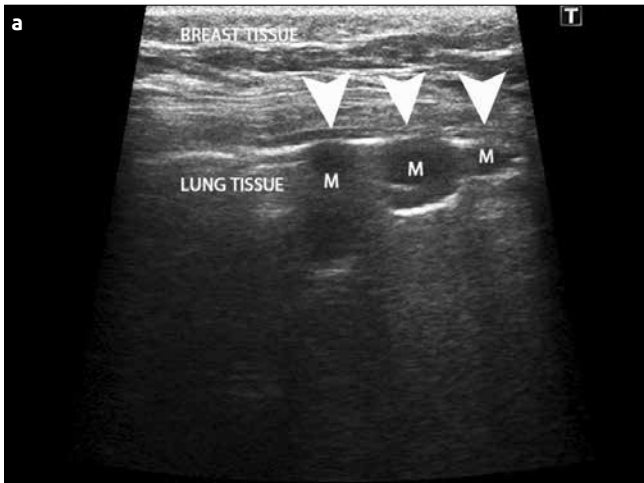
Case Presentation

Case 1

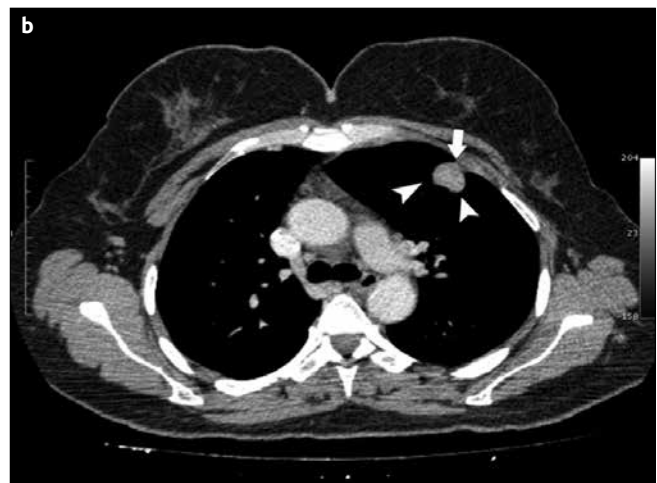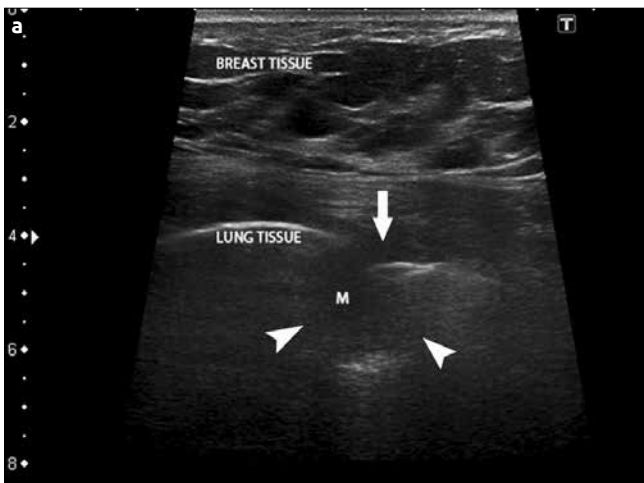
A 38-year-old female patient came to our breast screening unit with a complaint of swelling in the breast. On physical examination, a palpable painless mass detected on the right upper quadrant of the breast. The ultrasonographic examination, performed using a Toshiba Aplio XG SSA-790A ultrasonography device (Toshiba Medical Systems Corporation, Otawara, Japan) and a 7.5-Mhz high-frequency linear probe, detected a 3-cm hypoechoic malignant-appearing mass lesion with an irregular contour and infiltrative pattern on the upper outer quadrant of the right breast. There were metastatic lymphadenopathies in the right axillary region. The images showed a large number of nodular mass lesions in the peripheral region of the right lung (Figure 1a). Chest X-ray showed a large number of nodular lesions in the both lung (Figure 1b). Thus, after written consent was obtained from the patient, an ultrasound-guided Tru-Cut biopsy was performed on the patient's breast lump and lung mass lesion. The breast lump was invasive ductal carcinoma, and the lung lesions were breast carcinoma metastases.

Case 2

A 43-year-old female patient came to our breast screening unit with a complaint of swelling in the breast. On physical examination, a painless palpable immobile mass lesion detected on the left breast's lower mid quadrant. The ultrasonographic examination, performed



Resim 1. a, b. a) Ultrasonographic examination detected mass lesions compatible with nodular metastasis, which were peripherally localized, adjacent to the visceral pleura and mobile during respiration in the lung parenchymal under the breast tissue (arrowheads). b) Chest X-ray shows a large number of nodular lesions in the both lung.



Resim 2. a, b. a) Ultrasonographic examination detected metastatic mass lesions compatible with nodular metastasis, which were peripherally localized, adjacent to the visceral pleura under the breast tissue (arrowheads). The fact that the lump was mobile during respiration was seen to indicate that it was not a parietal pleura invasion (arrow). b) The lung CT to check for metastasis detected a nodular mass lesion adjacent to the pleura under the breast tissue on the left lung (arrowheads, arrow).

using a Toshiba Aplio XG SSA-790A ultrasonography device (Toshiba Medical Systems Corporation, Otawara, Japan) and a 7.5-Mhz high-frequency linear probe, detected a 23x17-mm hypoechoic malignant-appearing mass lesion with an irregular contour on the lower mid quadrant of the left breast. Ultrasonographic examination showed a mobile hypoechoic lesion, which was compatible with mobile hypoechoic lump metastasis, on the peripheral region of the left lung and adjacent to the pleura (Figure 2a). Because the lump in the lung was mobile during respiration, it was interpreted as having not invaded the parietal pleura. The patient, who was thought to have lung metastasis, had a lung CT, and two metastatic nodular lump lesions were found on different lobes of the left lung (Figure 2b). After written consent was obtained from the patient, an ultrasound-guided Tru-Cut biopsy was performed on the breast lump, and histopathological analysis revealed that the diagnosis was invasive ductal carcinoma.

Discussion and Conclusion

In US, breast cancer is typically seen as a hypoechoic mass lesion with an infiltrative pattern, which causes acoustic shadowing on the posterior (2). With ultrasonographic breast examination, the lump size,

multifocality, multicentricity, axillary metastasis, and the presence of distant metastasis can be evaluated. Ultrasonographic local staging is widely used as it helps to determine the surgical treatment required (3). Axillary lymph node metastasis, which is an important indicator of a patient's prognosis, can be evaluated in detail with US. Research has shown that it decreases false-negative rates in the detection of sentinel lymph nodes (1). Moreover, ultrasound-guided biopsies can be performed on suspicious lymph nodes that are seen during ultrasonographic examination, while ultrasonographic preoperative staging helps to determine the kind and schedule of the treatment. In the case of the presence of breast cancer's distant metastasis, the whole treatment schedule changes, and early diagnosis is therefore important. When a lump is found in the breast during ultrasonographic examination at a patient's first appointment, peripheral lung metastasis behind the breast tissue can be detected. In our cases, peripheral lung metastases were detected in good time, and synchronously with breast cancer lump using ultrasonography during the first US screening of the patients. Especially during the follow-up of patients who have had operations for breast cancer, the operated breast can be evaluated with ultrasound and potential peripheral lung metastasis can be detected.

Ultrasonographic examination is superior to mammography since it can also evaluate axillary, and adjacent lung tissues as well as breast tissue. Moreover, since US enables dynamic screening, the invasion of lung metastasis to the pleura can also be examined. Lumps that are immobile during respiration are considered to have invaded the parietal pleura (4). In our second case, the movements of the lump were followed in real time during respiration, and it was possible to say that it had not invaded the parietal pleura. Although it is rarely seen, breast metastasis of primary lung cancer can imitate breast cancer and breast cancer's lung metastasis (5, 6). Thus, the US-guided Tru-Cut biopsy can diagnose the tissue.

In general, patients who have had breast cancer operations have follow-ups with mammography and US. Breast cancer can present as a local recurrence, bone metastasis, and lung metastasis during the postoperative period (7). Especially in this group of patients, since additional screening modalities are not used during follow-ups, through an ultrasonographic examination, peripheral lung metastasis, which can appear years after primary treatment, can be detected early (7). Research shows that surgical metastasectomy makes a positive contribution to the prognosis in cases where lung metastases are detected early (7).

This case series emphasizes that, ultrasonography, which is successfully and safely used in the detection of breast cancer and the evaluation of its local metastasis, can also be used to detect peripheral breast cancer lung metastasis localized at the posterior of the screened breast tissue.

Informed Consent: Written informed consent was obtained from patients who participated in this case.

Peer-review: Externally peer-reviewed.

Financial Disclosure: The author declared that this study has received no financial support.

Conflict of Interest: No conflict of interest was declared by the author.

Hasta Onamı: Yazılı hasta onamı bu olguya katılan hastalardan alınmıştır.

Hakem değerlendirmesi: Dış bağımsız.

Çıkar Çatışması: Yazar çıkar çatışması bildirmemişlerdir.

Finansal Destek: Yazar bu çalışma için finansal destek almadıklarını beyan etmişlerdir.

References

1. Drukker K, Giger M, Meinel LA, Starkey A, Janardanani J, Abe H. Quantitative ultrasound image analysis of axillary lymph node status in breast cancer patients. *Int J Comput Assist Radiol Surg* 2013; 8:895-903. (PMID: 23526445) [[CrossRef](#)]
2. Yang WT. Staging of breast cancer with ultrasound. *Semin Ultrasound CT MR*. 2011; 32:331-341. (PMID:21782123) [[CrossRef](#)]
3. Rahbar H, Partridge SC, Javid SH, Lehman CD. Imaging axillary lymph nodes in patients with newly diagnosed breast cancer. *Curr Probl Diagn Radiol* 2012; 41: 149-158. (PMID:22818835) [[CrossRef](#)]
4. Rumende CM. The role of ultrasonography in the management of lung and pleural diseases. *Acta Med Indones* 2012; 44:175-183. (PMID:22745151)
5. Welter S, Jacobs J, Krbek T, Tötsch M, Stamatis G. Pulmonary metastases of breast cancer. When is resection indicated? *Eur J Cardiothorac Surg* 2008; 34:1228-1234. (PMID:18824371) [[CrossRef](#)]
6. Mirrielees JA, Kapur JH, Szalkucki LM, Harter JM, Salkowski LR, Strigel RM, et al. Metastasis of primary lung carcinoma to the breast: a systematic review of the literature. *J Surg Res* 2014; 188:419-431. (PMID:24560348) [[CrossRef](#)]
7. Takaaki Fujii, Reina Yajima, Ei Yamaki, Takayuki Kohsaka, Satoru Yamaguchi, Soichi Tsutsumi, et al. Pulmonary metastasis from breast cancer with an 18-year disease-free interval: implication of the role of surgery. *Int Surg* 2012; 97:281-284. (PMID:23294064) [[CrossRef](#)]