

MYOFIBROBLASTOMA ACCOMPANIED WITH BILATERAL GYNECOMASTIA

BİLATERAL JİNEKOMASTİYE EŞLİK EDEN MİYOFİBROBLASTOM

Aynur Solak¹, İlhami Solak², Berhan Genç¹

¹Department of Radiology, Şifa University Hospital, İzmir, Turkey

²Department of General Surgery, Faculty of Medicine, Ege University, İzmir, Turkey

ABSTRACT

Myofibroblastoma (MFB) of the breast is an uncommon benign tumor. It is more common in men. In this report we present a case of an 65 year old male patient presenting with a firm breast lump diagnosed as myofibroblastoma and confirmed by diffuse positivity of CD34 immunohistochemical stain. Our patient had radical orchiectomy surgery about four years previously and he received estrogen therapy. Therefore, he had bilateral gynecomastia. The breast lump had grown in the previous four years, also. To the best of our knowledge, only one case of myofibroblastoma arising in a context of bilateral gynecomastia has been reported in the literature.

Key words: Myofibroblastoma, male, breast, ultrasonography

ÖZET

Miyofibroblastom memenin nadir rastlanılan benign tümördür. Erkeklerde kadınlara nazaran daha sık görülmektedir. Bu yazıda memede sert kitle olarak kendini gösterip miyofibroblastom tanısı alan ve CD34 immunhistokimyasal boyamada güçlü pozitifliği ile tanısı doğrulanan 65 yaşındaki erkek hastayı sunuyoruz. Hastamız 4 yıl önce prostat karsinomu ön tanısıyla orşiektomi operasyonu geçirmiş ve östrojen tedavisi almıştır. Bu nedenle olguda bilateral jinekomaсти mevcuttur. Hastamızın memedeki kitlesi de son 4 yıldır büyümüştür. Bildiğimiz kadarıyla literatürde jinekomaстиye eşlik eden miyofibroblastom yalnızca bir olgu sunulmuştur.

Anahtar sözcükler: Miyofibroblastom, erkek, meme, ultrasonografi

Myofibroblastoma of the breast is a rare, benign tumor with mesenchymal in origin (1). It was first described by Wagortz et al. (2) in 1987. It is most commonly seen in middle-aged or elderly men, rare in women. Although the presence of rich literature knowledge including histopathological findings about this pathology, there are only a few reports in the radiological literature (3-5). Here, we report the radiological appearance of a case of breast myofibroblastoma diagnosed by ultrasound guided tru-cut biopsy, associated with histological findings. Our case have been followed up about 1 year after the histological diagnosis.

Case Report

A 65 year-old-male patient presented with a complaint of a painless breast lump located in the lower inner-quadrant of the left breast. The lesion was firm and mobile on physical examination, there were hyperemia and multiple telangiectasies on the skin covering the lesion. No axillary lymph nodes were palpable and his body temperature was normal. He had bilateral gynecomastia. Four years earlier, he underwent radical prostatectomy followed by bilateral orchiectomy, for prostate cancer. The patient received hor-

monal therapy (double combination of an LH-RH analog: goserelin, antiandrogen: finasterid) for fourteen months. He reported the lump had grown rapidly after the hormonal therapy. His past medical history included type 2 diabetes mellitus, COPD, hypertension, and ischemic heart disease. The family history was unremarkable. A chest Computed Tomography (CT) scan (taken for a chronic cough) revealed a 7x4.5 cm, ovoid, non-enhancing, well-demarcated solid mass (Figure 1A). Bilateral gynecomastia with dendritic pattern was seen on coronally reformatted images (Figure 1B). Ultrasound (US) examination revealed a 73x41x46 mm, homogeneous hypoechoic, well-demarcated solid mass. The mass had no identifiable capsule or cystic component (Figure 2A). Color doppler imaging showed no vascularity in the mass except for low-velocity venous flow in one focus (Figure 2B). US-guided tru-cut biopsy was carried out for a definite histological diagnosis. Histopathological examination revealed that the lesion was composed of hypercellular spindle-shaped cells with interspersed broad bands of collagen (Figure 3A). Immunohistochemistry was strongly positive for CD34 (Figure 3B), estrogen, positive for desmin and smooth muscle actin, and negative for S100 and keratin. Conclusive diagnosis of

myofibroblastoma was made based on the above findings. After one year follow-up period, the patient remains well. The sizes and configuration of the mass remained unchanged.

Discussion

Breast myofibroblastoma is an extremely rare, benign, slow-growing mass, usually solitary and unilaterally located. It commonly occurs in the fifth-sixth decades in men. Its incidence among women has increased with the use of mammographic-screening (6, 7). Mammography usually shows an ovoid shaped, well-circumscribed benign lesion, without evidence of pathologic microcalcification. On ultrasonographic examination the lesion appears as a homogeneously hypoechoic solid, sometimes contains cystic spaces, without a capsule formation. It has poor vascularity (5, 8-10). The sonographic features of our patient's lesion were similar to the findings reported in the literature. It was similar to a fibroadenoma. Color doppler ultrasound examination showed no vas-

cularity except for a peripherally located low-velocity venous flow. Normal male breast tissue may contain ductuli and lobuli. Development of a fibroadenoma in it is not possible due to lack of lobular unit. Sometimes lobular transformation may be seen as a result of long-term estrogen therapy. Rarely, fibroepithelial lesions such as a fibroadenoma and phylloid tumor can be seen in these patients (11, 12). Based on radiological findings, we thought that our patient's mass was more likely a fibroma, it was less likely a fibroadenoma due to estrogen therapy. We never considered the possibility of malignancy in the first place. Histological evaluation of the lesion showed no glandular breast tissue.

Pathological examination of the biopsy sample is the only definitive diagnostic method for myofibroblastoma due to the non-specific radiological findings described above (4, 6, 13). Myofibroblasts are benign stromal cells that can be found in different places in the body, even in the skin, meninges, pleura, lymph nodes and they

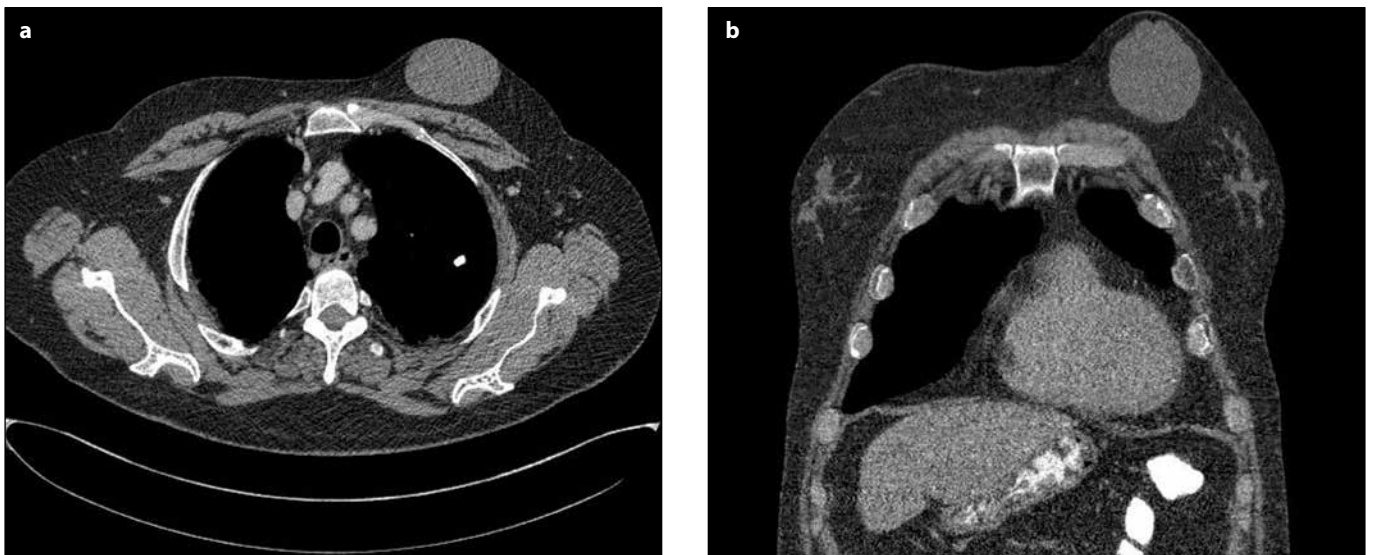


Figure 1. a) Axial CT scan (mediastinal window level) reveals a well-demarcated, homogeneous solid mass lesion in the left breast. **b)** Coronally reformatted image shows bilateral gynecomastia and the lump in the same section.

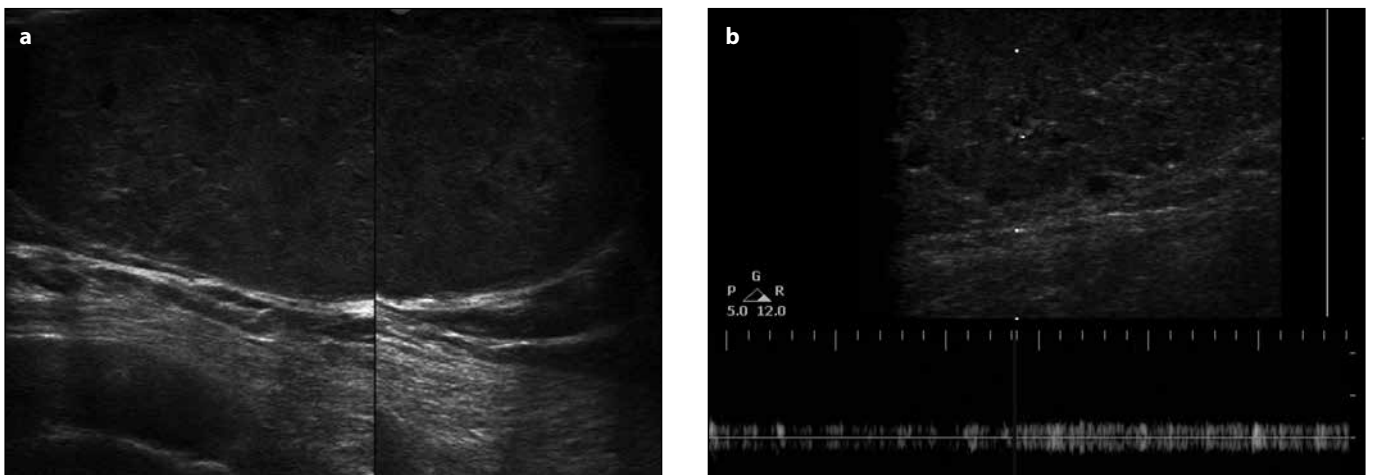


Figure 2. a) Ultrasound examination shows a 73x46x41 mm in diameter, homogeneous hypoechoic, solid mass without capsule formation. **b)** Color Doppler Imaging shows low-velocity venous flow in the mass.

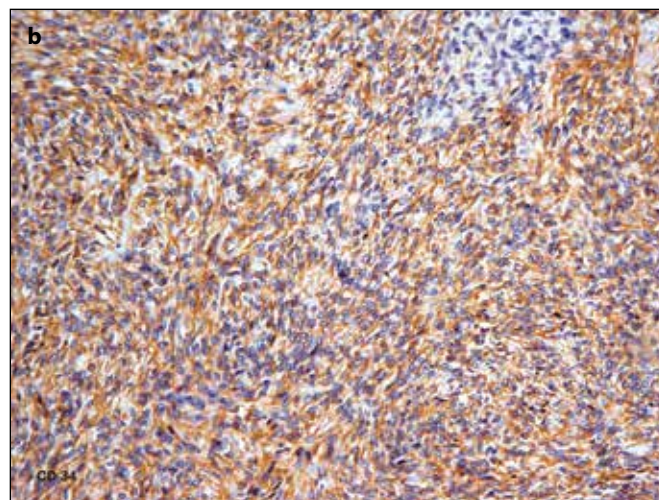
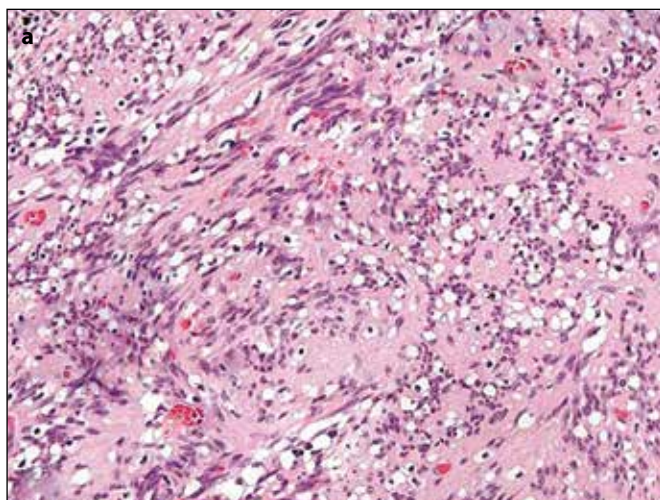


Figure 3. a) Histopathological examination reveals the lesion composed of hypercellular spindle-shaped cells with interspersed broad bands of collagen. **b)** Immunohistochemical staining is strongly positive for CD34.

have been found to be responsible for wound contraction. These cells, that contain characteristic features of smooth muscle and fibroblasts, were typically interspersed thick bands of collagen. Lack of mitotic activity (or rare), anaplasia and cellular atypia are the essential features in the differential diagnosis between malignant stromal tumor. In immunohistochemical staining, positivity for CD34 and desmin, negativity for S100 and cytokeratin confirm the diagnosis (2-4, 14-16). In our patients' histopathological specimen, hypercellular spindle shaped cells (myofibroblasts) separated by broad collagen bands were seen. The mass was strongly positively stained with CD34 (Figure 3 A, B).

Leiomyoma, due to its close location to the areola and schwannoma with radiological findings of benign soft tissue tumors, should be considered in the differential diagnosis. Leiomyomas are usually localized in the retroareolar region, well-defined nodular lesions. Schwannoma cells sometimes may resemble a myofibroblastoma morphologically. They can be distinguished only by immunohistochemical staining (schwannoma has strongly positivity for S100) (13, 16, 17).

Myofibroblastomas are slowly growing lesions that rarely exceed 10 cm in size. It is thought that estrogen receptors play particularly important roles in their growth (2, 5, 9). In our patient, growth

of the estrogen receptor-positive mass has been accelerated due to hormonal therapy. Gynecomastia also occurred after hormonal therapy. There have been only a few cases of myofibroblastoma associated with gynecomastia reported in the literature. However, the exact cause of this association was disclosed (18).

Total excision of the lesion is the correct treatment. If the growth of the lesion stops, it can be monitored clinically since there is no risk of malignant transformation (18-20). Our patient was called twice with 6-month intervals for control examination. We detected no change in the size and configuration of the mass.

In conclusion, in the diagnosis of slowly growing, firm, mobile and well-defined male breast lesions which have all findings closely similar to fibroadenoma except for the lack of capsule, myofibroblastoma must be considered primarily. The differential diagnosis includes schwannoma, leiomyoma, fibroma, less likely fibroepithelial tumors. Definitive diagnosis can be made only by immunohistochemical methods.

Conflict of interest

No conflict of interest was declared by the authors.

References

1. Mele M, Jensen V, Wronneck A, Lelkaitis G. Myofibroblastoma of the breast: Case report and literature review. *Int J Surg Case Rep* 2011; 2: 93-6. (PMID: 22096693) [CrossRef]
2. Wargotz ES, Weiss SW, Norris HJ. Myofibroblastoma of the breast: Sixteen cases of a distinctive benign mesenchymal tumor. *Am J Surg Pathol* 1987; 11: 493-502. (PMID: 3037930) [CrossRef]
3. Landeyro J, Díaz ML, Raventós A, Vadillo J, Martínez MS. Cytological diagnostic clues in fine needle aspiration of breast myofibroblastoma: a case report. *Diagn Cytopathol* 2012; 40: 1107-11. (PMID: 21548123) [CrossRef]
4. López-Ríos F, Burgos F, Madero S, Ballestín C, Martínez-González MA, de Agustín P. Fine needle aspiration of breast myofibroblastoma. A case report. *Acta Cytol* 2001; 45: 381-4. (PMID: 11393070) [CrossRef]
5. Dockery WD, Singh HR, Wilentz RE. Myofibroblastoma of the male breast: imaging appearance and ultrasound-guided core biopsy diagnosis. *Breast J* 2001; 7: 192-4. (PMID: 11469935) [CrossRef]
6. Magro G. Mammary myofibroblastoma: a tumor with a wide morphologic spectrum. *Arch Pathol Lab Med* 2008; 132: 1813-20. (PMID: 18976021)
7. Sharma A, Sen AK, Chaturvedi NK, Yadav R. Myofibroblastoma of male breast: a case report. *Indian J Pathol Microbiol* 2007; 50: 326-8. (PMID: 17883059)

8. Greenberg JS, Kaplan SS, Grady C. Myofibroblastoma of the breast in women: Imaging appearances. *AJR Am J Roentgenol* 1998; 171: 71-2. (PMID: 9648767) [\[CrossRef\]](#)
9. Vourtsi A, Kehagias D, Antoniou A, Mouloupoulos LA, Deligeorgi-Politi H, Vlahos L. Male breast myofibroblastoma and MR findings. *J Computer Assist Tomogr* 1999; 23: 414-6. (PMID: 10348448) [\[CrossRef\]](#)
10. Gnhan-Bilgen I, Bozkaya H, Ustn EE, Memiř A. Male breast disease: clinical, mammographic, and ultrasonographic features. *Eur J Radiol* 2002; 43: 246-55. (PMID: 12204407) [\[CrossRef\]](#)
11. Kanhai RC, Hage JJ, van Diest PJ, Bloemena E, Mulder JW. Short-term and long-term histologic effects of castration and estrogen treatment on breast tissue of 14 male-to-female transsexuals in comparison with two chemically castrated men. *Am J Surg Pathol* 2000; 24: 74-80. (PMID: 10632490) [\[CrossRef\]](#)
12. Appelbaum AH, Evans GF, Levy KR, Amirkhan RH, Schumpert TD. Mammographic appearances of male breast disease. *Radiographics* 1999; 19: 559-68. (PMID: 10336188)
13. Yitta S, Singer CI, Toth HB, Mercado CL. Image presentation. Sonographic appearances of benign and malignant male breast disease with mammographic and pathologic correlation. *J Ultrasound Med* 2010; 29: 931-47. (PMID: 20498468)
14. Arsenovic N, Abdullah KE, Shamim KS. Mammary-type myofibroblastoma of soft tissue. *Indian J Pathol Microbiol* 2011; 54: 391-3. (PMID: 21623101) [\[CrossRef\]](#)
15. Qureshi A, Kayani N. Myofibroblastoma of breast. *Indian J Pathol Microbiol* 2008; 51: 395-6. (PMID: 18723968) [\[CrossRef\]](#)
16. Meguerditchian AN, Malik DA, Hicks DG, Kulkarni S. Solitary fibrous tumor of the breast and mammary myofibroblastoma: the same lesion? *Breast J* 2008; 14: 287-92. (PMID: 18384484) [\[CrossRef\]](#)
17. Shibata S, Imafuku S, Tashiro A, Gondo CH, Toyoshima S, Furue M. Leiomyoma of the male nipple. *J Dermatol* 2011; 38: 727-9. (PMID: 21352311) [\[CrossRef\]](#)
18. Yoo CC, Pui JC, Torosian MH. Myofibroblastoma associated with bilateral gynecomastia: a case report and literature review. *Oncol Rep* 1998; 5: 731-3. (PMID: 9538186)
19. Llaverias Borrell S, Martinez Jimenez AM, Gallart Ortuno A. Solution to case 8. Myofibroblastoma of the breast. *Radiologia* 2009; 51: 527-8. (PMID: 19800486) [\[CrossRef\]](#)
20. Pina L, Apesteguía L, Cojo R, Cojo F, Arias-Camisión I, Rezola R, et al. Myofibroblastoma of the male breast: report of three cases and review of the literature. *Eur Radiol* 1997; 7: 931-4. (PMID: 9228111) [\[CrossRef\]](#)

Correspondence / Yazıřma Adresi

Aynur Solak
Phone : +90 (232) 446 08 80
E-mail : aynursolak@yahoo.com