

INVASIVE LOBULAR CARCINOMA: THE CONCORDANCE OF PATHOLOGIC TUMOR SIZE WITH MAGNETIC RESONANCE IMAGING

Hatice Gümüő¹, Philppa Mills², Sue Jones³, Peter Jones³, David Fish⁴, Metehan Gümüő⁵, Haresh Devalia³, Ali Sever²

¹Dicle Üniversitesi Tıp Fakültesi, Radyoloji Anabilim Dalı, Diyarbakır, Türkiye

²Maidstone Hospital, Radiology, Kent, İngiltere

³Maidstone Hospital, Surgery, Kent, İngiltere

⁴Maidstone Hospital, Pathology, Kent, İngiltere

Sunulduđu Kongre: Türk Radyoloji Kongresi, 2011.

İNVAZİV LOBULER KARSİNOMA: MANYETİK REZONANS GÖRÜNTÜLEME İLE PATOLOJİK TÜMÖR BOYUTUNUN UYUMU

ÖZET

Amaç: Bu çalışmanın amacı, invaziv lobuler kanserin (İLK) varlığını, yayılımını ve multifokalitesini belirlemede manyetik rezonans görüntülemenin (MRG) mamografi ve ultrasonografi ek olarak değerini tespit etmektir.

Yöntem ve gereçler: Mamografi, ultrasonografi ve MRG ile tespit edilmiş, histopatolojik olarak tanı konulmuş 38 İLK tanılı lezyonu retrospektif olarak değerlendirdik. Görüntülemedeki tümörün boyutu, multifokalitesi ve multisentrisitesi kaydedildi. Bulgular final patolojide tümör büyüklüğü ile karşılaştırıldı.

Bulgular: Hastaların ortalama yaşı 63 (aralık; 45–85) yıl idi. Tüm görüntüleme yöntemleri her bir hasta için yapıldı. İLK'nın belirlenmesindeki sensitivite ultrasonografi (%95) ve mamografi (%84) ile karşılaştırıldığında MRG'de (%100) daha iyiydi. MRG, mamografi ve ultrasonografi ile tespit edilemeyen, 7 hastada (%18,4) multifokal tümörü ve bir hastada (%2,6) kontralateral tümörü tespit etti. MRG'de 11 tümör olduğundan büyük, üç tümör olduğundan küçükdü. Ultrasonografide 3 tümör olduğundan büyük, 18 tümör olduğundan küçükdü. Mamografide 2 tümör olduğundan büyük, 17 tümör olduğundan küçükdü. Görüntüleme ile patolojideki tümör boyutunun uyumu MRG'de mamografi ve ultrasonografiden daha iyiydi ($p = 0,026$).

Sonuç: İLK'nın patolojideki tümör boyutu ile uyumunda ve tümörün belirlenmesindeki sensitivitede, MRG, mamografi ve ultrasonografiden daha iyidir. MRG, multifokal ve kontralateral tümörün tespitinde mamografi ve ultrasonografiye üstündür.

Anahtar sözcükler: karsinoma, lobuler, kanser, mamografi, ultrasonografi, manyetik rezonans görüntüleme

ABSTRACT

Purpose: The purpose of this study was to determine the adjunct value to mammography and ultrasonography of magnetic resonance imaging (MRI) in determining the presence, extent and multifocality of invasive lobular cancer (ILC).

Materials and methods: We retrospectively reviewed 38 ILC lesions that had been detected by mammography, ultrasonography, MRI and that had been diagnosed on the basis of histopathological analysis. The size, presence of multifocality and multicentricity of the tumors were recorded at imaging. The findings were compared with the final pathological size. Results: The mean age of the patients was 63 (range;45–85) years. All of the imaging modalities were performed on each patient. The sensitivity of the detection of ILC was much better with MRI (100%) compared to ultrasonography (95%) and mammography (84%). MRI identified multifocal tumor in seven patients (18.4%) and a contralateral tumor in one patient (2.6%), neither of which was identified with mammography and ultrasonography. MRI overestimated the tumor's size in 11 tumors and underestimated the tumor's size in three tumors. Ultrasonography overestimated the tumor size in three tumors and underestimated the tumor size in 18 tumors. Mammography overestimated the tumor's size in two tumors and underestimated the tumor's size in 17 tumors. The correlation of the tumor's size on imaging with final pathology was better for MRI than for mammography and ultrasonography ($p = 0.026$).

Conclusions: MRI has better sensitivity of detection and correlation with ILC tumor size at pathology than mammography and ultrasonography. MRI is shown to be superior to mammography and ultrasonography in detecting multifocal and contralateral tumors.

Key words: carcinoma, lobular, cancer, mammography, ultrasonography, magnetic resonance imaging

Introduction

Invasive lobular cancer (ILC) is a neoplasm originating in the lobular epithelium of the breast. It is the second most common breast cancer and accounts for 5–15% of all breast cancers (1-5). ILC was first described by Foote and Stewart in 1941. They noted its unique growth patterns, which include a linear file arrangement of cells (so-called Indian file pattern) and scattered growth pattern (6,7). ILC has a tendency to spread diffusely or between the collagen fibers of the breast and produces little desmoplastic response (8). ILC is associated with a higher frequency of multifocal, multicentric, or bilateral breast cancer compared with other types of cancer (1,9).

Therefore, ILC often presents a diagnostic and a therapeutic challenge (1,10). Despite these diagnostic difficulties, imaging modalities are important in the preoperative evaluation of ILC.

At mammography (MG), ILC tends to manifest as lesions with opacity equal to or less than that of normal fibroglandular tissue (11). Therefore, false-negative rates for ILC (up to 19%) are higher than for other invasive cancers detected via MG (2,12). Ultrasonography (US) is a valuable adjunct to MG for the detection of ILC. The appearance of ILC on US is frequently subtle and tends to manifest as focal shadowing without a discrete mass (11). In particular, the detection of ILC on US may be difficult for lesions smaller than 1 cm (12,13). As the mammographic and the sonographic appearance of ILC are frequently subtle, these modalities will not always detect the full extent of the tumor. MG and US are associated with lower sensitivities for detecting ILC (1-3,14).

Magnetic resonance imaging (MRI) is increasingly used for the detection of invasive breast cancers. In recent years, MRI has proved to be a useful adjunct to MG and US in the detection and management of ILC. MRI is a promising method for preoperative staging of breast cancer to exclude multifocality or multicentricity. Moreover, the additional screening by MRI of the contralateral breast may be useful, with some investigators reporting that MRI, together with MG and US, resulted in sensitivities reaching 100% in the detection of invasive breast cancer (9,10,15).

Due to the lower incidence of ILC, few studies have looked at the efficacy of MRI for the detection of ILC, preoperative estimation of size, and concordance with final pathology. The purpose of this study was to determine the adjunct value to mammography and ultrasonography of magnetic resonance imaging (MRI) in determining the presence, extent and multifocality of invasive lobular cancer (ILC).

Materials and methods

We retrospectively reviewed images from 38 patients with a mean age of 63 years (45–85) who had been diagnosed with ILC histopathologically between May 2009 and February 2011. Patients with associated ductal carcinoma were excluded from this study. In line with our unit policy, MRI was performed after ILC had been diagnosed histopathologically. The imaging and reporting data were collected from PACS. All of the patients underwent surgery. The size

of the tumor and the presence of multifocality or a bilateral tumor at imaging and reporting were recorded. In cases of widespread multifocal disease, the largest lesion was measured. The pathological size was considered the gold standard for comparison. Concordance occurred when the size of the measured lesion on imaging was within 0.5 cm of the size on the final pathology. In line with our Trust's policy no ethics committee approval was obtained as this was a retrospective survey and no patients were individually identified.

MRI

MRI of the breast was performed with a 3-T system, with a dedicated dual breast coil. The patients were imaged while in the prone position and with the breast slightly compressed. First, an axial T2-weighted turbo-spino-echo sequence (TR/TE, 5200/90 msec, slice thickness, 4 mm) was acquired. Then, an axial and sagittal T1-weighted flash three-dimensional sequence (TR/TE, 19/7 msec; matrix, 256x256; field of view, 30 cm; slice thickness, 4 mm) was used for dynamic contrast enhancement in all of the examinations. In the initial phases of the dynamic exam, axial and sagittal images were obtained without contrast. Intravenous (IV) contrast material (gadopentetate dimeglumine) (0.2 mmol/kg IV bolus) was then injected. Each field of view was scanned seven times. The sagittal images were obtained before and after the administration of the contrast material. To detect any contrast enhancement, subtraction images were obtained by subtracting the no-contrast images from the dynamic early- and late-phase contrast images. The images were reviewed by two specialist breast radiologists.

Mammography

All cases were examined with a technique using full-field digital mammography. Craniocaudal and mediolateral oblique rojections of bilateral breasts were obtained. Additional spot compression and magnification views were obtained some cases. The mammographic images were reviewed by two specialist breast radiologists.

Ultrasonography

All the sonographic examinations were performed by two specialist breast radiologists using high resolution sonography with the patient placed in the supine or oblique supine position. Scans were performed using a high frequency probe operating at 8–10 MHz.

Statistical analysis

The correlation between the pathological size and the size on imaging was measured by Pearson's correlation coefficients for each diagnostic modality. All of the data were analyzed by SPSS analytical software.

Results

Sensitivity

All of the tumors were visualized by MRI. US failed to detect two tumors (5.3%), and MG did not detect six tumors (15.8%). The sensitivity of detection of ILC was much better with MRI (100%) compared with US (95%) and MG (84%). Twenty-two of the patients underwent lumpectomy, and 16 of the patients underwent mastectomy.

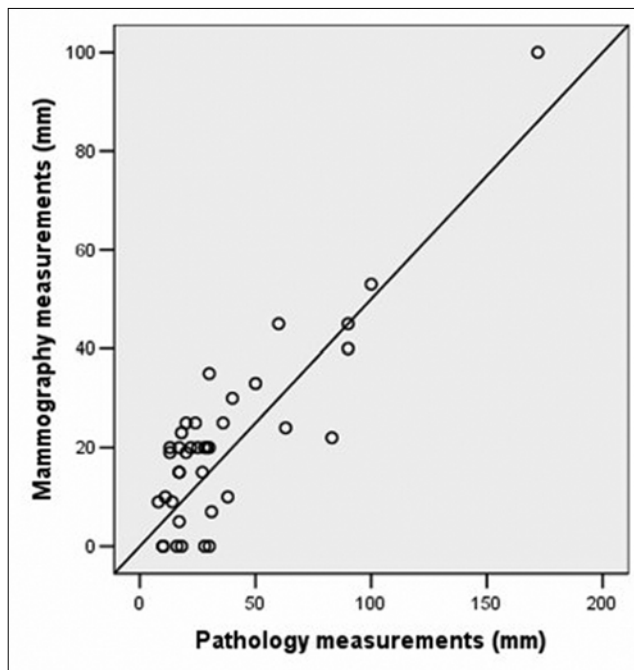


Figure 1. The correlation of the tumor's size on mammography with final pathology.

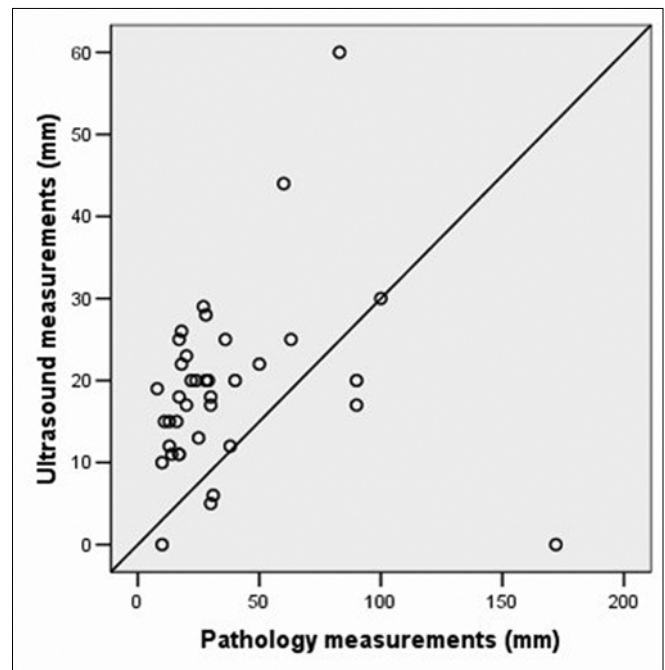


Figure 2. The correlation of the tumor's size on ultrasonography with final pathology.

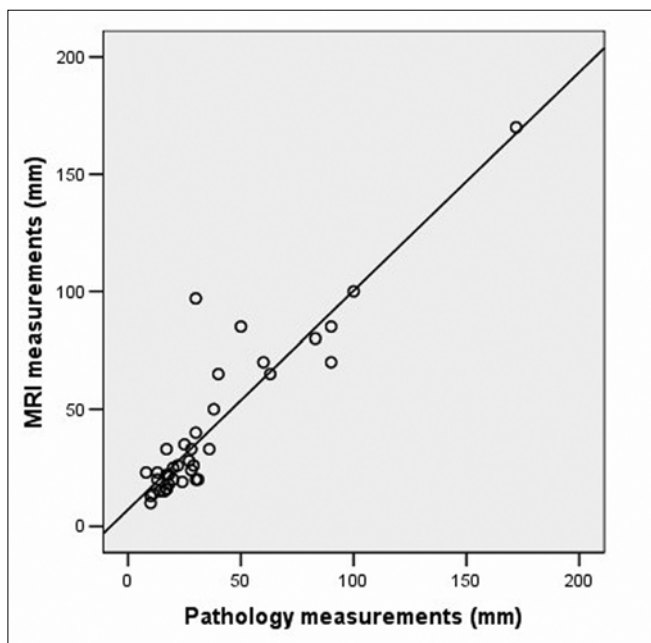


Figure 3. The correlation of the tumor's size on magnetic resonance imaging with final pathology.

Concordance, overestimation, and underestimation

The MRI tumor size was concordant (within 0.5 cm) with the pathological tumor size in 24 (63.2%) of the patients. The concordance for lesions of ≤ 2 cm at pathology was 12 of 16 (75%) patients, and the concordance for lesions of > 2 cm was 12 of 22 (54.5%) of the patients. MRI overestimated the size of the tumor by more than 0.5 cm in 11 of the patients (28.9%) and underestimated the

tumor's size by more than 0.5 cm in three (7.9%) of the patients. The mean size of the tumor was 37 mm (10–172) in the concordant group, 29.4 mm (8–60) in the overestimated group, and 50.3 mm (30–90) in the underestimated group by MRI.

The tumor's size on MG was concordant (within 0.5 cm) with the pathological tumor size in 13 (34.2%) of the patients. MG overestimated the tumor's size by more than 0.5 cm in two of the patients (5.3%) and underestimated the tumor's size by more than 0.5 cm in 17 of the patients (44.7%). The mean size of the tumor was 18.7 mm (8–30) in the concordant group, 13 mm (13–13) in the overestimated group, and 57.8 mm (17–172) in the underestimated group by MG.

The tumor's size on US was concordant (within 0.5 cm) with the pathological tumor size in 15 (39.5%) of the patients. US overestimated the size of the tumor by more than 0.5 cm in three of the patients (7.9%) and underestimated the size of the tumor by more than 0.5 cm in 18 (47.4%) of the patients. The mean size of the tumor was 36.7 mm (10–172) in the concordant group, 14.3 mm (8–18) in the overestimated group, and 48.3 mm (17–100) in the underestimated group by US.

Contralateral tumor

MRI identified a contralateral tumor in one patient (2.6%) that was not detected by MG or by US (Figure 4a,b,c,d). Subsequent US detected the tumor recognized by MRI, and US-guided core needle biopsy was performed. The results of the biopsy showed contralateral primary ILC in this patient. The patient underwent a bilateral mastectomy.

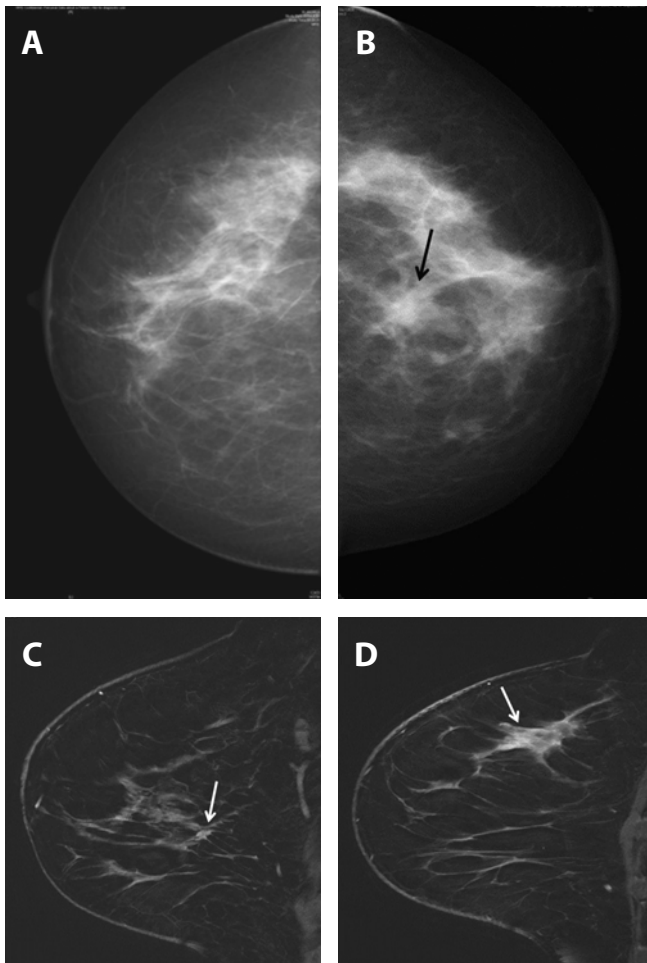


Figure 4. (A) Right mammogram (*craniocaudal view*) of a woman shows normal. (B) Left mammogram (*craniocaudal view*) of same woman shows ill-defined, speculated dens, irregular mass with biopsy-proven invasive lobular cancer. (C) Dynamic magnetic resonance image sagittal view (*right breast*) of same woman shows a tumour with biopsy-proven invasive lobular cancer. MRI identified a contralateral tumor in same woman that was not detected by mammography or by ultrasonography. (D) Dynamic magnetic resonance image sagittal view (*left breast*) of same woman shows ill-defined, speculated mass.

Multifocal tumors

MRI identified multifocal tumors in seven (18.4%) of the patients; these tumors were not detected by MG or US. Due to the increase in stage, the therapeutic procedure was changed from lumpectomy to mastectomy in six of these seven patients. The results of the final pathology showed multifocal ILC in these seven patients..

Correlation coefficients

The correlation of the measured tumor size with the size on final pathology measured by the Spearman correlation coefficient was the best with MRI ($r = 0.837$) ($p = 0.0001$) compared with MG ($r = 0.675$) ($p = 0.0001$) and US ($r = 0.361$) ($p = 0.026$) (Figure 1,2,3).

Discussion

In making a choice about surgical treatment, it is important to have an accurate definition of the extent of the cancer or bilateral cancer (16). The preoperative evaluation of the tumor's size and the detection of multifocal tumors can influence the choice of surgical treatment. In particular, an accurate estimation of the extent of invasive cancer is essential to determine eligibility for breast conservation therapy. The goal is to perform a resection with negative margins and, thus, minimize the risk of local tumor recurrence. Imaging modalities are important in the preoperative evaluation of ILC.

The sensitivity of MG and US for ILC detection was reported to be 57–90.5% (1,3,14,17-19,) and 68–98% (14, 17-20), respectively. The sensitivity of MG (84%) and US (95%) in this study are in accordance with the findings reported in the literature. The use of MRI as an adjunct to MG and US increases sensitivity in the detection of ILC and provides useful information for presurgical planning. Some investigators have reported that MRI is a useful addition to MG and US, with sensitivities reaching 100% in the detection of invasive breast cancer (9,10,15,17,18,21). In this study, the sensitivity of MRI was 100%.

In a study of ILC, McGhan et al (17) reported a concordance rate of 56% between MRI and the pathological size. We detected a rate of 63.2% in our study. Grimsby et al reported (22) that the MRI pathological concordance rate for tumors less than 2 cm for both ILC and invasive ductal carcinoma was higher in lesions >2cm (69% and 46%, respectively). McGhan et al (17) found the MRI pathological concordance rate for tumors ≤ 2 cm for ILC was higher than for those >2 cm (63% and 42%, respectively). In this study, the MRI pathological concordance was consistent with previous reports, demonstrating better concordance with ≤ 2 cm tumors (75%, 54.5%).

For ILC, the correlation between MRI and size on pathological analysis has been reported to range from 0.74 to 0.97 (17, 18, 21, 23, 24). In comparison, correlations for MG and US have been reported to be as low as 0.34–0.79 (17,25,21,24) and 0.24–0.71 (17, 21, 23-25), respectively. In our study, the correlations for MRI, MG, and US are consistent with those reported in the literature. As MRI uses both morphological and enhancement kinetics to evaluate cancer, it provides a more accurate estimation of the size of the tumor.

MG tends to underestimate the tumor size compared with US. However, overestimation of the tumor size by MG and US is rare. For example, Uchiyama et al. (26) and Veltman et al. (27) reported that 56% and 35–37%, respectively, of ILC on MG were underestimated. US tends to underestimate larger tumors more so than smaller tumors (28). Our results are in accordance with the findings reported in the literature.

In cases of multifocal breast cancer or where women have dense breast tissue, conventional imaging may miss an unsuspected breast cancer. Due to its very high sensitivity, MRI is a particularly useful imaging technique for staging women diagnosed with ILC, especially those women with very dense breast tissue and multifocal cancer. MRI has been shown to be superior to MG and to US in detecting multifocality and multicentricity, as well as in estimating the tumor's size, which tends to be underestimated with conventional imaging. The additional screening by MRI of the contralateral breast may be useful. MRI has been shown to

affect clinical management in 50% of patients with ILC, leading to changes in surgical management in 28% of cases (21,25).

In conclusion, MRI has better sensitivity in the detection of ILC and shows better correlation with the tumor's size in ILC at pathology compared with MG or US. MRI has been shown to be superior to MG and US in detecting multifocal and contralateral tumors. MG ve US tends to underestimate the tumor's size. The use of MRI as an adjunct to MG and US is important in the preoperative evaluation of ILC.

References

1. Hilleren DJ, Andersson IT, Lindholm K, Linnell FS. Invasive lobular carcinoma: mammographic findings in a 10-year experience. *Radiology* 1991; 178:149-154. (PMID: 1984294)
2. Krecke KN, Gisvold JJ. Invasive lobular carcinoma of the breast: mammographic findings and extent of disease at diagnosis in 184 patients. *AJR Am J Roentgenol* 1993; 161:957-960. (PMID: 8273634)
3. Le Gal M, Ollivier L, Asselain B, Meunier M, Laurent M, Vielh P, Neuenschwander S. Mammographic features of 455 invasive lobular carcinomas. *Radiology* 1992; 185:705-708. (PMID: 1438749)
4. Li CI, Daling JR. Changes in breast cancer incidence rates in the United States by histologic subtype and race/ethnicity, 1995 to 2004. *Cancer Epidemiol Biomarkers Prev* 2007; 16:2773-2780. (PMID: 18086787)
5. Arpino G, Bardou VJ, Clark GM, Elledge RM. Infiltrating lobular carcinoma of the breast: tumor characteristics and clinical outcome. *Breast Cancer Res* 2004; 6:149-156. (PMID: 15084238)
6. Weinstein SP, Orel SG, Heller R, Reynolds C, Czerniecki B, Solin LJ, Schnall M. MR Imaging of the breast in patients with invasive lobular carcinoma. *Am J Roentgenol* 2001; 176:399-406. (PMID: 11159081)
7. Foote FW Jr, Stewart FW. Lobular carcinoma in situ: a rare form of mammary cancer. *Am J Pathol* 1941; 17:491-496. (PMID: 19970575)
8. Fu KL, Fu YS, Lopez JK, Cardall SY, Bassett LW. The normal breast. In: Bassett LW, Jackson VP, Fu SK, Fu YS, eds. *Diagnosis of diseases of the breast*. 2nd ed. Philadelphia: Saunders, 2005;396.
9. Rodenko GN, Harms SE, Pruneda JM, Farell RS, Evans WP, Copit DS, Krakos PA, Flamig DP. MR Imaging in the management before surgery of lobular carcinoma of the breast: correlation with pathology. *Am J Roentgenol* 1996; 167:1415-1419. (PMID: 8956569)
10. Quayyum A, Birdwell RL, Daniel BL, Nowels KW, Jeffrey SS, Agoston TA, Herfkens RJ. MR Imaging features of infiltrating lobular carcinoma of the breast: histopathologic correlation. *Am J Roentgenol* 2002; 178:1227-1232. (PMID: 11959737)
11. Lopez JK, Bassett LW. Invasive lobular carcinoma of the breast: spectrum of mammographic, US, and MR imaging findings. *Radiographics* 2009; 29:165-176. (PMID: 19168843)
12. Sickles EA. The subtle and atypical mammographic features of invasive lobular carcinoma. *Radiology* 1991; 178:25-26. (PMID: 1984313)
13. Butler RS, Venta LA, Wiley EL, Ellis RL, Dempsey PJ, Rubin E. Sonographic evaluation of infiltrating lobular carcinoma. *AJR Am J Roentgenol* 1999; 172:325-330. (PMID: 9930776)
14. Albayrak ZK, Onay HK, Karatađ GY, Karatađ O. Invasive lobular carcinoma of the breast: mammographic and sonographic evaluation. *Diagn Interv Radiol* 2011; 17:232-338. (PMID: 20706979)
15. Orel SG, Schnall MD. MR imaging of the breast for the detection, diagnosis, and staging of breast cancer. *Radiology* 2001; 220:13-30. (PMID: 11425968)
16. Boetes C, Mus RDM, Holland R, Barentsz JO, Strijk SP, Wobbes T, Hendriks JHCL, Ruys SHJ. Breast tumors: comparative accuracy of MR imaging relative to mammography and US for demonstrating extent. *Radiology* 1995; 197:743-747. (PMID: 7480749)
17. McGhan LJ, Wasif N, Gray RJ, Giurescu ME, Pizzitola VJ, Lorans R, Ocal IT, Stucky CC, Pockaj BA. Use of preoperative magnetic resonance imaging for invasive lobular cancer: good, better, but maybe not the best? *Ann Surg Oncol* 2010; 17:255-262. Epub 2010 Sep 19. (PMID: 20853043)
18. Kneeshaw PJ, Turnbull LW, Smith A, Drew PJ. Dynamic contrast enhanced magnetic resonance imaging aids the surgical management of invasive lobular breast cancer. *Eur J Surg Oncol* 2003; 29:32-37. (PMID: 12559074)
19. Paramagul CP, Helvie MA, Adler DD. Invasive lobular carcinoma: sonographic appearance and role of sonography in improving diagnostic sensitivity. *Radiology* 1995; 195:231-234. (PMID: 7892476)
20. Cawson JN, Law EM, Kavanagh AM. Invasive lobular carcinoma: sonographic features of cancers detected in a BreastScreen Program. *Australas Radiol*. 2001; 45:25-30. (PMID: 11259968)
21. Francis A, England DW, Rowlands DC, Wadley M, Walker C, Bradley SA. The diagnosis of invasive lobular breast cancer. Does MRI have a role? *The Breast* 2001; 10:38-40. (PMID: 14965557)
22. Grimsby GM, Gray R, Dueck A, Carpenter S, Stucky CC, Aspey H, Giurescu ME, Pockaj B. Is there concordance of invasive breast cancer pathologic tumor size with magnetic resonance imaging? *Am J Surg* 2009; 198:500-504.
23. Kepple J, Layeeque R, Klimberg VS, Harms S, Siegel E, Korourian S, Gusmano F, Henry-Tillman RS. Correlation of magnetic resonance imaging and pathologic size of infiltrating lobular carcinoma of the breast. *Am J Surg* 2005; 190:623-627. (PMID: 16164936)
24. Munot K, Dall B, Achuthan R, Parkin G, Lane S, Horgan K. Role of magnetic resonance imaging in the diagnosis and single-stage surgical resection of invasive lobular carcinoma of the breast. *Br J Surg* 2002; 89:1296-1301. (PMID: 12296901)
25. Boetes C, Veltman J, Van DL, Bult P, Wobbes T, Barentsz JO. The role of MRI in invasive lobular carcinoma. *Breast Cancer Res Treat* 2004; 86:31-37. (PMID: 15218359)
26. Uchiyama N, Miyakawa K, Moriyama N, Kumazaki T. Radiographic features of invasive lobular carcinoma of the breast. *Radiat Med* 2001; 19:19-25. (PMID: 11305614)
27. Veltman J, Boetes C, van Die L, Bult P, Blickman JG, Barentsz JO. Mammographic detection and staging of invasive lobular carcinoma. *Clin Imaging* 2006; 30:94-98. (PMID: 16500539)
28. Tresserra F, Feu J, Grases PJ, Navarro B, Alegret X, Fernandez-Cid A. Assessment of breast cancer size: sonographic and pathologic correlation. *J Clin Ultrasound* 1999; 27:485-491. (PMID: 10525209)

Correspondence

Hatice Gümüş
E-Posta : drhaticegumus@hotmail.com