



Massive Megacolon Due to Giant Faecaloma of the Sigmoid Colon in an Elderly Patient

Yaşlı Bir Hastada Sigmoid Kolondaki Dev Fekaloma Bağlı Gelişen Masif Megakolon

© Zafer Teke, © Orçun Yalav, © Osman Erdoğan, © İshak Aydın

Çukurova University Faculty of Medicine, Department of Surgical Oncology, Adana, Turkey

ABSTRACT

Faecaloma is a mass of inspissated faeces, typically found in the rectosigmoid colon. Furthermore, faecalomas may cause intestinal obstruction, stercoral ulcer development and colon perforation, which may be due to the pressure effect of large faecal mass. We herein present a case of massive megacolon due to giant faecaloma in a 72-year-old man with symptoms of mechanical ileus. During surgery, there was a giant faecaloma, 10 cm in diameter, within the sigmoid colon, and a Hartmann left colon resection was performed. The purpose of this article is to provide a brief overview of this condition and discuss treatment options.

Keywords: Faecaloma, ileus, intestinal obstruction, mechanical bowel obstruction, megacolon

ÖZ

Fekalom, genellikle rektosigmoid kolonda yerleşen sertleşmiş bir gaita kütesidir. Fekalomlar, bağırsak tıkanmasına, fekal muhteviyatın bası etkisiyle stercoral ülser gelişimi ve kalın bağırsak perforasyonuna yol açabilir. Biz burada mekanik ileus semptomları ile başvuran 72 yaşındaki erkek bir hastada dev fekaloma bağlı gelişen masif megakolon olgusunu sunuyoruz. Operasyonda sigmoid kolonda 10 cm çaplı dev bir fekalom kütesi olduğu görüldü ve hastaya Hartmann tipi sol kolon rezeksiyonu uygulandı. Bu çalışmanın amacı, bu klinik durumu kısaca gözden geçirmek ve tedavi seçeneklerini tartışmaktır.

Anahtar Kelimeler: Fekalom, ileus, bağırsak tıkanması, mekanik bağırsak tıkanması, megakolon

Introduction

Faecaloma is characterised as a mass of inspissated faeces accumulated in the colon and/or rectum that is much harder than impacted faeces. The faeces initially accumulate, then stagnate and get impacted by faecal stasis, expand and deform the intestine and develop into large tumour-like masses. Moreover, faecalomas are frequently seen in neglected elderly people, bed-dependent patients, nursing home residents, chronic psychiatric patients, Hirschsprung's disease, Chagas disease, colonic stenosis caused by chronic inflammation or tumours and patients with chronic constipation.¹

We herein describe a case of massive megacolon due to

giant faecaloma in a 72-year-old man with symptoms of mechanical colonic obstruction. During surgery, there was a giant faecaloma in the sigmoid colon, and a Hartmann left colon resection was performed. The purpose of this article is to provide a brief overview of this condition and discuss treatment alternatives for such cases.

Case Report

A 72-year-old male was admitted to our emergency department with complaints of abdominal pain, abdominal distension, nausea and vomiting and an absence of gas-faeces discharge for approximately 1 week. The patient was first admitted to



Address for Correspondence/Yazışma Adresi: Zafer Teke, MD,
Çukurova University Faculty of Medicine, Department of Surgical Oncology, Adana, Turkey
E-mail: zteke_md@hotmail.com ORCID ID: orcid.org/0000-0001-8869-6476
Received/Geliş Tarihi: 29.02.2020 Accepted/Kabul Tarihi: 27.03.2020

another general hospital and was then hospitalised in the hospital's inpatient general surgery unit. Initially, the patient was diagnosed with ileus and managed conservatively with laxatives and enemas for about 5-6 days. Unfortunately, he did not benefit from the medical treatment used, and the patient's abdominal distension increased day by day. Since the patient was considered a poor surgical candidate due to his older age and underlying pulmonary disease, he was referred to our hospital for further examination and treatment.

The patient's previous medical history included colonic surgery of uncertain aetiology 9 years earlier. During the physical examination, the abdomen was markedly distended. A digital rectal examination revealed empty ampulla recti. Plain abdominal X-rays showed marked distension of the entire colon, which was full of faecal waste. In addition, computed tomography (CT) of the abdomen revealed markedly distended colonic segments filled with intraluminal faecal matter (Figure 1). The patient was admitted in the surgical intensive care unit of our hospital, and surgical intensive care team began rapid intravenous fluids and electrolyte replacement. A nasogastric tube was inserted and a large volume of liquid faecaloid content was emptied. Initially, we tried medical strategy, including enemas, but it was not effective in resolving mechanical ileus. Since our patient was unresponsive to conventional medical treatment for about 1 week and his abdomen was severely distended, leading to abdominal compartment syndrome, we agreed to perform a surgical intervention with a preliminary diagnosis of obstructive left colonic malignancy.

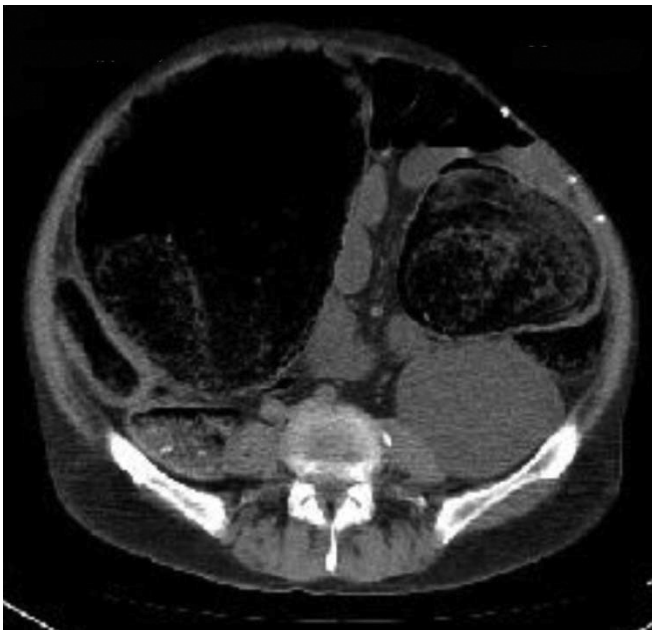

Figure 1. An axial CT section showing well-formed, large faecal ball in dilated sigmoid colon

CT: Computed tomography

An emergency laparotomy was conducted following haemodynamic stabilisation with adequate fluid and electrolyte resuscitation in the surgical intensive care unit. Furthermore, proximal colonic segments were extremely distended during exploration due to faecaloma obstruction. The maximum diameter of the transverse colon was 24 cm. At the previous anastomotic level, there was a giant faecaloma in the sigmoid colon (Figure 2). Surgical intervention was carried out with the Hartmann left hemicolectomy. On the section of the sigmoid colon, a large faecal mass, approximately 10 cm in diameter, was present within the lumen (Figure 3). The patient had a regular postoperative course. Additionally, histopathologic examination revealed oedematous and congested colonic mucosa. No stercoral ulcers were also detected. However, there were ganglion cells in the submucosa of the colon.

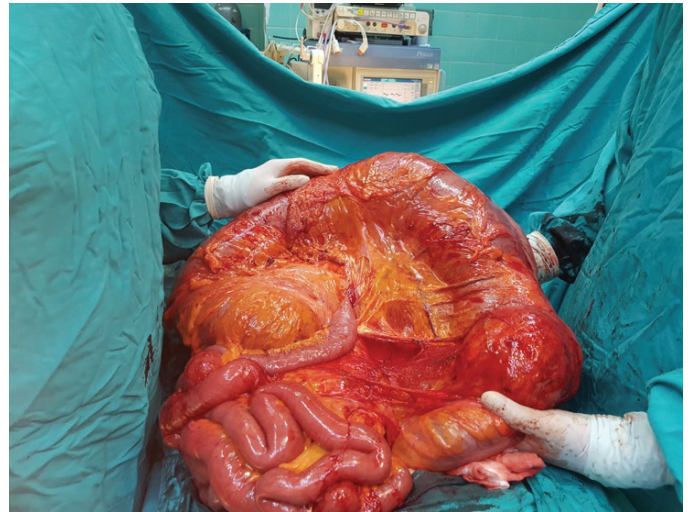


Figure 2. Giant faecaloma resided in the sigmoid colon and dilated proximal colonic segments

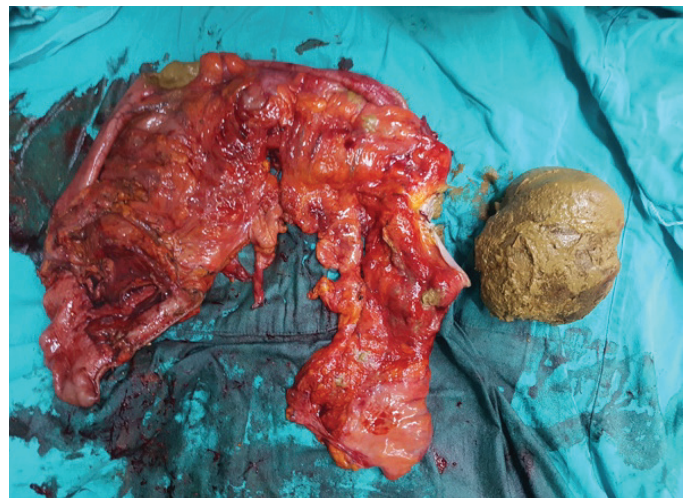


Figure 3. Resected colon specimen with giant faecaloma

Discussion

Faecal impaction is a common condition, and faecaloma is an extreme variety of impaction, which refers to an accumulation of faeces that forms a mass distinguishable from the rest of the bowel contents.² Faecalomas are hard, laminated and calcified faecal masses. This clinical condition is generally seen in elderly and chronically constipated patients and is usually caused by a dolichomegacolon. Moreover, the sigmoid colon and rectum are the most common localisations of this condition.³ Chronic constipation is one of the most commonly recorded symptoms in these cases and is the primary cause of patient medical examinations.⁴ Patients with faecaloma typically have non-specific symptoms such as diarrhoea overflow, chronic anaemia, weight loss or ambiguous postprandial abdominal discomfort.⁵ Plain abdominal X-rays, barium enema studies and a colonoscopy can be diagnostic. Specific ultrasound and CT scan appearance have also been reported.^{6,7} Despite all these investigations, faecalomas have been confused with colonic malignancy. Our patient was in his seventh decade and had chronic constipation, and we were only able to establish the diagnosis during surgery that revealed a giant faecaloma in the sigmoid colon.

Faecaloma can resemble a colorectal carcinoma due to its manifestation as an abdominal mass. The most frequently seen complications of a faecaloma result from direct obstruction of either small bowel or colon, which may lead to perforation, peritonitis and abscess formation. Other rare complications of faecaloma stem from the direct compression of adjacent anatomical structures, which may cause urinary retention, bladder compression, urinary bladder rupture, ureteral obstruction, hydronephrosis, nerve compression, sciatica or deep venous thrombosis.^{5,8,9} On the other hand, faecaloma, which is complicated by stercoral ulceration may lead to rectal bleeding, chronic anaemia and perforation of the colon or rectum.¹⁰ Although constipation with faecaloma is common, stercoral perforation is rare. A study of 175 consecutive autopsies reported a 4.6% incidence of stercoral ulcer.¹¹ In our patient, considering the enormous size of the faecaloma, there were no stercoral ulcers, presumably due to the associated megacolon. Most faecalomas are usually evacuated by conventional modalities, including bowel rest, laxatives, polyethylene glycol, suppositories and transrectal enemas. Manual disimpaction, finger fracture method and digital rectal evacuation are also necessary to dislodge hard stools. Rectosigmoidoscopic approach to the elimination of rectal faecaloma has also been reported.¹² In addition, water jets from dental clinics have been used in chronic faecalomas using a sigmoidoscope.¹³ When conservative treatments are ineffective or when potentially serious complications appear,

surgical removal is appropriate to avoid morbidity and mortality. Surgical intervention requires either explorative laparotomy or laparoscopic colectomy with faecaloma extraction or excision of the colonic segment involved where there is an underlying pathology.¹⁴ Thus, partial resection has promising outcomes in patients with minimal disease, such as sigmoid megacolon.¹⁵ More radical surgery, such as total abdominal colectomy with ileorectal anastomosis, may be necessary in patients with constipation due to total colonic inertia. Preferably, if the proximal colon is full of faecal matter, it should be washed by polyethylene glycol or by rapid on-table colonic lavage before resection. This patient was first treated conservatively with laxatives and enemas for around 5-6 days in another hospital. We also initially attempted a medical approach, including enemas, but it was unsuccessful in resolving mechanical ileus. Since our patient was unresponsive to conventional medical treatment and had abdominal compartment syndrome due to severely distended abdomen, we agreed to perform a surgical intervention with a preliminary diagnosis of obstructive left colonic malignancy. We performed a left-sided hemicolectomy with a temporary colostomy (Hartmann's procedure) to relieve mechanical intestinal obstruction in the emergency setting, and then the closure of colostomy was done in the second session.

Faecaloma should be taken into consideration in the differential diagnosis of any patient with a history of chronic constipation, particularly in elderly people, bed-dependent patients, nursing home residents and chronically ill psychiatric patients or even in patients with prior colorectal surgery. Chronically constipated patients should be extensively investigated and should be medically, endoscopically or surgically approached to prevent possible complications. However, management is tiresome in high-risk individuals and may require surgery.

Ethics

Informed Consent: Patient was informed about the study and written informed consent form was obtained.

Peer-review: Externally peer reviewed.

Authorship Contributions

Concept: Z.T., O.Y., O.E., İ.A., Design: Z.T., O.Y., O.E., İ.A., Data Collection or Processing: Z.T., O.Y., O.E., İ.A., Analysis or Interpretation: Z.T., O.Y., O.E., İ.A., Literature Search: Z.T., O.Y., O.E., İ.A., Writing: Z.T., O.Y., O.E., İ.A.

Conflict of Interest: No conflict of interest was declared by the authors.

Financial Disclosure: The authors declared that this study received no financial support.

References

1. Altomare DF, Rinaldi M, Sallustio PL, Armenise N. Giant fecaloma in an adult with severe anal stricture caused by anal imperforation treated by proctocolectomy and ileostomy: report of a case. *Dis Colon Rectum* 2009;52:534-537.
2. Cid AA, Pietruk T, Bidari CZ, Ehrinpreis MN. Cecal fecaloma mimicking colonic neoplasm. *Dig Dis Sci* 1981;26:1134-1137.
3. Rajagopal A, Martin J. Giant Fecaloma with idiopathic sigmoid megacolon: report of a case and review of the literature. *Dis Colon Rectum* 2002;45:833-835.
4. Sonnenberg A, Koch TR. Physicians visits in the United States for constipation: 1958 to 1986. *Dig Dis Sci* 1989;34:606-611.
5. Gupta M, Aggarwal P, Singh R, Lehl SS. A case of giant fecaloma in a 32-year-old woman. *Austin J Clin Case Rep* 2014;1:2.
6. Derchi LE, Musante F, Biggi E, Cicio GR, Oliva L. Sonographic appearance of a fecal mass. *J Ultrasound Med* 1985;4:573-575.
7. Fagelman D, Warhit JM, Reiter JD, Geiss AC. CT diagnosis of fecaloma. *J Comput Assist Tomogr* 1984;8:559-561.
8. Chute DJ, Cox J, Archer ME, Bready RJ, Reiber K. Spontaneous rupture of urinary bladder associated with massive fecal impaction (fecaloma). *Am J Forensic Med Pathol* 2009;30:280-283.
9. Narang A, Mittal S, Garg P, Aggarwal S, Singh J, Kaushik K, Verma S. Rectal perforation by impacted fecaloma -- a new mechanism proposed. *Indian J Gastroenterol* 2013;32:417-418.
10. Serpell JW, Nicholls RJ. Stercoral perforation of the colon. *Br J Surg* 1990;77:1325-1329.
11. Grinvalsky HT, Bowerman CI. Stercoraceous ulcers of the colon: relatively neglected medical and surgical problem. *J Am Med Assoc* 1959;171:1941-1946.
12. Sakai E, Inokuchi Y, Inamori M, Uchiyama T, Iida H, Takahashi H, Akiyama T, Akimoto K, Sakamoto Y, Fujita K, Yoneda M, Abe Y, Kobayashi N, Kubota K, Saito S, Nakajima A. Rectal fecaloma: successful treatment using endoscopic removal. *Digestion* 2007;75:198.
13. Korn ER. Use of a dental irrigating unit in the treatment of fecal impactions. *Gastrointest Endosc* 1972;19:88.
14. Engelberg M, Nudelman I, Korzets Z. Giant fecaloma with dolichomegacolon. *Am J Proctol Gastroenterol Colon Rectal Surg* 1982;33:9-12.
15. Pfeifer J, Agachan F, Wexner SD. Surgery for constipation: a review. *Dis Colon Rectum* 1996;39:444-460.