

Giant Juvenile Fibroadenoma of the Breast: Clinical Manifestation in Two Cases

Memenin Dev Juvenil Fibroadenomu: İki Olguda Klinik Manifestasyon

✉ Mehmet Tolga Kafadar¹, ✉ Mehmet Ali Kırşan¹, ✉ Suat Çal², ✉ Mehmet Hanifi Okur², ✉ Sadullah Girgin¹

¹Dicle University Faculty of Medicine, Department of General Surgery, Diyarbakır, Turkey

²Dicle University Faculty of Medicine, Department of Pediatric Surgery, Diyarbakır, Turkey

Cite this article as : Kafadar MT, Kırşan MA, Çal S, Okur MH, Girgin S. Giant Juvenile Fibroadenoma of the Breast: Clinical Manifestation in Two Cases. J Acad Res Med 2020;10(3):303-5

ABSTRACT

Giant fibroadenomas are benign masses that usually present as unilateral rapid growths in the breast during puberty. They can spread over a wide area and cause congestion and ulcerations in the breast skin. Definitive diagnosis is made by breast biopsy. Treatment options may vary from simple excision to subcutaneous mastectomy, depending on the size of the mass. Herein, we present two cases of 13- and 14-year-old female patients who were treated for giant breast fibroadenoma. In these extremely rare cases, total mass excision was performed, which preserved the breast skin.

Keywords: Breast, juvenile giant fibroadenoma, surgery

ÖZ

Dev fibroadenomlar puberte döneminde, memede genellikle tek taraflı hızlı büyüme ile karşımıza çıkan iyi huylu kitlelerdir. Geniş alana yayılıp konjesyona ve meme derisinde ülserasyonlara sebep olabilirler. Kesin tanıları meme biyopsisi ile konur. Tedavi seçenekleri, kitlenin büyüklüğüne göre, basit eksizyondan subkütan mastektomiye kadar değişkenlik gösterebilmektedir. Bu yazıda, memede dev fibroadenom nedeni ile tedavi edilen 13 ve 14 yaşında bayan iki olgu sunuldu. Oldukça nadir görülen olgulara, meme derisi korunarak total kitle eksizyonu uygulandı.

Anahtar kelimeler: Meme, juvenil dev fibroadenom, cerrahi

INTRODUCTION

Fibroadenomas are the most common causes of breast lumps in young women. They have a benign character and contain mixed glandular and mesenchymal structures. They are caused by increased estrogen stimulation and receptor sensitivity during puberty (1). They usually stop growing if they reach a size of 2 cm. Those over 5 cm in size are defined as giant fibroadenoma. Indeed, providing the best treatment for these patients in terms of clinical and psychological care is challenging. Attentive surgical

planning is required to ensure a fine balance between adequate resection and the best cosmetic outcome for a developing breast (2). Herein, two different cases of a giant juvenile fibroadenoma of the left breast were presented.

CASE PRESENTATIONS

Case 1

A 13-year-old female patient was admitted to a general surgery outpatient clinic with a rapidly growing, painless mass in her left

ORCID IDs of the authors: M.T.K. 0000-0002-9178-7873; M.A.K. 0000-0003-0015-4870; S.Ç. 0000-0003-1964-0895; M.H.O. 0000-0002-6720-1515; S.G. 0000-0002-4889-7473

Corresponding Author/Sorumlu Yazar: Mehmet Tolga Kafadar,

E-mail: drtolgakafadar@hotmail.com

Received Date/Geliş Tarihi: 03.09.2020 **Accepted Date/Kabul Tarihi:** 19.11.2020

©Copyright 2020 by University of Health Sciences Turkey, Gaziosmanpaşa Training and Research Hospital. Available on-line at www.jarem.org

©Telif Hakkı 2020 Sağlık Bilimleri Üniversitesi, Gaziosmanpaşa Eğitim ve Araştırma Hastanesi. Makale metnine www.jarem.org web sayfasından ulaşılabilir.



breast that she have noticed approximately 3 months ago. Physical examination revealed a firm, well-circumscribed, approximately 11 cm mass that filled the left breast (Figure 1a). No pathology was found in the right breast and in both axillae. Patient's family history and laboratory tests were unremarkable. Breast ultrasonography (USG) showed a 105x80 mm², well-circumscribed hypoechoic solid lesion that nearly filled the left breast (Breast Imaging-Reporting and Data System 4A).

Case 2

A 14-year-old female patient was admitted to the general surgery outpatient clinic with a rapidly growing, painless mass in her left breast that she have noticed approximately 3 months ago. During physical examination, a firm, well-circumscribed mass of approximately 9 cm, which nearly filled the left breast, was palpated. The patient's medical and family histories were unremarkable. Breast magnetic resonance imaging (MRI) showed a lesion that nearly filled the left breast, with heterogeneous hypointense appearance on T2A images with a size of 82x78 mm, heterogeneous hyperintense characteristic in T1A images, marked heterogeneous enhancement after intravenous administration of contrast material in the upper inner quadrant, and slight diffusion restriction in the diffusion-weighted images (Figure 1b).

Tru-cut biopsy was performed on the left breast in both cases. The results revealed fibroadenoma, and the patients underwent surgery. The masses were totally excised under general anesthesia, preserving the breast skin (Figure 1c). The resulting deformity was filled with the patients' own breast tissue (Figure 1d). Postoperative histopathological examination of the masses were interpreted as giant juvenile fibroadenoma (Figure 2). No recurrence was noted during the 3-month follow-up period.

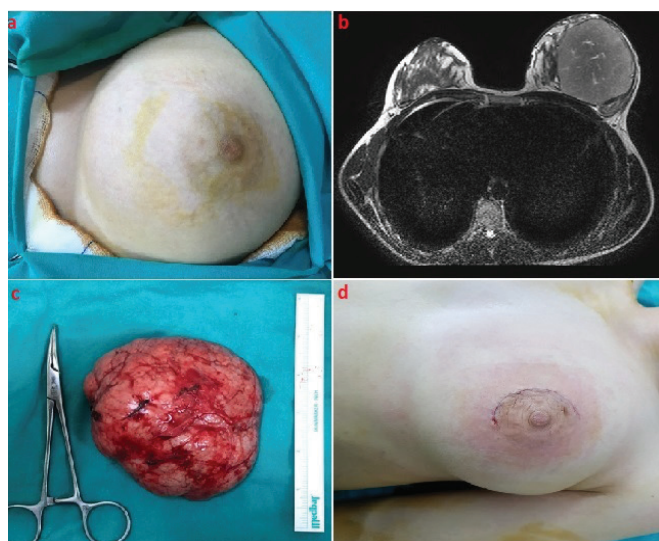


Figure 1. Preoperative view of the patient (a), preoperative MRI of the patient (b), macroscopic view of the excised specimen (c), and postoperative incision view of the patient (d)
MRI: magnetic resonance imaging

DISCUSSION

Fibroadenomas are one of the most common causes of breast masses in adolescents and young women. Juvenile giant fibroadenomas account for 0.5% of all fibroadenomas. They are mostly solitary in nature, but multiple masses can be found in 10%-20% of the patients. They are usually unilateral and rarely seen bilaterally (3). The incidence increases in the second and third decades of life, and masses typically stop growing when they reach a size of 2-3 cm. They are generally benign, well-circumscribed, and encapsulated. Typically, large lesions grow rapidly. In rare cases, they can grow up to 15 cm in size. Very few fibroadenomas have irregular edges and may contain calcifications. The lesion may cause breast deformity, compression of surrounding tissues, nipple collapse, congestion, and skin ulcerations (4). Islam et al. (5) reported the world's largest juvenile fibroadenoma of the breast in a 16-year-old girl who presented with a 28x25 cm² mass on her left breast, which was treated conservatively. In the presented cases, the masses were unilateral, rapidly growing, well-circumscribed, and solitary, consistent with the literature.

Giant fibroadenoma, phyllodes tumor, juvenile macromastia, breast abscess, lipoma, hamartoma, and malignancies can be included in the differential diagnosis of large breast masses (6). Phyllodes tumors of the breast should be ruled out in the differential diagnosis. These tumors rarely occur during puberty, and they are often seen in the third to fourth decades of life. They do not have true capsules but have high cellularity and a tendency to metastasize (7).

Preoperative histopathological diagnosis is important for differentiating breast mass from phyllodes and malignant tumors. USG is usually sufficient for the diagnosis of giant fibroadenomas, but in some cases, MRI can be performed. MRI is generally indicated for atypical lesions. Mammography is not recommended in young patients (8).

Surgical planning should be made according to the localization and size of the mass. Small tumors can be easily removed through an areolar incision. Breast-conserving surgery and reconstruction with prosthesis can be performed in patients with small tumors. The excision of fibroadenomas can be performed under local or general anesthesia. Circumareolar or inframammary incision is a good choice to minimize scar, but the location and size of

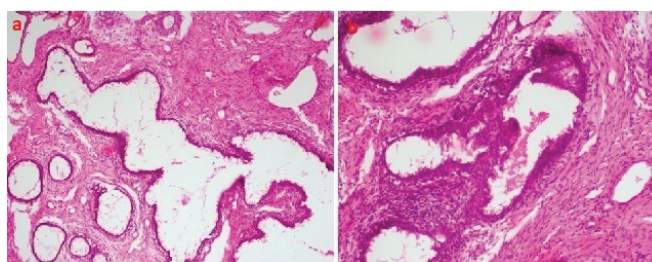


Figure 2. Microscopic view of the specimen; the tumor shows pericanalicular pattern growth, uniformly increased stromal cellularity, and epithelial proliferation without atypia (a,b) (hematoxylin and eosin staining, x100)

the mass influence the selection of appropriate incision. For masses located far from the areola border, a half-moon incision can be made directly over the mass. The mass should be totally excised (9). Skin excision and reduction may be required due to structural deformities after giant tumor excisions. Reductions made to ensure symmetry should be done after puberty, that is, after breast development (10). Skin excision was not performed in our cases. A good cosmetic result was obtained by filling the deformity following mass excision with the patient's own breast tissue.

CONCLUSION

Juvenile giant fibroadenomas are rare tumors. They can grow rapidly and form deformities in the breast. USG and, if necessary, MRI are required for diagnosis. Definitive diagnosis is made by histopathological examination. Once diagnosed, good cosmetic results can be obtained with immediate and appropriate surgical treatment.

Informed Consent: Informed consent was obtained from the father of the patients presented in this study.

Peer-review: Externally peer-reviewed.

Author Contributions: Surgical and Medical Practices - M.T.K., M.H.O.; Concept - M.T.K., M.A.K., S.Ç., S.G.; Design - M.T.K., S.Ç.; Data Collection and/or Processing - M.T.K., M.A.K., S.Ç., M.H.O.; Analysis and/or Interpretation - M.T.K., M.A.K., S.G.; Literature Search - M.T.K., M.H.O., S.G.; Writing Manuscript - M.T.K.

Conflict of Interest: The authors have no conflict of interest to declare.

Financial Disclosure: The authors declared that this study has received no financial support.

Hasta Onam: Bu çalışmada sunulan hastaların babasından bilgilendirilmiş onam alındı.

Hakem Değerlendirmesi: Editörler kurulu dışında olan kişiler tarafından değerlendirilmiştir.

Yazar Katkıları: Cerrahi ve Medikal uygulamalar - M.T.K., M.H.O.; Fikir - M.T.K., M.A.K., S.Ç., S.G.; Tasarım - M.T.K., S.Ç.; Veri toplanması ve/veya işlemesi - M.T.K., M.A.K., S.Ç., M.H.O.; Analiz ve/veya yorum - M.T.K., M.A.K., S.G.; Literatür Taraması - M.T.K., M.H.O., S.G.; Yazıyı Yazan - M.T.K.

Çıkar Çatışması: Yazarların beyan edecek çıkar çatışması yoktur.

Finansal Destek: Yazarlar bu çalışma için finansal destek almadıklarını beyan etmişlerdir.

REFERENCES

1. Celik SU, Besli Celik D, Yetiskin E, Ergun E, Percinel S, Demire S. Giant juvenile fibroadenoma of the breast: a clinical case. Arch Argent Pediatr 2017; 115: e428-31.
2. Rafeek N, Rangasami R, Dhanraj K, Joseph S. Multimodality approach in the diagnosis and management of bilateral giant juvenile breast fibroadenoma. BMJ Case Rep 2016; 2016: bcr2016217588.
3. Çelik MF, Dural AC, Ünsal MG, Akarsu C, Alim ER, Kapan S, et al. Giant juvenile fibroadenoma. Ulus Cerrahi Derg 2014; 31: 96-8.
4. Thuruthiyath N, Das PC, Avabratha KS, Mascarenhas V, Marla N. Giant fibroadenoma of breast in an adolescent girl. Oman Med J 2012; 27: 314-5.
5. Islam S, Saroop S, Bheem V, Naraynsingh V. Largest giant juvenile fibroadenoma of the breast. BMJ Case Rep 2019; 12: e227277.
6. Nikumbh DB, Desai SR, Madan PS, Patil NJ, Wader JV. Bilateral giant juvenile fibroadenomas of breasts: a case report. Patholog Res Int 2011; 2011: 482046.
7. Sadove AM, van Aalst JA. Congenital and acquired pediatric breast anomalies: a review of 20 years experience. Plast Reconstr Surg 2005; 115: 1039-50.
8. Song BS, Kim EK, Seol H, Seo JH, Lee JA, Kim DH, et al. Giant juvenile fibroadenoma of the breast: a case report and brief literature review. Ann Pediatr Endocrinol Metab 2014; 19: 45-8.
9. Kupsik M, Yep B, Sulo S, Memmel H. Giant juvenile fibroadenoma in a 9-year-old: A case presentation and review of the current literature. Breast Dis 2017; 37: 95-8.
10. Roveda Júnior D, Badan GM, Campos MSDDA, Maragno B, Pessanha LB. Juvenile fibroadenoma. Radiol Bras 2018; 51: 136-7.