

# Histopathological Effects of Fibrin Glue and Cyanoacrylate on the Maxillary Sinus

## *Fibrin Glue ve Siyanoakrilatın Maksiller Sinüs İçerisindeki Histopatolojik Etkileri*

Selda Sarıkaya<sup>1</sup>, Sultan Bişkin<sup>1</sup>, Murat Damar<sup>1</sup>, Mehmet Birol Uğur<sup>1</sup>, Erdal Sakallı<sup>2</sup>, Sibel Bektaş<sup>3</sup>

<sup>1</sup>Department of Otorhinolaryngology, Bülent Ecevit University School of Medicine, Zonguldak, Turkey

<sup>2</sup>Division of Audiology, Department of Otorhinolaryngology, Gelişim University School of Medicine, İstanbul, Turkey

<sup>3</sup>Department of Pathology, Bülent Ecevit University School of Medicine, Zonguldak, Turkey

Original Investigation

Özgün Araştırma

### Abstract

**Objective:** To compare the histopathological effects of fibrin glue (FbGl) and cyanoacrylate (CyAc) on the maxillary sinus mucosa.

**Methods:** Twenty rabbits were divided into two groups of 10, and surgical defects were created in the maxillary sinuses. The right maxillary sinus was treated with FbGl in one group and with CyAc in the other group. As a control, the left maxillary sinuses of all rabbits were treated with sterile saline solution. One rabbit treated with CyAc died during the study and was excluded. On postoperative day 21, all animals were sacrificed. Maxillary sinus mucosa samples were studied to determine the extent of inflammation and fibrosis, foreign body reaction, cilia loss, increased osteogenesis in bony structures under the mucosa, and loss of serous glands.

**Results:** The FbGl group differed significantly from the CyAc and control groups in terms of a high degree of inflammation ( $p<0.001$ ), fibrosis ( $p<0.001$ ), foreign body reaction ( $p<0.001$ ), cilia loss ( $p<0.001$ ), and serous gland loss ( $p<0.001$ ). In terms of osteogenesis, there were no significant differences between the FbGl and CyAc groups ( $p=0.650$ ), while there was a significant ( $p=0.002$ ) difference between these two groups and the control group.

**Conclusion:** Histopathologically, CyAc had fewer side effects than FbGl. Further clinical studies are needed to demonstrate the validity of these results in humans.

**Keywords:** Animal experimentation, maxillary sinus, fibrin glue, cyanoacrylate, histopathology

### Öz

**Amaç:** Fibrin glue (FbGl) ve siyanoakrilatın (CyAc) maksiller sinüs mukozası üzerine histopatolojik etkilerini karşılaştırmak.

**Yöntemler:** Çalışmaya 20 adet tavşan alındı ve her biri 10 adet olan iki gruba ayrıldı. Her iki grubun sağ maksiller sinüslerinde oluşturulan cerrahi defektleri birinci grupta (Grup 1) FbGl kullanılarak ikinci grupta (Grup 2) ise CyAc kullanılarak tedavi edildi. Her iki grubun sol maksiller sinüsleri steril salin solüsyonu ile tedavi edilerek kontrol grubu (Grup 3) olarak kullanıldı. Siyanoakrilat uygulanan ve çalışma sırasında ölen bir tavşan çalışma dışında bırakıldı. Postoperatif 21. gün bütün tavşanlar sakrifiye edildi. Her üç grubun maksiller sinüs mukozasında histopatolojik olarak inflamasyon ve fibrozis yaygınlığı, yabancı cisim reaksiyonu, silia kaybı, mukozanın altındaki kemikte osteogenezis artışı ve seröz gland kaybı oran-

ları değerlendirildi.

**Bulgular:** Her üç grup karşılaştırıldığında Grup 1(FbGl) istatistiksel olarak diğer iki gruptan daha yüksek oranda anlamlı inflamasyona ( $p<0.001$ ), fibrozise ( $p<0.001$ ), yabancı cisim reaksiyonuna ( $p<0.001$ ), silia kaybına ( $p<0.001$ ) ve seröz gland kaybına ( $p<0.001$ ) sahipti. Osteogenezis açısından ise FbGl ve CyAc grupları ile arasında anlamlı fark yok iken ( $p=0.650$ ), kontrol grubuna göre anlamlı olarak daha yüksek ( $p=0.002$ ) osteogenezise neden olmuşlardı.

**Sonuç:** Histopatolojik olarak CyAc, maksiller sinüs mukozasına FbGl'ye daha az yan etki oluşturmaktadır. İnsanlarda bu sonuçların güvenilirliğinin gösterilmesi için ileri çalışmalara ihtiyaç vardır.

**Anahtar Kelimeler:** Hayvan deneyi, maksiller sinüs, fibrin glue, siyanoakrilat, histopatoloji

### Introduction

The human body can often repair soft and hard tissue wounds, and this can be facilitated by fastening the tissues mechanically with sutures or staples (1).

In nasal and functional endoscopic sinus surgery (ESS), the limited surgical field and the need to use minimally invasive procedures make it difficult to use sutures (the gold standard), particularly



Address for Correspondence/Yazışma Adresi:

Sultan Bişkin  
E-mail: drsultanbisikin@gmail.com

Received Date/Geliş Tarihi: 22.02.2016

Accepted Date/Kabul Tarihi: 06.06.2016

© Copyright 2016 by Official Journal of the Turkish Society of Otorhinolaryngology and Head and Neck Surgery Available online at [www.turkarchotorhinolaryngol.org](http://www.turkarchotorhinolaryngol.org)

© Telif Hakkı 2016 Türk Kulak Burun Boğaz ve Baş Boyun Cerrahisi Derneği Makale metnine [www.turkarchotorhinolaryngol.org](http://www.turkarchotorhinolaryngol.org) web sayfasından ulaşılabilir.

DOI: 10.5152/tao.2016.1590

in mucosal regions (2). Wound closure, skin grafting, and the fixation of transplants and implants are vital to ensure surgical success. Tissue glues are also used to achieve closure and are currently the method of choice in dural plasty, haemostasis, and skin adhesion (1). However, wound closure systems using adhesives in otorhinolaryngology require more research.

During functional ESS, iatrogenic wounds often develop in the lamina cribrosa, particularly in the anterior ethmoid region. The lamina cribrosa is fragile, and defects and dehiscence can develop from the area of attachment of the median concha to the skull base and in the anterior and posterior ethmoidal artery channels. If an iatrogenic injury leads to cerebrospinal fluid leakage, the fistula can be closed with muscle, bone wax, fascia, a bony plate, a mucoperichondrial flap, a dural flap, tissue glue, or fat tissue (2, 3).

It is important that the material used for closure be inexpensive, readily available, easy to use, and highly compatible with the tissue. Many authors have used fibrin glue (FbGl) or a cyanoacrylate (CyAc) to adhere different tissues in both clinical and experimental studies. Sakagami et al. (4) successfully used FbGl as an underlay after myringoplasty, Grayeli et al. (5) used it after facial nerve anastomosis, and Vries et al. (6) used it after surgery on nerves. However, a risk of viral transfer has been reported (7, 8). In addition, the glue is relatively expensive and a technician may be needed to prepare autologous FbGl before the operation (9).

Pineros-Fernandez et al. (10) used CyAc to repair peripheral nerves, Bruns et al. (11) used it to repair skin lacerations, and Gulalp et al. (12) used it to repair incisions of the skin and mucosa. Several papers have reported satisfactory aesthetic and functional results using CyAc (10-12). Some studies have reported increased inflammation and fibrosis, but primarily, when first-generation short-chain materials were used. During the degradation of CyAc polymers, formaldehyde is released and the extent of CyAc histotoxicity is proportional to the amount of formaldehyde produced (13). The most commonly used CyAcs, ordered from good to bad in terms of tissue tolerance, are *n*-decyl-, *n*-octyl-, *n*-heptyl-, *n*-butyl-, isobutyl-, and methyl-cyanoacrylate (14). When applied to the skin, the strength of *n*-octyl-cyanoacrylate is thrice that of *n*-butyl-cyanoacrylate, and it is almost as strong as 5.0 monofilament nylon suture (15). Therefore, we used *n*-octyl-cyanoacrylate in this study.

No study has compared the histopathological effects of tissue adhesives on the paranasal sinus mucosa. Therefore, we compared the effects of FbGl glue and CyAc on the maxillary sinus mucosa of rabbits.

## Methods

We used 20 14- to 16-week-old New Zealand rabbits weighing 2.5–3 kg. All were fed a standard laboratory diet. The rabbits were kept in an animal room and monitored for several days before surgery to confirm that they were in good health. The animals were divided into two groups of 10 to study the histopathological effects of FbGl and CyAc on the maxillary sinus.

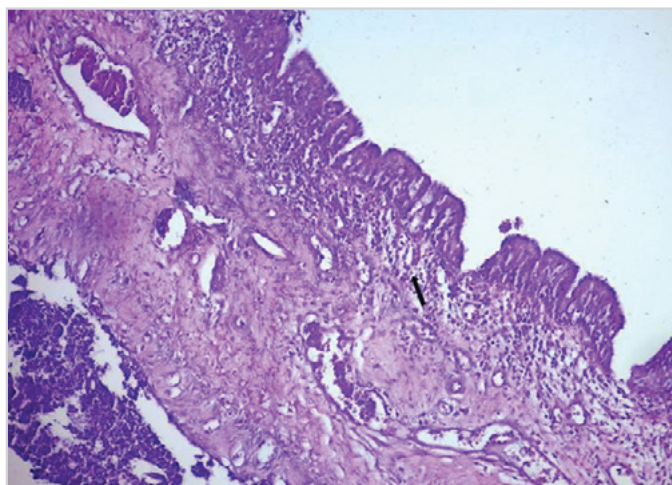


Figure 1. Medium inflammation and serous gland loss in the FbGl group (arrow, HE×100)

Table 1. Degree of inflammation in all groups

Degree of inflammation	FbGl group	CyAc group	Control group	p
Light	1 10.0%	7 77.8%	18 94.7%	p<0.001
Medium	8 80.0%	2 22.2%	1 5.3%	
Heavy	1 10.0%	0 0%	0 0%	
Total	n=10	n=9	n=19	

FbGl: fibrin glue; CyAc: cyanoacrylate

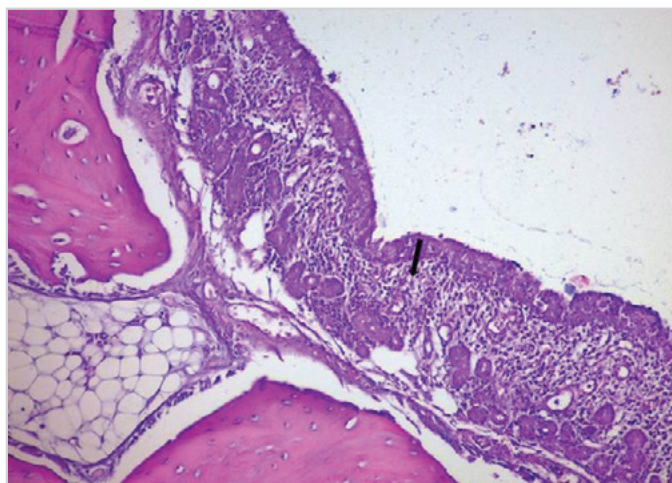


Figure 2. Light inflammation in the CyAc group (arrow, HE×100)

All rabbits were anaesthetised with intramuscular (IM) ketamine HCl (Ketalar 10 mg/mL, (Ketalar; Pfizer, İstanbul, Turkey)) and xylazine (5 mg/kg). Each surgical site was scrubbed with povidone iodine thrice. The periosteum was reached via a 2-cm vertical incision commencing at the midsection of the nasal dorsum. Then, the periosteum was elevated off the bone via a vertical incision. Using a 2-mm diameter drill, two holes (on the left and right) were drilled into the front wall of the maxillary sinus; the holes were offset by about 1 cm from the midsection of the nasal bone. In the FbGl group (n=10), the right maxillary sinus was completely filled with FbGl (Tisseel®, Baxter AG; Vienna, Austria), and in the CyAc group (n=9), it was filled

**Table 2.** Fibrosis, foreign body reactions, ciliary loss, osteogenesis, and serous gland loss in all groups

		FbG1 group n=10	CyAc group n=9	Control group n=19	P
Fibrosis	positive	10 100%	3 33.3%	0 0%	p<0.001
	none	0 0%	6 66.6%	19 100%	
Foreign body reaction	positive	7 70%	0 0%	0 0%	p<0.001
	none	3 30%	9 100%	19 100%	
Ciliary loss	positive	9 90%	3 33.3%	0 0%	p<0.001
	none	1 10%	6 66.6%	19 100%	
Osteogenesis	positive	5 50%	3 33.3%	0 0%	p<0.002
	none	5 50%	6 66.6%	19 100%	
Loss of serous glands	positive	10 100%	3 33.3%	1 5.3%	p<0.001
	none	0 0%	6 66.6%	18 94.7%	

FbG1: fibrin glue; CyAc: cyanoacrylate

**Table 3.** Statistical analysis of fibrosis, foreign body reactions, ciliary loss, osteogenesis, and serous gland loss between CyAc and control groups

		CyAc group n=9	Control group n=19	p
Degree of inflammation	7 (light) 77.8%	18 (light) 94.7%	p=0.234 Nonsignificant	
	2 (medium) 22.2%	1 (medium) 5.3%		
Fibrosis	positive	3 33.3%	0 0%	p=0.026
	none	6 66.6%	19 100%	Significant
Foreign body reaction	positive	0 0%	0 0%	Nonsignificant
	none	9 100%	19 100%	
Ciliary loss	positive	3 33.3%	0 0%	p=0.026
	none	6 66.6%	19 100%	Significant
Osteogenesis	positive	3 33.3%	0 0%	p=0.026
	none	6 66.6%	19 100%	Significant
Loss of serous glands	positive	3 33.3%	1 5.3%	p=0.084
	none	6 66.6%	18 94.7%	Nonsignificant

FbG1: fibrin glue; CyAc: cyanoacrylate

with wicking-type octyl-2-cyanoacrylate (Super Glue™; Osaka, Japan). As a control, the left maxillary sinuses of all rabbits were filled with sterile saline solution (n=19). For the FbG1 group, the thrombin and fibrinogen components of FbG1 in separate injectors were mixed in equal amounts and applied immediately. Then, the defects were covered with the periosteum and skin. After surgery, each incision was closed with atraumatic 3/0 silk suturing. During the operation, each rabbit was given 5 mg/kg ceftriaxone IM. One rabbit treated with CyAc died during the study and was excluded. Twenty-one days after the operation, all animals were euthanized, and the periosteum was opened as described above. Each maxillary sinus was extracted in the sagittal plane using an electric saw and studied.

### Histopathological Tissue Investigations

Both sides of each maxillary sinus were fixed in 10% (v/v) formaldehyde for 24 h, decalcified in an electrolytic device in 15% (v/v) formic acid for 20 days, paraffinized, cut into 5-µm-thick slices, stained with haematoxylin–eosin (H–E), and observed under a light microscope to determine the extent of inflammation, fibrosis, foreign body reaction, cilia loss, osteogenesis of bony structures under the mucosa, and loss of serous glands.

The extent of inflammation was graded on the basis of lymphocyte and macrophage infiltration, tissue damage, and repair. Fibrosis was evaluated on the basis of the migration of fibroblasts into the wound, cell proliferation, and storage of the extracellular matrix. Histopathological evaluation included analysis of foreign body reactions caused by activated macrophages, cilia loss, type 1 collagen levels, and abnormal development (osteogenesis and serous gland loss).

### Statistical Analysis

Statistical analysis were performed using SPSS 19.0 (SPSS; Chicago, IL, USA). Descriptive statistics are expressed as the frequency and percentage. The chi-square test or Fisher’s exact test was used to determine the differences among the three groups. A p-value of less than 0.05 was considered statistically significant for all tests.

### Ethics/Patient Consent

Our study was approved by the Animal Ethics Committee of Bülent Ecevit University, Zonguldak, Turkey. All animals were treated according to the Helsinki Universal Declaration of Animal Rights.

### Results

#### Inflammation

The FbG1 group had significantly more inflammation than the CyAc (p=0.009) and control (p<0.001) groups. Figure 1 shows the extent of medium inflammation in the FbG1 group. There were no significant (p=0.234) differences in inflammation between the CyAc and control groups (Table 1, Figure 2).

#### Fibrosis

Table 2 summarizes the extent of fibrosis in the lamina propria. There was 100% fibrosis in the FbG1 group, 33% in the CyAc group, and none in the control group. Figure 3 shows the fibrosis in the FbG1 group. There was significantly (p<0.001) more fibrosis in the FbG1 group and significantly (p<0.026) more fibrosis in the CyAc group than in the control group (Tables 2, 3).

#### Foreign body reaction

Only the FbG1 group showed a foreign body reaction (Table 2, Figure 4).

#### Cilia Loss

Cilia loss occurred in 90% of the rabbits in the FbG1 group and in 33% of the rabbits in the CyAc group (Table 2); the difference was statistically significant (p<0.001). The difference between the CyAc and control groups was also significant (p=0.026).



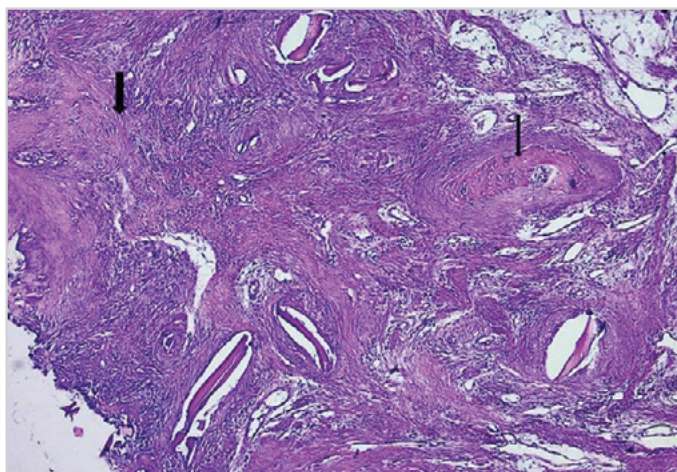


Figure 3. Fibrosis (thick arrow) and osteoneogenesis (thin arrow) in the FbG1 group (HE×100)

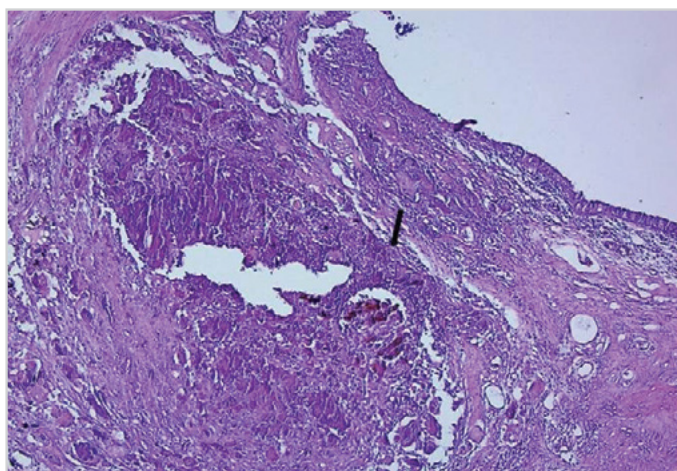


Figure 4. Foreign body reaction in the FbG1 group (arrow, HE×100)

### Osteogenesis

Both the FbG1 (50%) and CyAc (33%) groups showed significantly ( $p=0.002$ ) more osteogenesis than the control group (0%) (Table 2), although the difference between the FbG1 and CyAc groups was not significant ( $p=0.650$ ). Figure 3 shows osteogenesis in the FbG1 group.

### Serous Gland Loss

There was no loss of serous glands in the controls, while a significant ( $p<0.001$ ) loss was apparent in the FbG1 (100%) and CyAc (33%) groups (Table 2). The difference between the CyAc and control groups was not significant ( $p=0.084$ ).

### Discussion

We found that FbG1 increased inflammation. Erkan et al. (16) used FbG1 to attach a nasal mucoperichondrial flap to the septal cartilage of the nasal mucosa of albino Vienna rabbits and noted histologically apparent inflammation. In addition, the mucosal thickness increased, while the thicknesses of the perichondrium and cartilage decreased, cartilage damage was evident, ciliary and goblet cell numbers decreased, and fibrosis developed. Altuntaş et al. (3) evaluated the histopathological effects of FbG1

on the maxillary sinus mucosa of rats. After 21 days, no significant difference between FbG1 and saline was noted in terms of the extent of inflammation. In contrast, compared with controls, we observed a significant ( $p<0.001$ ) increase in inflammation when FbG1 was applied.

We also observed an increase in inflammation (compared with controls) when CyAc was applied, but this was not significant ( $p=0.234$ ). We could not find any study that applied CyAc to the respiratory mucosa of rabbits.

In a similar study, Alkan et al. (17) used CyAc to fix the septum to the anterior spine of New Zealand rabbits. Some inflammation was evident but disappeared after 8 weeks. No necrosis, foreign body reaction, or histotoxicity was observed.

Costa et al. (13) compared butyl-cyanoacrylate, gelatin-resorcin-formaldehyde (GRF), and suturing in the stabilization of cartilage grafts in New Zealand rabbits. No significant differences were evident among groups in terms of inflammation. In our study, no significant ( $p=0.234$ ) differences in inflammation were evident between the control and CyAc groups after week 3, while FbG1 caused significant ( $p<0.001$ ) inflammation.

Fibrosis was more extensive in the FbG1 group than in the control or CyAc groups ( $p<0.001$ ). Erkan et al. (16) noted similar results in a study of fibrosis in the nasal mucosa of rabbits. Dabb et al. (18) applied 2-octyl-cyanoacrylate to the nasal mucosa of nine patients and observed no fibrosis, inflammation, or erythema. Toriumi et al. (19) fixed the auricular cartilage to the nasal bone of rabbits using second-generation CyAc and observed no fibrosis. Our results differ from these reports in that FbG1 caused more fibrosis than CyAc and there was significantly more fibrosis in the CyAc group than in the control group.

In terms of foreign body reactions, Alkan et al. (17) used *n*-butyl-cyanoacrylate to fix the septum to the anterior nasal spine and found no significant foreign body reaction histopathologically in comparison with a control group. Egemen et al. (20) used FbG1 and suturing to secure a vascular anastomosis and compared this with suturing only in rats. The foreign body reaction was reduced using the glue/suturing combination. In our study, we did not find any foreign body reaction when CyAc was used, while FbG1 produced a significant ( $p<0.001$ ) foreign body reaction attributable to the sensitivity of the nasal mucosa relative to that of the vascular wall.

In terms of the numbers of cilia and serous cells, the FbG1 group showed significantly greater losses than the CyAc or control group. In the study of Erkan et al. (16), in which mucoperichondrial flaps were fixed to the mucosal septal cartilage in rabbits using FbG1, similar losses were apparent. Choi et al. (21) used CyAc to close sinus membrane perforations in rabbits and observed that the extent of the extracellular matrix but not serous gland numbers decreased. This was attributed to the regeneration of subepithelial serous glands. We also observed significant ( $p<0.001$ ) losses of cilia and serous cells (only 33%) in CyAc

compared with controls, and FbGl was associated with significant losses in both components ( $p<0.001$ ) compared with CyAc. This may be explained by tissue degeneration in the former and tissue regeneration in the latter.

Kania et al. (22) observed that FbGl accelerated bone formation under osteogenic conditions in a rabbit femoral defect model. In our study, there was no significant ( $p=0.650$ ) difference between the FbGl and CyAc groups but a significant ( $p=0.002$ ) difference between both these groups and controls. Overall, the increase in osteogenesis was more noticeable in the FbGl group (50%).

FbGl and CyAc have been used to repair various types of tissues. Petter-Puchner et al. (23) found no differences in terms of air penetration in the lung tissue of rabbits when FbGl and CyAc were used. However, FbGl was preferred because CyAc was associated with significantly higher levels of inflammation and elevated wound temperatures in the early stages of healing. Wieken et al. (24) compared FbGl and CyAc in the context of neural anastomosis in a rat model. CyAc caused inflammation, reminiscent of a foreign body reaction, and decrease in the neural diameter by 66%. Consequently, CyAc was not preferred for peripheral neural repair. In contrast, we found that CyAc was better than FbGl in all aspects studied. This may be attributable to the particular structural features of the mucosal tissue and the microvascular density therein.

This study had some weaknesses. The first was the side effects of maxillary sinus obliteration caused by FbGl and CyAc. The maxillary sinus mucosa and its aeration were preserved in the control group but not in the FbGl and CyAc groups. Another important weakness is that we did not evaluate the effects of FbGl and CyAc on the nasal mucosa.

## Conclusion

Histopathologically, CyAc had fewer side effects than FbGl. FbGl is also relatively expensive. Before either agent can safely be used on the paranasal sinus mucosa, they must be evaluated in larger groups and the long-term histopathological effects on various tissues should be explored.

**Ethics Committee Approval:** Ethics committee approval was received for this study from the ethics committee of Animal Ethics Committee of Bülent Ecevit University.

**Informed Consent:** Not required in this study.

**Peer-review:** Externally peer-reviewed.

**Author contributions:** Concept - S.S., S.B., M.B.U.; Design - S.S., S.B., M.B.U., E.S.; Supervision - S.B., M.B.U., E.S.; Resource - S.S., S.B., M.B.U.; Materials - S.S., S.B.; Data Collection &/or Processing - S.S., S.B., M.D., M.B.U., E.S., S.B.; Analysis &/or Interpretation - S.S., S.B., M.B.U., S.B.; Literature Search - S.S., S.B., M.D., E.S., S.B.; Writing - S.S., S.B., M.D., M.B.U.; Critical Reviews - M.D., M.B.U., E.S.

**Conflict of Interest:** No conflict of interest was declared by the authors.

**Financial Disclosure:** The authors declared that this study has received no financial support.

**Etik Komite Onayı:** Bu çalışma için etik komite onayı Bülent Ecevit Üniversitesi Hayvan Etik Kurulu'ndan alınmıştır.

**Hasta Onamı:** Bu çalışma için hasta onamına gerek yoktur.

**Hakem Değerlendirmesi:** Dış bağımsız.

**Yazar Katkıları:** Fikir - S.S., S.B., M.B.U.; Tasarım - S.S., S.B., M.B.U., E.S.; Denetleme - S.B., M.B.U., E.S.; Kaynaklar - S.S., S.B.; Gereçler - S.S., S.B.; Veri Toplanması ve/veya işleme - S.S., S.B., M.D., M.B.U., E.S., S.B.; Analiz ve/veya Yorum - S.S., S.B., M.B.U., S.B.; Literatür taraması - S.S., S.B., M.D., E.S., S.B.; Yazıyı Yazan - S.S., S.B., Eleştirel İnceleme - M.D., M.B.U., E.S.

**Çıkar Çatışması:** Yazarlar çıkar çatışması bildirmemişlerdir.

**Finansal Destek:** Yazarlar bu çalışma için finansal destek almadıklarını beyan etmişlerdir.

## References

- Schneider G. Tissue adhesives in otorhinolaryngology. *Laryngorhinootologie* 2009; 88: S156-64. [CrossRef]
- Cheng H, Almström S, Olson L. Fibrin glue used as an adhesive agent in CNS tissues. *J Neural Transplant Plast* 1995; 5: 233-43. [CrossRef]
- Altuntaş EE, Özer H, Çetin B, Müderris S. Histopathological effects of fibrin glue in maxillary sinus mucosa: An experimental study. *Cumhuriyet Medical J* 2011; 33: 338-43.
- Sakagami M, Yuasa R, Yuasa Y. Simple underlay myringoplasty. *J Laryngol Otol* 2007; 121: 840-4. [CrossRef]
- Bozorg Grayeli A, Mosnier I, Julien N, El Garem H, Bouccara D, Sterkers O. Long-term functional outcome in facial nerve graft by fibrin glue in the temporal bone and cerebellopontine angle. *Eur Arch Otorhinolaryngol* 2005; 262: 404-7. [CrossRef]
- de Vries J, Menovsky T, van Gulik S, Wesseling P. Histological effects of fibrin glue on nervous tissue: a safety study in rats. *Surg Neurol* 2002; 57: 415-22. [CrossRef]
- Takahashi N, Ichimiya Y, Mawatari T, Kusajima K, Komatsu S. The reinforcement of tracheoplasty with a self-fascia lata and gelatin-resorcin-formal (GRF) glue. *Surg Today* 1997; 27: 1046-50. [CrossRef]
- Graefe H, Wollenberg B, Brocks C. Application of skin adhesives in head and neck surgery: analysis of cosmetic results, applicability and cost-effectiveness of cyanoacrylate-based adhesives. *HNO* 2008; 56: 947-54. [CrossRef]
- Park MS. Autologous fibrin glue for tympanoplasty. *Am J Otol* 1994; 15: 687-9.
- Pineros-Fernandez A, Rodeheaver PF, Rodeheaver GT. Octyl-2-cyanoacrylate for repair of peripheral nerve. *Ann Plast Surg* 2005; 55: 188-95. [CrossRef]
- Bruns TB, Robinson BS, Smith RJ, Kile DL, Davis TP, Sullivan KM, et al. A new tissue adhesive for laceration repair in children. *J Pediatr* 1998; 132: 1067-70. [CrossRef]
- Gulalp B, Seyhan T, Gursoy S, Altınors MN. Emergency wounds treated with cyanoacrylate and long-term results in pediatrics: A series of cases; what are the advantages and boards? *BMC Res Notes* 2009; 2: 132-5. [CrossRef]
- Costa HJ, Pereira CS, Costa MP, Fabri FS, Lancellotti CL, Dolci JE. Comparison of butyl-2-cyanoacrylate, gelatin-resorcin-formalde-

- hyde (GRF) compound and suture in stabilization of cartilage grafts in rabbits. *Braz J Otorhinolaryngol* 2006; 72: 61-71. [\[CrossRef\]](#)
14. DeGuillebon H, Zauberman H, Refojo MF. Cyanoacrylate adhesive: Use in the removal of lens and foreign particles from the vitreous cavity. *Arch Ophthalmol* 1972; 87:407-10. [\[CrossRef\]](#)
  15. Penoff J. Skin closures using cyanoacrylate tissue adhesives. Plastic Surgery Educational Foundation DATA Committee. Device and Technique Assessment. *Plast Reconstr Surg* 1999; 103: 730-1. [\[CrossRef\]](#)
  16. Erkan AN, Cakmak O, Kocer NE, Yilmaz I. Effects of fibrin glue on nasal septal tissues. *Laryngoscope* 2007; 117: 491-6. [\[CrossRef\]](#)
  17. Alkan S, Dadaş B, Celik D, Coskun BU, Yilmaz F, Başak T. The efficacy of N-2-butyl cyanoacrylate in the fixation of nasal septum to the anterior nasal spine in rabbits: experimental study. *Eur Arch Otorhinolaryngol* 2007; 264: 1425-30. [\[CrossRef\]](#)
  18. Dabb RW, Gaffield JW, Camp LA. Use of cyanoacrylate (super glue) for the fixation and prefabrication of nasal cartilage grafts. *Aesthet Surg J* 2001; 21: 328-33. [\[CrossRef\]](#)
  19. Toriumi DM, Raslan WF, Friedman M, Tardy ME Jr. Variable histotoxicity of Histoacryl when used in a subcutaneous site: an experimental study. *Laryngoscope* 1991; 101: 339-43. [\[CrossRef\]](#)
  20. Egemen O, Ugurlu K, Ozkaya O, Sacak B, Sakiz D, Bas L. Anastomosis with fish-mouth technique using fibrin glue. *J Craniofac Surg* 2011; 22: 1047-51. [\[CrossRef\]](#)
  21. Choi BH, Kim BY, Huh JY, Lee SH, Zhu SJ, Jung JH, et al. Cyanoacrylate adhesive for closing sinus membrane perforations during sinus lifts. *J Craniomaxillofac Surg* 2006; 34: 505-9. [\[CrossRef\]](#)
  22. Kania RE, Meunier A, Hamadouche M, Sedel L, Petite H. Addition of fibrin sealant to ceramic promotes bone repair: Long-term study in rabbit femoral defect model. *J Biomed Mater Res* 1998; 43: 38-45. [\[CrossRef\]](#)
  23. Petter-Puchner AH, Simunek M, Redl H, Puchner KU, Van Griensven M. A comparison of a cyanoacrylate glue (Glubran) vs. fibrin sealant (Tisseel) in experimental models of partial pulmonary resection and lung incision in rabbits. *J Invest Surg* 2010; 23: 40-7. [\[CrossRef\]](#)
  24. Wieken K, Angioi-Duprez K, Lim A, Marchal L, Merle M. Nerve anastomosis with glue: Comparative histologic study of fibrin and cyanoacrylate glue. *J Reconstr Microsurg* 2003; 19: 17-20. [\[CrossRef\]](#)