

Retrospective Analysis of Surgically Managed Maxillofacial Fractures in Kayseri Training and Research Hospital

Kayseri Eğitim ve Araştırma Hastanesi'nde Cerrahi Olarak Tedavi Edilen Maksillofasial Fraktürlerin Geriye Dönük Analizi

Original Investigation
Özgün Araştırma

Mehmet Yaşar, Ali Bayram, Murat Doğan, Mustafa Sağıt, Altan Kaya, İbrahim Özcan, Cemil Mutlu
Department of Otorhinolaryngology, Kayseri Training and Research Hospital, Kayseri, Turkey

Abstract

Objective: To retrospectively evaluate the clinical and surgical data of patients with maxillofacial fracture (MFF) who were surgically treated at the Department of ENT and Head Neck Surgery in the Kayseri Training and Research Hospital and to compare and discuss the results with relevant literature, including that from Turkey.

Methods: Data concerning the age, gender, etiology, type and site of injury, treatment modality, and postoperative complications were collected and analyzed from medical records of patients who underwent maxillofacial surgery for MFF at the Department of ENT and Head Neck Surgery in the Kayseri Training and Research Hospital between January 2013 and March 2015.

Results: A total of 35 patients were surgically treated because of MFF between January 2013 and March

2015. Of the 35 patients, 28 (80%) were male, whereas seven (20%) were female. Traffic accidents (40%) were the most frequent cause of MFFs. Mandibular fractures (49.1%) were the most common fractures, followed by zygomatic fractures (31.6%). Surgical management of MFFs was performed via closed reduction (17.5%) and/or open reduction with internal fixation by miniplates (82.5%). A total of five complications were observed in the present study: malunion (n=2), removal of fixation plate because of infection (n=2), and permanent infraorbital nerve injury (n=1).

Conclusion: Based on the experience from the close proximity of the area, we think that surgeries for MFFs should be in the surgical repertoire of ENT surgeons.

Keywords: Maxillofacial injuries, etiology, maxillofacial surgery

Öz

Amaç: Kayseri Eğitim ve Araştırma Hastanesi, KBB ve Baş Boyun Cerrahisi Bölümü'nde maksillofasial fraktür (MFF) nedeniyle cerrahi olarak tedavi edilen hastaların klinik ve cerrahi bilgilerinin değerlendirilmesi ve aynı zamanda elde edilen sonuçların Türkiye de dahil olmak üzere ilgili literatür ile karşılaştırılması ve yorumlanması.

Yöntemler: Ocak 2013 ile Mart 2015 tarihleri arasında, MFF nedeniyle Kayseri Eğitim ve Araştırma Hastanesi, KBB ve Baş Boyun Cerrahisi Bölümü'nde maksillofasial cerrahi geçiren hastaların yaş, cinsiyet, kırık tipi ve yerleşimi, tedavi yaklaşımı ve ameliyat sonrası komplikasyonları ile ilgili bilgileri medikal kayıtlardan toplanarak incelendi.

Bulgular: Ocak 2013 ve Mart 2015 arasında toplam 35 hasta MFF nedeniyle cerrahi olarak tedavi edildi.

Bu 35 hastanın 28'i (%80) erkek, yedisi (%20) bayan idi. Trafik kazaları (%40), MFF'lerin en sık nedeni idi. Mandibula (%49.1) en sık görülen fraktür bölgesi idi, zigomatik kırıklar (%31.6) mandibulayı takip ediyordu. Cerrahi tedavi kapalı redüksiyon (%17.5) ya da açık redüksiyon ve miniplak ile internal fiksasyon (%82.5) yoluyla yapıldı. Toplamda görülen beş komplikasyonu malunion (n=2), enfeksiyon nedeniyle fiksasyon plağının çıkarılması (n=2) ve kalıcı infraorbital sinir hasarı (n=1) oluşturmaktadır.

Sonuç: Bölgeye olan yakınlıktan kazanılan klinik deneyime dayanarak, MFF cerrahilerinin KBB cerrahilerinin cerrahi dağarcığında bulunması gerektiğini düşünmekteyiz.

Anahtar Kelimeler: Maksillofasial yaralanmalar, etiyoloji, maksillofasial cerrahi

Introduction

Maxillofacial fracture (MFF) is a serious condition that may impede the functions of several structures, including the patient's airway, masticatory system, olfactory and ocular function, as well as

aesthetic appearance. The prevalence and etiology of MFF differs among countries depending on the local demographic, cultural, and socioeconomic conditions (1). Several investigations focusing on the epidemiology and treatment of MFF have



Address for Correspondence/Yazışma Adresi:
Ali Bayram
E-mail: dralibayram@gmail.com

Received Date/Geliş Tarihi: 07.02.2016
Accepted Date/Kabul Tarihi: 23.04.2016

© Copyright 2016 by Official Journal of the Turkish Society of Otorhinolaryngology and Head and Neck Surgery Available online at
www.turkarchotorhinolaryngol.org

© Telif Hakkı 2016 Türk Kulak Burun Boğaz ve Baş Boyun Cerrahisi Derneği Makale metnine
www.turkarchotorhinolaryngol.org web sayfasından ulaşılabilir.

DOI: 10.5152/tao.2016.1501

been reported from different countries, including Turkey (2-5). However, alterations of the socioeconomic status of countries as well as technological improvements in trends of treatment modalities necessitate periodic verification of clinical data concerning MFF. The aim of the present study was to retrospectively evaluate the clinical and surgical data concerning age, gender, etiology, type and site of injury, treatment modality, and postoperative complications of patients who were surgically treated because of MFFs in our clinic and to compare and discuss the results with relevant literature, including that from Turkey.

Methods

Between January 2013 and March 2015, patients who underwent surgical treatment under general anesthesia because of MFFs at the Department of ENT and Head Neck Surgery of the Kayseri Training and Research Hospital were retrospectively evaluated in the present study. The confirmation of MFF necessitating surgery was performed by the physical examination of patients, including full head and neck region and computed tomography with axial and coronal planes, in addition to three-dimensional reconstruction of images. The evaluation and surgical intervention of the patients were performed by the same surgeon (MY). Data concerning the age, gender, etiology, type and site of injury, treatment modality, and postoperative complications were collected and analyzed from patients' medical records. Written informed consent was obtained from the subjects who participated in the present study, and the study protocol was approved by the local ethics committee with the document no. 2016/179.

The etiology of trauma was classified into traffic accidents, interpersonal violence, falls, and sport- or work-related accidents. Mandibular fractures were subdivided into angle, condyle, body, symphysis, parasymphysis, subcondyle, and ramus. Maxillary fractures were determined according to the Le-Fort classification (6).

Zygomatic fractures were classified into zygomatic arch, infraorbital rim, blow-out (Figure 1 a, b), and tripod fractures. Because the treatment of patients with isolated nasal fractures was mostly performed in an outpatient manner, they were excluded from the study.

Surgical management of MFFs was performed via closed reduction or open reduction with internal fixation by miniplates (Depuy Synthes GmbH; Oberdorf, Switzerland) under general anesthesia. Single fractures without displacement or malocclusion were treated via closed reduction. The complex fractures such as multiple, displaced, and/or fractures with malocclusion were treated via open reduction with internal fixation. Intermaxillary fixation was performed for any patients who had mandibular and maxillary fractures for at least 30 days with arch bar wires. All the incisions were made intraorally, except for zygomatic and condyle fractures. Infraorbital rim and blow-out fractures were reduced via subciliary incision. The Gillies approach was used for zygomatic arch reduction. For tripod fractures, gingivo-labial sulcus and lateral rim incision were simultaneously applied to reduce the fracture sites. Patients were followed at least for 6 months after surgery, and complications were recorded at the end of the follow-up period. Statistical analysis was performed using Statistical Package for the Social Sciences (v. 15; SPSS Inc.; Chicago, IL, USA).

Results

Thirty-five patients were surgically treated between January 2013 and March 2015 at the Department of ENT and Head Neck Surgery of the Kayseri Training and Research Hospital. Of the 35 patients, 28 (80%) were male, whereas seven (20%) were female. The mean age was 33.5 ± 12.6 years, ranging from 18 to 67 years. Traffic accidents (40%, n=14) were the most frequent cause of MFFs among the 35 cases, whereas interpersonal

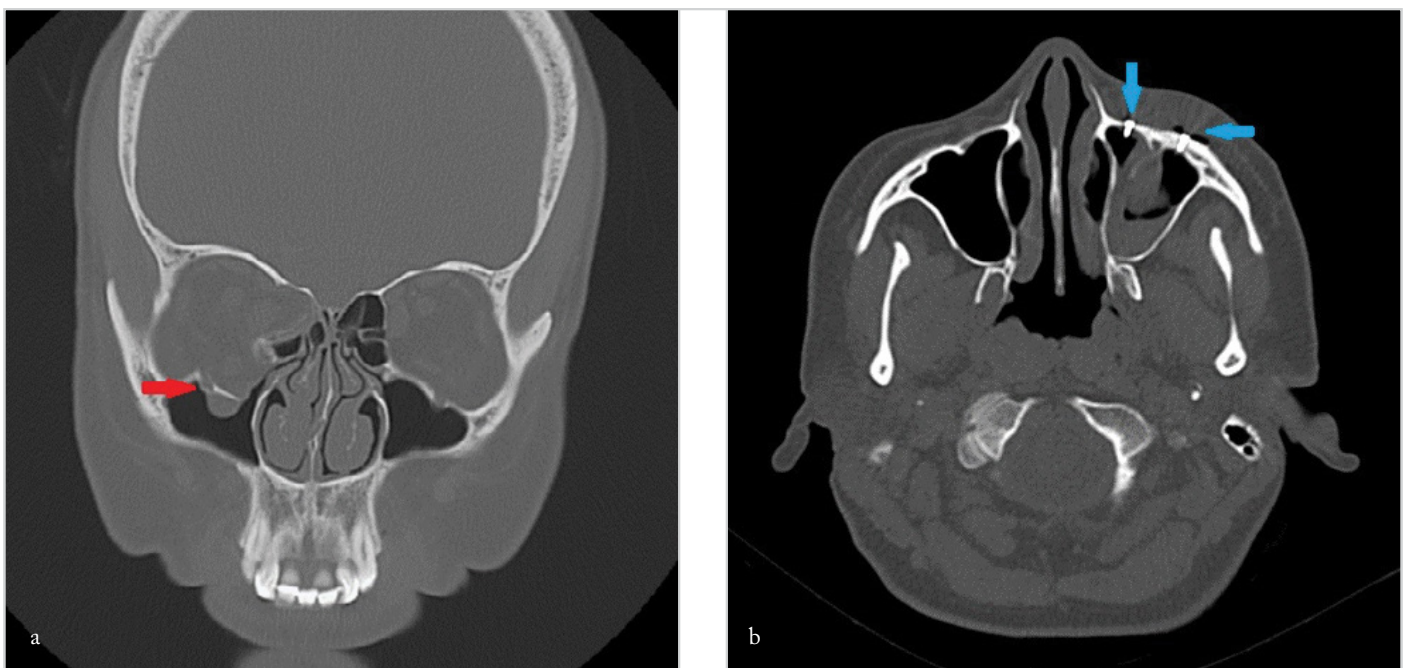


Figure 1. a, b. Coronal CT scan shows blow-out fracture on the right side (red arrow) (a). Postoperative axial CT scan demonstrates internal fixation by miniplates (blue arrows) (b)

violence (28.6%, n=10) and falls (28.6%, n=10) had an equal ratio. Sport-related accident was encountered in one (2.8%, n=1) patient.

In the present study, a total of 57 fractures were determined in 35 patients. Nineteen (54.3%) patients had simple facial fractures, while 16 (45.7%) had multiple facial fractures. Among the 57 MFFs, there were 28 (49.1%) mandibular, 18 (31.6%) zygomatic, six (10.5%) maxillary, and five (8.8%) nasal fractures. A total of 28 mandibular fractures were encountered in 20 patients. Mandibular fractures were mostly unifocal (65%, n=13), followed by bifocal fractures (30%, n=6) (Figure 2 a, b). Triple fracture was determined in one patient (5%). All patients with mandibular fractures had no other facial fractures. Parasymphysis (39.3%, n=11) was the most common fracture site among the 28 mandibular fractures. The site distribution of mandibular fractures is shown in Figure 3. A total of 18 zygomatic fractures were determined in 15 patients. The most common fracture site was the inferior orbital rim (38.9%, n=7) among the 18 zygomatic fractures. The site distribution of zygomatic fractures is shown in Figure 4. Six patients with zygomatic fractures also had Le-Fort I type maxillary fractures. Nasal fracture was accompanied by zygomatic fracture in five patients.

Surgical management of MFFs includes closed reduction and/or open reduction with internal fixation by miniplates. Surgical treatment modalities according to the site of MFFs are shown in Table 1. Among the 25 mandibular fractures treated with open reduction, 22 fractures (88%) were operated via intraoral incision, whereas three patients (3%) with condylar fractures were underwent reduction through an external incision. Six zygomatic fractures (37.5%), which were accompanied by maxillary fractures, were treated via an intraoral and external approach, whereas the remaining 10 fractures (62.5%) of the zygomatic

site were subjected to external incision. A total of five complications were observed in the present series. These were malunion (n=2), removal of the fixation plate due to infection (n=2), and permanent infraorbital nerve injury (n=1). Malunion and removal of fixation plates occurred in patients with mandibular fractures who underwent open surgery. Patients with malunion did not accept a second operation. Permanent infraorbital nerve injuries were observed in one case with zygomatic fracture.

Discussion

The prevalence of maxillofacial injuries has been reported to be between 45.3% and 60% in all traumatic cases (7). MFFs are more frequent in males aged 21–30 years, according to the epidemiologic studies (8-10). Gönüllü et al. (7) reported that the male-to-female ratio was 5:1, with the mean age of 23.61 ± 16.75 , in 246 cases with MFFs in their study. Most patients were young males in the present study, which was compatible that observed in the literature. The young male predominance may be explained by the more frequent exposure of males to etiological agents than females as well as other age groups.

The incidence of etiological factors associated with MFFs is influenced by local demographic, cultural, and socioeconomic conditions of countries. Interpersonal violence has been reported to be the most common cause of facial injuries in developed countries, whereas traffic accidents are the main cause in developing countries (1, 11, 12). Traffic accidents are the most common cause of MFFs in most papers published in Turkey (13-15); this is in accordance with the data from developing countries. However, Bozkuş et al. (16) reported interpersonal violence to be the most common cause of MFF in 78 patients. Traffic accidents (40%) were the main etiological agent in the present study; this is consistent with the data reported for developing countries.

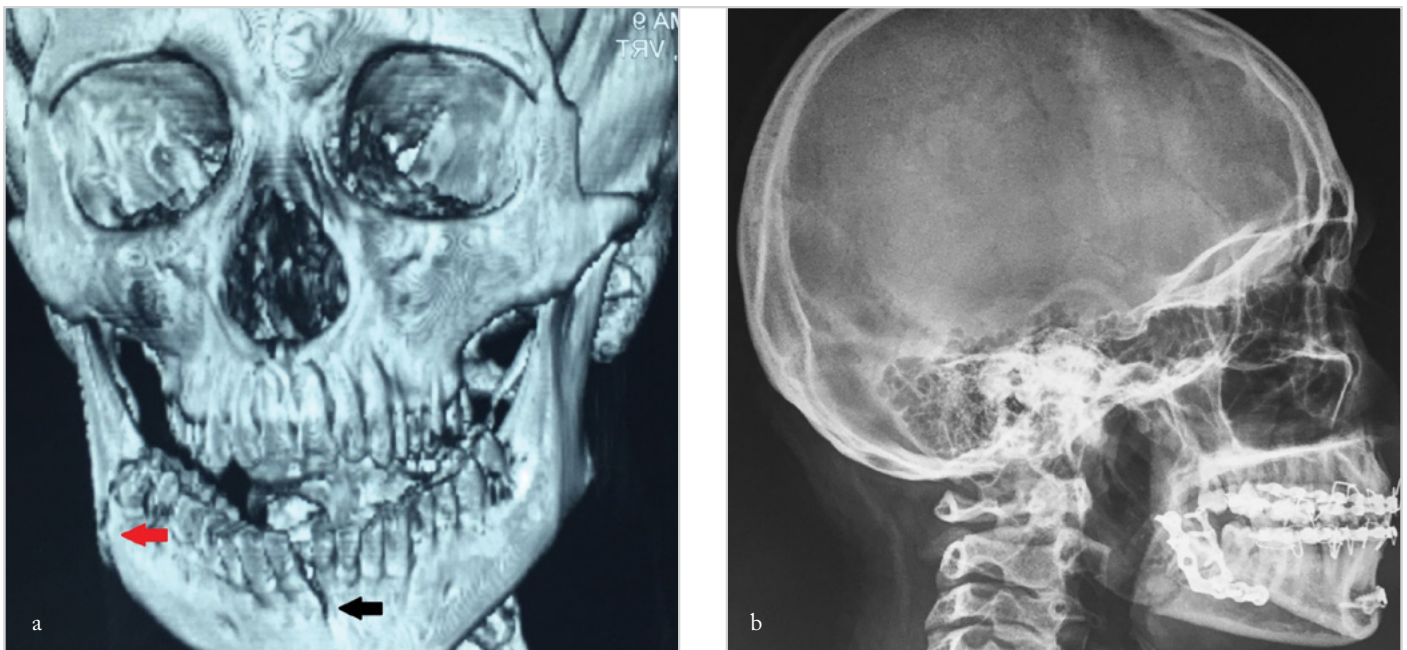


Figure 2. a, b. Three-dimensional tomography of bifocal mandibular fracture (black arrow: symphysis fracture; red arrow: angle fracture) (a) Postoperative plain graphy of the patient demonstrates internal fixation by miniplates with intermaxillary fixation (b)

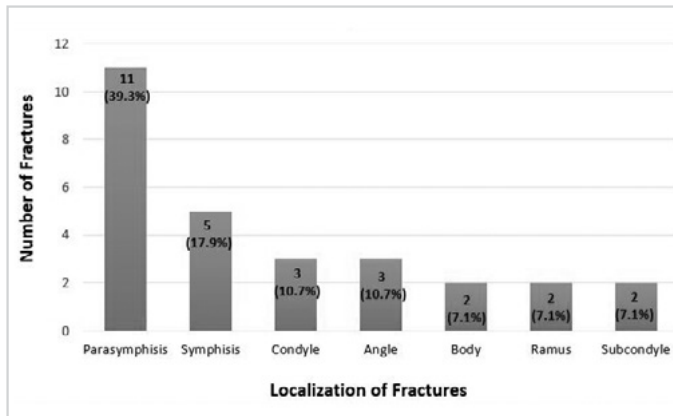


Figure 3. Site distribution of mandibular fractures

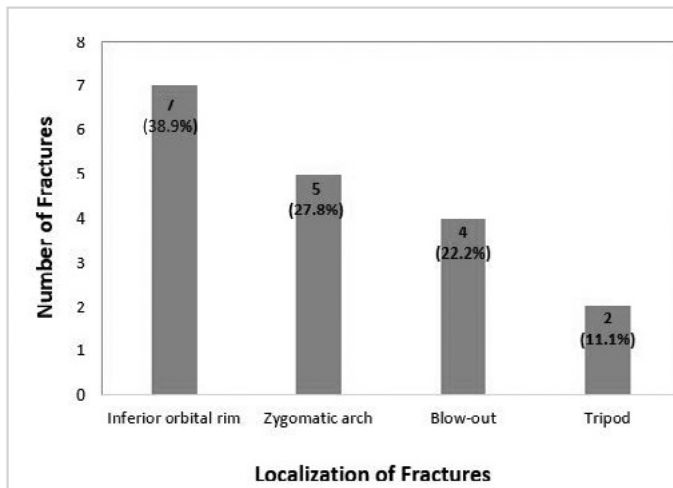


Figure 4. Site distribution of zygomatic fractures

Table 1. Surgical treatment modalities according to the site of maxillofacial fractures

	Open reduction+ internal fixation	Closed reduction
Mandibular	25 (89.3%)	3 (10.7%)
Zygomatic	16 (88.9%)	2 (11.1%)
Maxillary	6 (100%)	0
Nasal	0	5 (100%)
Total	47 (82.5%)	10 (17.5%)

The mandible (49.1%) was the most common site of injury among MFFs in the present study, which was in agreement with findings reported by other authors, those from including Turkey (1, 5, 13, 14, 17, 18). The most common fracture site was highly variable in the literature. The body of the mandible (19), parasymphysis (13), condyle (15), and angle (20) were demonstrated as the most prevalent locations of fracture in different studies. Motamedi et al. (2) reported the symphyseal–parasymphyseal region (27.2%) to be the most common area in a study on 5737 mandibular fractures. Demir et al. (13) reported that the 32% of mandibular fractures were related to parasymphysis, followed by angle (16%), in their study on 52 patients with 67 fracture

lines in the mandible. Kırış et al. (14) reported that parasymphysis fractures (31.5%) were the most common fractures among 115 mandibular fractures. On the other hand, in some other papers published in Turkey, body and condyle/subcondyle regions were reported to be the most frequent mandibular fracture sites (27.1% and 24.2%, respectively) (15, 16). Parasymphysis (39.3%) constituted the most common fracture site, followed by the symphysis area, among the mandibular fractures in our study. The variable results on the prevalence of fracture sites in the literature may be originated from the variations in the etiology of fractures as well as the number of patients participating in these studies.

Zygomatic fractures accounted for 31.6% of all MFFs in the present study. The inferior orbital rim was the most common fracture site (38.9%), followed by the zygomatic arch (27.8%). Erol et al. (21) reported infraorbital rim fractures in 351 of 743 zygomatic fractures with the most prevalent occurrence. Demir et al. (13) also reported the inferior orbital rim to be the most common injury site in zygomatic fractures (36%). In both studies, the zygomatic arch was the second most common fracture site. The findings of the present study are consistent with these results.

The management of MFFs varies according to the surgeon’s preference as well as the technical capacities concerning available instrumentation. In recent years, depending on the innovations in surgical tools, plate osteosynthesis has gained priority in proper cases (22, 23). The main advantages of this approach include stable and precise reduction of fragments, early recovery due to the rapid bone remodeling, and consolidation in the fracture line (24). In the present study, open reduction and internal fixation by miniplates accounted for the majority of surgical procedures (82.5%) and were our main clinical approach to treat MFFs. A total of five complications were observed in the present study: malunion (n=2), removal of fixation plate due to infection (n=2), and permanent infraorbital nerve injury (n=1). Malunion and removal of the fixation plate occurred in patients with mandibular fracture treated with open surgery. Infection has been reported as the most frequent postoperative complication after mandibular fractures (25, 26). Lamphier et al. (26) showed that open surgery has higher complication rates than closed reduction even with improved plating systems. In the present study, all complications concerning mandibular fractures were encountered after open surgery.

Conclusion

Traffic accidents were the main cause of MFFs in the present study; this is similar to data reported from developing countries. The mandible was the most common fracture site, and the most preferred surgical treatment modality was open reduction and internal fixation by miniplates, reflecting the current trends in the treatment of MFFs. The major limitation of the present study was the small sample size, which was probably a consequence of the reduced number of ENT calls from emergency departments for MFFs in recent years. However, based on the experience from the close proximity of the area, we think that surgeries for MFFs should be in the surgical repertoire of ENT surgeons.

Ethics Committee Approval: Ethics committee approval was received for this study from the ethics committee of the Kayseri Erciyes University School of Medicine / No: 2016-179.

Informed Consent: Written informed consent was obtained from patients who participated in this study.

Peer-review: Externally peer-reviewed.

Author Contributions: Concept - M.Y., A.B.; Design - A.B., M.Y.; Supervision - M.D., M.S., C.M., İ.Ö.; Resources - M.Y.; Materials - M.Y., A.B.; Data Collection and/or Processing - A.B., M.Y.; Analysis and/or Interpretation - A.B.; Literature Search - A.B.; Writing Manuscript - A.B., M.Y.; Critical Review - M.D., M.S., C.M., İ.Ö.; Other - M.Y., A.B., M.D., M.S., C.M., İ.Ö.

Conflict of Interest: No conflict of interest was declared by the authors.

Financial Disclosure: The authors declared that this study has received no financial support.

Etik Komite Onayı: Bu çalışma için etik komite onayı Kayseri Erciyes Üniversitesi Tıp Fakültesi'nden alınmıştır / No: 2016-179.

Hasta Onamı: Yazılı hasta onamı bu çalışmaya katılan hastalardan alınmıştır.

Hakem Değerlendirmesi: Dış bağımsız.

Yazar Katkıları: Fikir - M.Y.; Tasarım - A.B., M.Y.; Denetleme - M.D., M.S., C.M., İ.Ö.; Kaynaklar - M.Y., A.B.; Gereçler - M.Y., A.B.; Veri Toplanması ve/veya İşlenmesi - A.B., M.Y.; Analiz ve/veya Yorum - A.B.; Literatür Taraması - A.B.; Yazıyı Yazan - A.B., M.Y.; Eleştirel İnceleme - M.D., M.S., C.M., İ.Ö.; Diğer - M.Y., A.B., M.D., M.S., C.M., İ.Ö.

Çıkar Çatışması: Yazarlar çıkar çatışması bildirmemişlerdir.

Finansal Destek: Yazarlar bu çalışma için finansal destek almadıklarını beyan etmişlerdir.

References

- Chrcanovic BR. Factors influencing the incidence of maxillofacial fractures. *Oral Maxillofac Surg* 2012; 16: 3-17. [CrossRef]
- Motamedi MH, Dadgar E, Ebrahimi A, Shirani G, Haghghat A, Jamalpour MR. Pattern of maxillofacial fractures: a 5-year analysis of 8,818 patients. *J Trauma Acute Care Surg* 2014; 77: 630-4. [CrossRef]
- Erol B, Tanrikulu R, Görgün B. Maxillofacial fractures. Analysis of demographic distribution and treatment in 2901 patients (25-year experience). *J Craniomaxillofac Surg* 2004; 32: 308-13. [CrossRef]
- Brasileiro BF, Passeri LA. Epidemiological analysis of maxillofacial fractures in Brazil: a 5-year prospective study. *Oral Surg Oral Med Oral Pathol Oral Radiol Endod* 2006; 102: 28-34. [CrossRef]
- Pham-Dang N, Barthélémy I, Orliaguet T, Artola A, Mondié JM, Dallel R. Etiology, distribution, treatment modalities and complications of maxillofacial fractures. *Med Oral Patol Oral Cir Bucal* 2014; 19: 261-9. [CrossRef]
- Gartshore L. A brief account of the life of René Le Fort. *Br J Oral Maxillofac Surg* 2010; 48: 173-5. [CrossRef]
- Gönüllü H, Karadaş S, Işık D, Koçak ÖF, Tekin H. Maxillofacial trauma cases applying to an emergency service: a retrospective study. *Turk Plast Surg* 2011; 19: 121-4.
- Kieser J, Stephenson S, Liston PN, Tong DC, Langley JD. Serious facial fractures in New Zealand from 1979 to 1998. *Int J Oral Maxillofac Surg* 2002; 31: 206-9. [CrossRef]
- Torgersen S, Tornes K. Maxillofacial fractures in a Norwegian district. *Int J Oral Maxillofac Surg* 1992; 21: 335-8. [CrossRef]
- Mijiti A, Ling W, Tuerdi M, Maimaiti A, Tuerxun J, Tao YZ, et al. Epidemiological analysis of maxillofacial fractures treated at a university hospital, Xinjiang, China: a 5-year retrospective study. *J Craniomaxillofac Surg* 2014; 42: 227-33. [CrossRef]
- Kontio R, Suuronen R, Ponkkonen H, Lindqvist C, Laine P. Have the causes of maxillofacial fractures changed over the last 16 years in Finland? An epidemiological study of 725 fractures. *Dent Traumatol* 2005; 21: 14-9. [CrossRef]
- Lee KH. Interpersonal violence and facial fractures. *J Oral Maxillofac Surg* 2009; 67: 1878-83. [CrossRef]
- Demir Z, Öktem F, Velidedeği H, Çelebioğlu S. Analysis of 121 patients with maxillofacial fractures and comparison with the literature. *KBB-Forum* 2008; 7: 85-90.
- Kırış M, Yuca K, Çelebi S, Kiroğlu F, Çankaya H. Treatment modalities in maxillofacial fractures: Retrospective analysis. *Türkiye Klinikleri J Med Sci* 2009; 29: 696-701.
- Şakrak T, Köse A, Karabağlı Y, Elmas İ, Tekgöz A, Çetin C. A retrospective analysis of 232 patients with maxillofacial trauma and treatment protocols of our clinic. *Turk Plast Surg* 2010; 18: 66-9.
- Bozkuş F, İylen İ, Şan İ. Retrospective analysis of the patients with maxillofacial traumas. *Tıp Araştırmaları Dergisi* 2011; 9: 10-6.
- Ascani G, Di Cosimo F, Costa M, Mancini P, Caporale C. Maxillofacial Fractures in the province of Pescara, Italy: A retrospective study. *ISRN Otolaryngol* 2014; 2014: 101370. [CrossRef]
- Mabrouk A, Helal H, Mohamed AR, Mahmoud N. Incidence, etiology, and patterns of maxillofacial fractures in Ain-Shams University, Cairo, Egypt: A 4-year retrospective study. *Craniomaxillofac Trauma Reconstr* 2014; 7: 224-32. [CrossRef]
- Roode GJ, van Wyke PJ, Botha SJ. Mandibular fractures: an epidemiological survey at the Oral and Dental Hospital, Pretoria. *SADJ* 2007; 62: 272-4.
- Ogundare BO, Bonnick A, Bayley N. Pattern of mandibular fractures in an urban major trauma center. *J Oral Maxillofac Surg* 2003; 61: 713-8. [CrossRef]
- Erol B, Özer N, Tanrikulu R, Gülsün B, Atay Ç. Maxillo-facial fractures: Retrospective study of the 2308 cases. *Turkish J Trauma and Emergency Surg* 1998; 4: 162-7.
- Sauerbier S, Schön R, Otten JE, Schmelzeisen R, Gutwald R. The development of plate osteosynthesis for the treatment of fractures of the mandibular body - a literature review. *J Craniomaxillofac Surg* 2008; 36: 251-9. [CrossRef]
- Rallis G, Stathopoulos P, Igoumenakis D, Krasadakis C, Mourouzis C, Mezitis M. Treating maxillofacial trauma for over half a century: how can we interpret the changing patterns in etiology and management? *Oral Surg Oral Med Oral Pathol Oral Radiol* 2015; 119: 614-8. [CrossRef]
- Laskin DM, Best AM. Current trends in the treatment of maxillofacial injuries in the United States. *J Oral Maxillofac Surg* 2000; 58: 207-15. [CrossRef]
- Moulton-Barrett R, Rubinstein AJ, Salzhauer MA, Brown M, Angulo J, Alster C, et al. Complications of mandibular fractures. *Ann Plast Surg* 1998; 41: 258-63. [CrossRef]
- Lamphier J, Ziccardi V, Ruvo A, Janel M. Complications of mandibular fractures in an urban teaching center. *J Oral Maxillofac Surg* 2003; 61: 745-9. [CrossRef]