DOI: 10.4274/jcrpe.galenos.2021.2020.0258

Case report

SILENT CORTICOTROPH TUMOR WITH ADRENOCORTICAL CHORISTOMA IN AN ELEVEN-YEAR-OLD BOY

Hande Turan[1], Gürkan Tarçın[1], Özgür Mete[2 3], Ada Bulut Sinoplu, Saadet Olcay Evliyaoğlu[1], Büge Öz ,Oya Ercan[1]
[1]Istanbul University-Cerrahpaşa, Cerrahpaşa Faculty of Medicine, Department of Pediatric Endocrinology, Istanbul, Turkey.
[2]University of Toronto, Department of Laboratory Medicine and Pathobiology,Toronto, Canada
[3]University Health Network, Department of Pathology, Toronto, Canada
[4]Istanbul University-Cerrahpaşa, Cerrahpaşa Faculty of Medicine Department of pediatrics, Istanbul, Turkey
[5]Istanbul University-Cerrahpaşa, Cerrahpaşa Faculty of Medicine, Department of Pathology, Istanbul, Turkey

WHAT IS ALREADY KNOWN ON THIS TOPIC?
Silent corticotroph adenomas (SCAs) do not manifest biochemical or clinical evidence of hypercortisolism, but are immunopositive for ACTH and Tpit the transcription factor of functioning and silent corticotroph adenomas which is useful in diagnosis of corticotroph and null cell adenoma .The existence of adrenocortical cells within the pituitary gland, which can be explained as a choristoma, is a very rare entity, and the co-occurrence of these two entities have only been reported in few cases.

WHAT THIS STUDY ADDS?
Adrenocortical choristoma in SCA is a very rare entity, and herein, to our knowledge, we describe the fourth and the youngest patient reported until now.

Abstract
Silent corticotroph tumors are composed of corticotroph cells, but do not manifest any biochemical or clinical evidence of hypercortisolism. A choristoma is a benign, congenital proliferation of histologically mature tissue elements normally not present at the site of occurrence. The existence of adrenocortical cells within the pituitary gland, which can be explained as a choristoma, is a very rare entity, and the co-occurrence of these two entities have only been reported in few cases. In the present case, we report an 11-year-old boy with central hypothyroidism. In his cranial magnetic resonance imaging a pituitary tumor was detected, and histopathological studies led to a diagnosis of an adrenal choristoma and a silent corticotroph tumor in the pituitary gland. The presence of adrenocortical cells were confirmed with positive calretinin, inhibin and Melan A staining, and the corticotroph cells with adrenocorticotropic hormone immunohistochemistry. Herein, we report the fourth and the youngest case of silent corticotroph tumor with adrenocortical choristoma in the literature. Even though the underlying mechanism is not fully understood, suggested mechanisms are discussed in the paper.
Keywords: adrenocortical choristoma, corticotroph adenoma, steroidogenic factor 1

Address for Correspondence: MD. Hande TURAN
Istanbul University-Cerrahpaşa, Cerrahpaşa Faculty of Medicine, Department of Pediatric Endocrinology, Istanbul, Turkey
+90 05059113735
dr.handeerdogan@gmail.com
0000-0003-0121-3756
12.11.2020
09.02.2021

Introduction
Corticotroph adenomas (CAs) comprise approximately 10% of all pituitary tumors (1). Functional CAs are associated with elevated circulating adrenocorticotrophic hormone (ACTH) and cortisol levels leading to Cushing disease with features of hypercortisolism or Nelson's syndrome (2). Up to 20% of CAs are known as silent corticotroph adenomas (SCAs), and they do not manifest biochemical or clinical evidence of hypercortisolism, whereas both silent and functional CAs are immunopositive for ACTH and Tpit, the transcription factor of functioning and silent corticotroph adenomas which is useful in diagnosis of corticotroph and null cell adenoma (3–5). Silent corticotroph adenomas comprise very little of the overall nonfunctional pituitary adenomas. Despite being silent, they show aggressive behavior (6).
A choristoma is a benign, congenital proliferation of histologically mature tissue elements normally not present at the site of occurrence. This heterotopic congenital mass results from normal tissue elements migrating to or remaining in an abnormal location during embryogenesis. Adrenocortical choristomas have been identified in a wide variety of other non-steroidogenic tissues, including kidney, lung, spinal canal and the leptomeningeal surface in the cranium (7,8). However only four previous reports pointed out the occurrence of interspersed adrenal cortical cells in three SCAs and in one clinically functioning corticotroph adenoma (7,9–11).
Silent corticotroph adenomas are diagnosed incidentally or when they reach a size which leads to clinical symptoms such as headache or compression findings (1). Adrenocortical choristoma in SCA is a very rare entity, and herein, to our knowledge, we describe the fourth and the youngest patient reported until now, who was diagnosed during evaluation of central hypothyroidism.
Case report

uncorrected proof

The patient had been on regular follow-up in our clinic with a diagnosis of compensated hypothyroidism [exaggerated thyroid-stimulating hormone (TSH) response to thyrotropin-releasing hormone (TRH)] and was under L-thyroxine treatment since four months of age. The patient did not have any relevant past medical and familial history except for the presence of double urethral meatus. At 11 years of age, despite L-thyroxine treatment, findings compatible with central hypothyroidism (free thyroxine: 0.78 ng/dL, normal range 0.98-1.63 and TSH: 0.47 mIU/mL, normal range 0.51-4.3) were noticed. On his physical examination, he was in the 90-97th percentile for weight and 90th percentile for height. His blood pressure was normal (90/50 mmHg, 50-75th percentile). All the other pituitary hormones were found to be within normal ranges. Cortisol was found to be low (4.82 ug/dL, normal: >15 ug/dL), and adrenocorticotropic hormone (ACTH) level was 17.3 pg/mL (relatively low). An ACTH deficiency was confirmed with a peak cortisol of 15.27 ug/dL (normal>18 ug/dL) to low dose ACTH stimulation test (12). Thus, cortisol replacement was added to L-thyroxine replacement.
Magnetic resonance imaging (MRI) identified a tumor measuring 11x11x10 mm in the pituitary region with enhancement characteristics suggestive of a pituitary adenoma (also known as pituitary neuroendocrine tumor)(Fig.1). Transsphenoidal resection of the pituitary tumor was performed due to the tumor mass effect which resulted in central hypothyroidism and central adrenal insufficiency. Pathological examination identified a corticotroph adenoma with adrenocortical choristoma. Growth failure was noticed after surgery (Fig.2). Based on growth hormone (GH) stimulation tests, complete GH deficiency was confirmed, and GH therapy was initiated. The patient benefited significantly from the treatment with a height velocity of 8.4 cm/year in the first year, and his pubertal development progressed in accordance with his age.
Six years after the surgery, tumoral recurrence was observed on MRI in the pituitary gland, with a microadenoma of 5 mm in diameter. However, since the tumor did not cause any clinical findings, the patient was followed up with MRI repeated at 6-month intervals.
Beforehand, informed consent was obtained from the parents of the patient for all steps and added to the patient's file.

Pathological Evaluation

Pathological evaluation of the tumor revealed the presence of two groups of cells: small round cells with amphophilic to basophilic cytoplasm and large spherical, oval cells with abundant, granular, partly vacuolated acidophilic cytoplasm. (Fig. 3A,3B)
By immunohistochemistry, small cells were immunopositive for ACTH and synaptophysin. In addition, these cells were diffusely positive for Periodic Acid Schiff (PAS) indicating the presence of corticotroph cells with predominant dense granulation pattern. Larger cells were immunonegative for synaptophysin (Fig. 4A,4B); positive for mitochondrial antigen , inhibin (Fig. 5A,5B), calretinin and Melan A (clone A103). The cells were rich in mitochondria, and did not stain with PAS, compatible with adrenocortical tissue.
The ratio of the two cell types varied considerably from area to area. Major cellular or nuclear pleomorphism was not noted, and no mitotic figures were seen in both components. The Ki67 labeling index was 3-4%. However, the tumor margins could not be determined due to the nature of the specimen excision.

Discussion

Silent corticotroph adenomas comprise 3-19% of nonfunctional pituitary adenomas (1). The most frequently reported presenting features of SCAs are tumor mass effects, including headaches, visual disturbance, and hypopituitarism (13). Central hypothyroidism and central adrenal insufficiency developed during the follow-up of our patient. Growth hormone deficiency emerged after surgery, as an expected complication of pituitary surgeries (14) .
It has been demonstrated that SCAs can be more aggressive than any other clinically nonfunctioning adenomas with a higher prevalence of cavernous sinus invasion and a higher rate of recurrences(5,13). In the other three case reports (7,10,11), data with regard to postoperative follow-up period were lacking, but the tumor in our patient recurred after 6 years.
The SCA in our patient was associated with adrenocortical cells. Coexistence of corticotroph adenoma with adrenocortical choristoma is a very rare entity, and in 1996, Oka et al. (7) were first to report such a tumor in a 16-year-old boy who presented with growth retardation (7). Three of the previously described tumors including the patient reported by Oka et al. (7) were all biochemically silent, but the fourth one showed evidence of function (9). Similar to our case, all reported four tumors were macroadenomas (tumors exceeding 1.0 cm on MRI studies). Three of the four cases were diagnosed in teenage years (16-18 years of age), while only one was adult. Our 11-year-old patient was the youngest of them.
The adult patient mentioned above was a 35-year-old male patient, and he had secondary hypothyroidism, hypogonadotropic hypogonadism and ''low IGF1 with growth hormone''. (11) The other three teen-aged patients had either growth retardation (Basal GH and IGF1 levels were reported to be low) or delayed pubertal development. However, our patient had a diagnosis of central hypothyroidism and ACTH insufficiency, which may be associated with the compression of the tumor that results in selective adenohypophyseal dysfunction. On the other hand, in a silent adenoma, endocrine hypoactivity may be due to the defective production, packaging or release of hormones by pituitary cells. In our case growth retardation developed later in follow-up period, and GH was confirmed. Pubertal development progressed in accordance with age, i.e., he did not have hypogonadotropic hypogonadism.
The origin of adrenocortical cells in corticotroph adenomas and the reason for coexistence with corticotroph cells is not clearly understood. It is suggested that they might be a random mixture of the two types of cells proliferating in the sella (15). As discussed in previously published papers, there might be two explanations for the existence of the two cell types together. The first one is that adrenocortical cells might have differentiated from stem cells, such as undifferentiated mesenchymal cells, under prolonged ACTH stimulation. Studies in humans and in experimental animals support the hypothesis that ACTH stimulation in corticotroph adenomas converts mesenchymal cells to adrenocortical-like cells (16). Groat et al. (16) observed differentiation of the adrenocortical-like cells from ovarian and other mesenchymal tissues in the adrenalectomized ground-squirrels. Likewise, it was also suggested that these two cell types might interact in a paracrine manner due to the close relationship between ACTH and adrenocortical cells. However, conversely, our patient had ACTH deficiency which makes this mechanism unlikely. Mete et al. suggested that steroidogenic factor 1 (SF-1) which is present in both pituitary and adrenal cortex may have an important role in the proliferation and differentiation of uncommitted mesenchymal stem cells

uncorrected proof

within the sella (11). On the other hand, the second explanation is that the adrenocortical cells may have migrated to a wrong place in early embryonic process (7,8,10). In the present case, the latter explanation appears to be more likely.

Conclusion

The lack of biochemical and clinical evidence of Cushing syndrome despite corticotroph tumor indicated the presence of a SCA. In our patient, the presence of the second group of cells, similar to adrenocortical cells in this heterotopic location is compatible with choristoma. The younger age of our patient than those of previously reported cases and clinical significance of SCA, make this case remarkable, and the recurrence of the tumor in the present case after surgery also makes this case report unique. Another point is that endocrinologists should pay attention to unexpectedly suppressed TSH values while evaluating thyroid function tests during the follow-up of the patients with primary hypothyroidism and should be careful in terms of newly developing central hypothyroidism. In such a situtation, other pituitary hormone levels and a pituitary imaging should be taken into account.

REFERENCES

1. Cooper O. Silent corticotroph adenomas. Pituitary [Internet]. 2015 Apr 23;18(2):225–31. Available from: http://link.springer.com/10.1007/s11102-014-0624-3
2. Melmed S. Mechanisms for pituitary tumorigenesis: the plastic pituitary. Journal of Clinical Investigation [Internet]. 2003 Dec 1;112(11):1603–18. Available from: http://www.jci.org/articles/view/20401
3. Asa SL, Mete O. Immunohistochemical Biomarkers in Pituitary Pathology. Endocrine pathology [Internet]. 2018 Jun;29(2):130–6. Available from: http://www.ncbi.nlm.nih.gov/pubmed/29453601
4. Mete O, Asa SL. Structure, Function, and Morphology in the Classification of Pituitary Neuroendocrine Tumors: the Importance of Routine Analysis of Pituitary Transcription Factors. Endocrine Pathology [Internet]. 2020 Aug 19; Available from: http://link.springer.com/10.1007/s12022-020-09646-x
5. Alahmadi H, Lee D, Wilson JR, Hayhurst C, Mete O, Gentili F, et al. Clinical features of silent corticotroph adenomas. Acta Neurochirurgica [Internet]. 2012 Aug 24;154(8):1493–8. Available from: http://link.springer.com/10.1007/s00701-012-1378-1
6. Drummond J, Roncaroli F, Grossman AB, Korbonits M. Clinical and Pathological Aspects of Silent Pituitary Adenomas. The Journal of clinical endocrinology and metabolism [Internet]. 2019 Jul 1;104(7):2473–89. Available from: https://academic.oup.com/jcem/article/104/7/2473/5055109
7. Oka H, Kameya T, Sasano H, Aiba M, Kovacs K, Horvath E, et al. Pituitary choristoma composed of corticotrophs and adrenocortical cells in the sella turcica. Virchows Archiv [Internet]. 1996 Mar;427(6). Available from: http://link.springer.com/10.1007/BF00202893
8. Wiener MF, Daalgaard SA. Intracranial adrenal gland; a case report. AMA archives of pathology [Internet]. 1959 Feb;67(2):228–33. Available from: http://www.ncbi.nlm.nih.gov/pubmed/13616833
9. Albuquerque FC, Weiss MH, Kovacs K, Horvath E, Sasano H, Hinton DR. A Functioning Composite "Corticotroph" Pituitary Adenoma with Interspersed Adrenocortical Cells. Pituitary. 1999;1((3-4)):279–84.
10. Claire IC, Eva H, Kalman K, Harley SS, Hironobu S, Kazumi L, et al. Composite Silent Corticotroph Pituitary Adenoma with Interspersed Adrenocortical Cells: Case Report. Neurosurgery [Internet]. 1998 Mar 1;42(3):650–4. Available from: https://academic.oup.com/neurosurgery/article/42/3/650/2843516
11. Mete O, Ng T, Christie-David D, McMaster J, Asa SL. Silent Corticotroph Adenoma with Adrenal Cortical Choristoma: a Rare but Distinct Morphological Entity. Endocrine Pathology [Internet]. 2013 Sep 20;24(3):162–6. Available from: http://link.springer.com/10.1007/s12022-013-9256-9
12. El-Farhan N, Pickett A, Ducroq D, Bailey C, Mitchem K, Morgan N, et al. Method-specific serum cortisol responses to the adrenocorticotrophin test: comparison of gas chromatography-mass spectrometry and five automated immunoassays. Clinical endocrinology [Internet]. 2013 May;78(5):673–80. Available from: http://www.ncbi.nlm.nih.gov/pubmed/22994849
13. Scheithauer BW, Jaap AJ, Horvath E, Kovacs K, Lloyd R V., Meyer FB, et al. Clinically Silent Corticotroph Tumors of the Pituitary Gland. Neurosurgery [Internet]. 2000 Sep;47(3):723–30. Available from: http://content.wkhealth.com/linkback/openurl?sid=WKPTLP:landingpage&an=00006123-200009000-00039
14. Kobayashi N, Yamaguchi-Okada M, Horiguchi K, Fukuhara N, Nishioka H, Yamada S. Postoperative growth hormone dynamics in clinically nonfunctioning pituitary adenoma. Endocrine Journal [Internet]. 2018;65(8):827–32. Available from: https://www.jstage.jst.go.jp/article/endocrj/65/8/65_EJ17-0536/_article
15. Larkin S, Ansorge O. Development And Microscopic Anatomy Of The Pituitary Gland [Internet]. Endotext. 2000. Available from: http://www.ncbi.nlm.nih.gov/pubmed/28402619
16. Groat RA. Formation and growth of adrenocortical-like tissue in the ovaries of the adrenalectomized ground squirrel. The Anatomical Record [Internet]. 1944 May;89(1):33–41. Available from: http://doi.wiley.com/10.1002/ar.1090890104

uncorrected proof

FIGURE LETTERS

Fig.1:Magnetic resonance imaging (MRI) of the pituitary gland at eleven years of age the 1-cm adenoma is marked with an arrow.

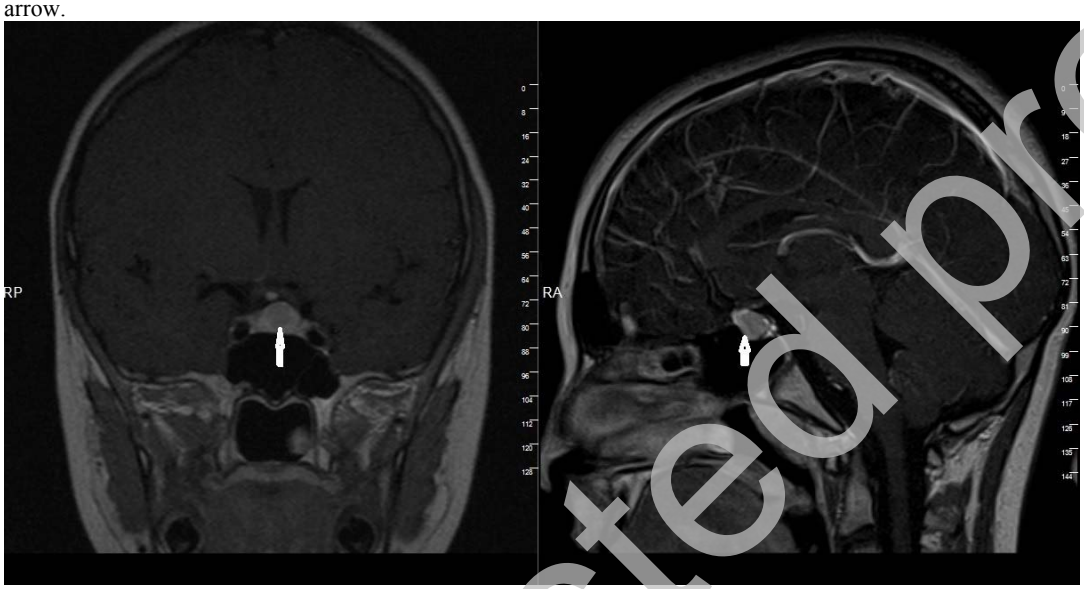

Fig. 2: Percentile curve of the case. A:Pituitary surgery B:Initiation of the growth hormone therapy MP: Midparental height

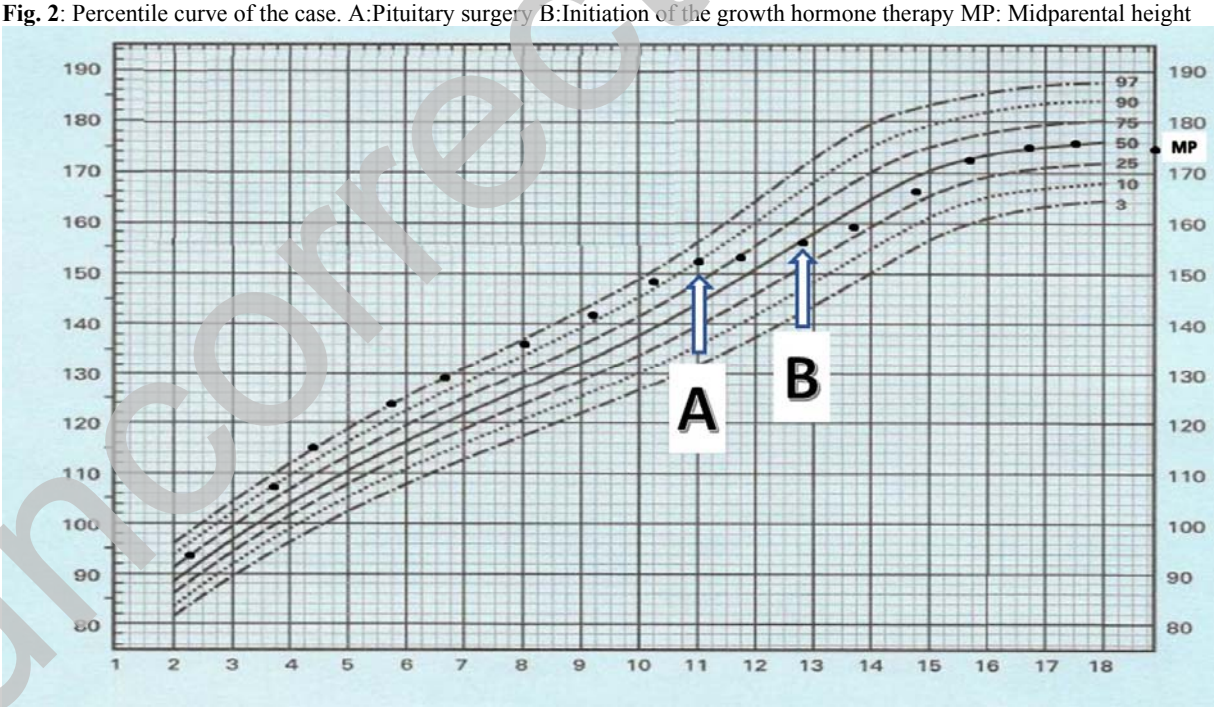

Fig. 3A,3B: Mixture of the small round well-granulated cells with amphophilic or basophilic cytoplasm (Corticotroph cells) and the large spherical or oval cells with abundant, granular, partly vacuolated cytoplasm(Adrenocortical cells) form groups (H&EX100-400)

uncorrected proof

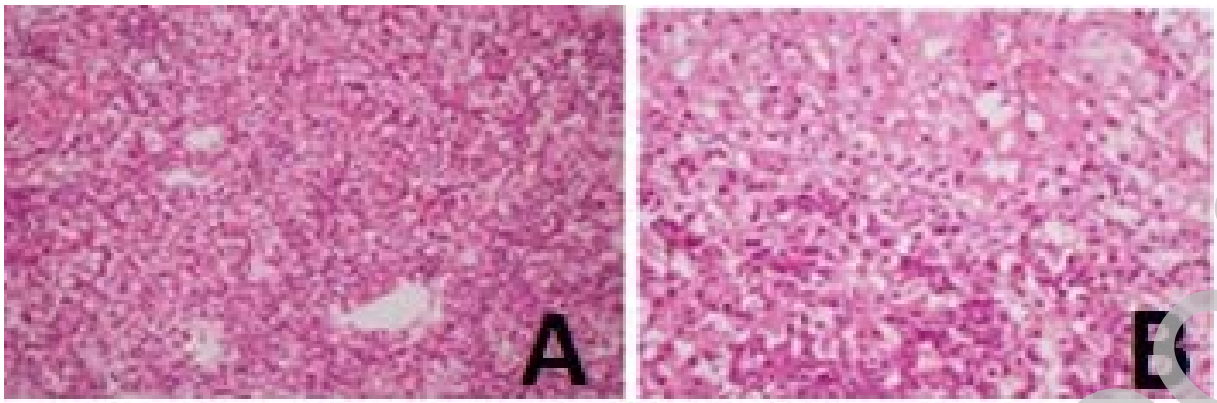

Fig.4A: Small cells immunopositive for ACTH (ACTHX400)

Fig.4B: Adrenocortical cells are immunonegative and corticotroph cells immunpossitive for Synaptophysin (SynaptophysinX400)



Fig.5A: Large vacuolated cytoplasm adrenocortical cells are densely immunpositive for mitochondrial antigen (Mitochondrial agX100)

Fig.5B: Adrenocortical cells are immunpositive for inhibin (inhiibinx400)

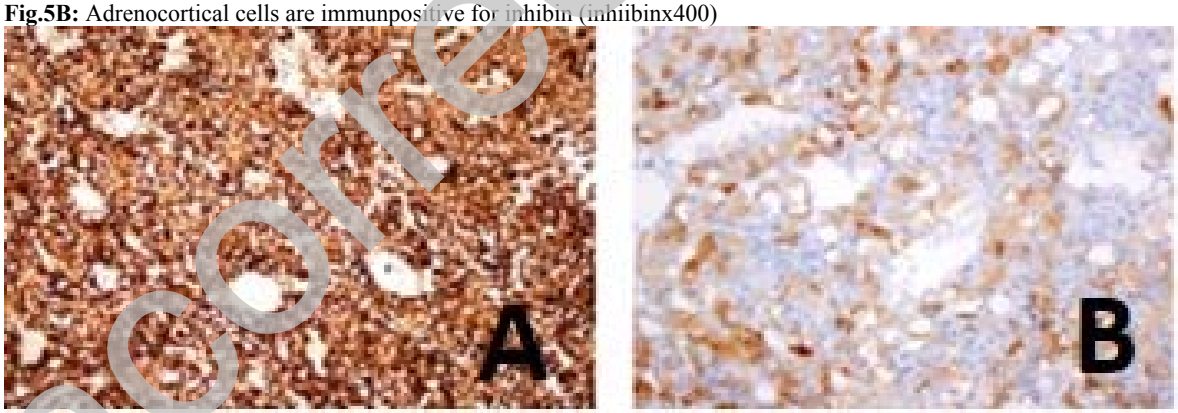

uncorrected proof