

Computed Tomographic Assessment of Osteotomy with Respect to Open Roof in Patients Undergoing Primary Septorhinoplasty with Bilateral Osteotomy

Bilateral Osteotomi Yapılan Primer Septorinoplasti Olgularının Osteotomilerinin Open Roof Açısından Bilgisayarlı Tomografi ile Değerlendirilmesi

© Ozan Özdemir¹, © Zerrin Boyacı²

¹ University of Health Sciences Turkey, İstanbul Training and Research Hospital, Clinic of Otolaryngology, İstanbul, Turkey

² Acıbadem Kozyatağı Hospital, Clinic of Otolaryngology, İstanbul, Turkey

ABSTRACT

Introduction: The objective of rhinoplasty is to provide predictable changes in the nasal contours and improve nasal functions. Nasal osteotomy is a frequently used correction technique in rhinoplasty. However, the optimal osteotomy technique and approach remain a matter of dispute.

Methods: In this study, 24 patients who underwent primary septorhinoplasty and 24 patients who underwent paranasal sinus computed tomography (CT) due to various causes were retrospectively assessed. Operated patients completing a minimum postoperative follow-up duration of 1 year were invited to the study center. Informed consent form was signed, and a CT of the nasal bone in the axial plane was performed. These recorded values were compared with their preoperative results and with non-surgical patients.

Results: Comparison of data between postoperative and non-surgical cases showed that there was a significant reduction in the ventral width of operated patients ($p=0.022$), whereas no significant difference was observed in the dorsal width despite bilateral spreader grafts ($p=0.108$).

Conclusion: Our results suggest that the dorsal width in patients undergoing bilateral osteotomy and bilateral spreader grafts was not significantly different from those in non-operated subjects. Also, contrary to what one may expect, spreader grafts are not associated with an increased dorsal width.

Keywords: Open roof, spreader graft, septorhinoplasty, rhinoplasty

ÖZ

Amaç: Rinoplastinin amacı, burun hatlarında öngörülebilir değişiklikleri sağlamak ve burun fonksiyonlarını iyileştirmektir. Nazal kemik osteotomisi, rinoplastide sıklıkla kullanılan bir tekniktir. Bununla birlikte, optimal osteotomi tekniği ve yaklaşımı bir tartışma konusu olmaya devam etmektedir.

Yöntemler: Bu çalışmada, primer septorinoplasti yapılan yirmi dört hasta ve çeşitli nedenlerle paranasal sinüs tomografisi çekilen diğer 24 hasta grubu retrospektif olarak değerlendirildi. En az bir yıllık postoperatif takip süresini tamamlayan opere edilen hastalar çalışma merkezine davet edildi, bilgilendirilmiş onam formu imzalatıldı ve aksiyal planda burun kemiği tomografisi çekildi. Kaydedilen bu değerler ameliyat öncesi sonuçları ve ameliyatsız hastalar ile karşılaştırıldı.

Bulgular: Ameliyat sonrası ve ameliyatsız olgular arasındaki verilerin karşılaştırılması, ameliyat edilen hastalarda ventral genişlikte anlamlı bir azalma olurken ($p=0,022$) dorsal genişlikte bilateral spreader greftlere rağmen anlamlı bir farklılık görülmedi ($p=0,108$).

Sonuç: Sonuçlarımız, bilateral osteotomi ve bilateral spreader greft uygulanan hastalarda dorsal genişliğin ameliyat edilmeyen hastalardan önemli ölçüde farklı olmadığını düşündürmektedir ve beklenenin aksine, spreader greftler artmış dorsal genişlik ile ilişkili değildir.

Anahtar Kelimeler: Open roof, spreader greft, septorinoplasti, rinoplasti

Introduction

The nose and its associated structures represent a common anatomical site subjected to physical trauma. Consequently, surgical correction procedures involving this site are performed very frequently. Among these, rhinoplasty is a common procedure performed by ear-nose-throat

specialists (1). The objective of rhinoplasty is to provide predictable changes in nasal contours and improve nasal functions (2). Nasal surgery is classified into two major categories as follows: "Aesthetic rhinoplasty," which alters the appearance, and "functional rhinoplasty," which improves functions. Nasal osteotomy is a frequently used correction



Address for Correspondence/Yazışma Adresi: Ozan Özdemir MD, University of Health Sciences Turkey, İstanbul Training and Research Hospital, Clinic of Otolaryngology, İstanbul, Turkey
Phone: +90 212 459 60 00 E-mail: opdrozanzozdemir@gmail.com ORCID ID: orcid.org/0000-0001-6534-1672

Cite this article as/Atıf: Özdemir O, Boyacı Z. Computed Tomographic Assessment of Osteotomy with Respect to Open Roof in Patients Undergoing Primary Septorhinoplasty with Bilateral Osteotomy. İstanbul Med J 2021; 22(2): 84-7.

©Copyright 2021 by the University of Health Sciences Turkey, İstanbul Training and Research Hospital/İstanbul Medical Journal published by Galenos Publishing House.

©Telif Hakkı 2021 Sağlık Bilimleri Üniversitesi İstanbul Eğitim ve Araştırma Hastanesi/İstanbul Tıp Dergisi, Galenos Yayınevi tarafından basılmıştır.

Received/Geliş Tarihi: 26.10.2020
Accepted/Kabul Tarihi: 02.02.2021

technique in rhinoplasty that is individualized according to the needs of specific patients. However, the optimal osteotomy technique and approach remain a matter of dispute. There has been a growing interest, particularly among the aesthetic surgeon community, toward the use of assistive imaging modalities such as computed tomography (CT) in planning and predicting the potential outcomes of such surgery (3).

Methods

The study was approved by the Ethics Committee of Kartal Lütfi Kırdar Training and Research Hospital (approval number: 8951337/1009/146).

A group of 24 patients who underwent primary septorhinoplasty due to breathing difficulties and nasal deformities and another 24 patients who underwent paranasal CT due to various causes between 2008 and 2013 at the Maltepe University Faculty of Medicine, Departments of Ear Nose and Throat Surgery and Head and Neck Surgery, were retrospectively assessed. All patients were operated by the same surgeon using the same surgical equipment and closed septorhinoplasty technique, with spreader grafts. Spreader grafts retrieved from the septal cartilage were placed in the submucoperichondrial area located between the upper laterals and septum and were then sutured to the septum and medial edges of the upper laterals, leading to the expansion of the internal nasal valve and provision of long-term support for the septum.

After the hump reduction, lateral osteotomies were performed using the internal continuous method in accordance with low-to-low technique and were merged with percutaneous transverse osteotomies. The nasal bones separated from the lateral side were approached to narrow the nasal dorsum and close the open roof. Excessive spreader graft parts were excised using a scalpel after the procedure.

Antibiotic-soaked intranasal packing was removed on postoperative day 3. The cast placed to provide stability to the nasal dorsum was removed on days 8 to 10, and steri-strips™ (Istanbul-Turkey) that were applied following the physical examination were removed on day 14. Follow-up visits were scheduled at increasing time intervals postoperatively.

Patients completing a minimum postoperative follow-up duration of 1 year were invited to the study center and went through a physical examination; the measurement of the dorsal width by palpation was recorded. After obtaining photographic records, informed consent form was signed, and a CT of the nasal bone in the axial plane was performed. When required, endoscopic imaging was also performed to assess the nasal passages. The ventral width crossing the lateral osteotomy lines and the dorsal width measured at the tip of the dorsum were recorded in millimeters (Figure 1). The recorded values were compared with those in non-surgical patients who had undergone a paranasal CT for various indications. In addition, the correlation between the dorsal width measurements and palpation findings was analyzed.

Statistical analysis

Statistical analysis was performed using SPSS 16.0 software. The distribution of variables was measured using the Kolmogorov-Smirnov

test. Mann-Whitney U and chi-square tests were used to analyze quantitative and qualitative independent data, respectively. Fisher's test was used when chi-square test conditions were not met. A two-tailed $p < 0.05$ was considered statistically significant.

Results

A total of 24 patients undergoing surgery (20 women and 4 men; age range: 19-51 years, mean age: 28.4 years) and 24 non-operated individuals (14 women and 10 men; age range: 17-88 years, mean age: 38.75 years) were examined (Table 1).

Closed septorhinoplasty was conducted in all patients who underwent primary surgical procedure, with placement of bilateral spreader grafts and low-to-low lateral osteotomy + percutaneous transverse osteotomy in all cases. No serious intraoperative or postoperative complications occurred. At the postoperative 1-year follow-up examination, photographic images of the patients were obtained, and the width of the nasal dorsum was graded according to open roof deformity. Of patients, 18 and 6 were negative and positive by palpation, respectively. In addition, a photographic examination corroborated the findings in two cases. The axial CT of the nasal bone performed at a mean of 30.4 months postoperatively was used to obtain the dorsal and ventral width measurements. The corresponding values in the 24 control patients enrolled in the study were also recorded and compared. The results are shown in Table 2 and 3 as mean and standard deviation, where a p-value of less than 0.05 was considered significant. A comparison of the data between postoperated and non-operated cases showed no significant difference in the dorsal width ($p=0.108$), but there was a significant reduction in the ventral width in operated patients ($p=0.022$; Table 2). In a within-group comparison among those who underwent primary septorhinoplasty, a significantly higher dorsal width was found in those with positive palpation than those with negative palpation ($p=0.045$). However, similar results were found between these two groups in terms of ventral width ($p=0.499$; Table 3).

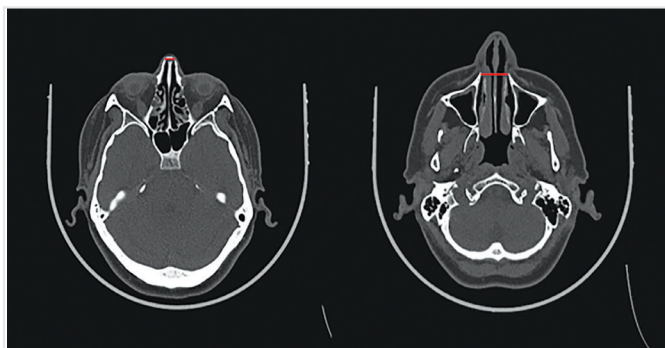


Figure 1. The short red line shows the dorsal width and long red line the ventral width

Table 1. Distribution of patients

Distribution of patients	Operated patients (50%)	Non-operated patients (50%)
Male	4 (8%)	10 (21%)
Female	20 (42%)	14 (29%)

Table 2. Dorsal and ventral widths in postoperated and non-operated patient groups

Measured value	Postoperated group median (IQR)	Non-operated group median (IQR)	p
Dorsal width (mm)	100±12	94±9	0.108
Ventral width (mm)	216±14	227±17	0.022

P<0.05 is considered significant, IQR: interquartile range

Table 3. Dorsal and ventral widths at postoperative 1-year in patients with palpable and non-palpable nasal dorsum

Measured value	Palpation (+) group median (IQR)	Palpation (-) group median (IQR)	p
Dorsal width (mm)	105±12	95±10	0.045
Ventral width (mm)	218±15	214±13	0.499

P<0.05 is considered significant, IQR: interquartile range

Discussion

Open roof deformity may arise from thickened or deviated dorsal septum and thickened bone in the radix or from greenstick fractures in non-mobilized nasal bones. Its surgical management involves correcting the septal deformity, displacing the medial triangular structure of the bone in the radix, and redoing the lateral osteotomy (4). Daniel described a symptomatic deformity due to the contact between the mucous membrane and open roof (5). However, this was not observed in the current study.

Similar to this study, Camirand et al. (6) reported that lateral osteotomy was very rarely associated with airway problems. The authors claimed that spreader grafts could correct the airway problems of patients who experienced such issues (6). However, lateral nasal osteotomy led to a significant narrowing of the nasal passage (7). In our study, despite low-to-low osteotomy, closed septorhinoplasty could prevent the collapse of the medial wall and preserve the structural integrity of the nasal valve, along with the placement of spreader grafts obviating the dorsal height loss and irregularity.

In the study by Egeli et al. (8) where nasal passage measurements were performed using CT, it was concluded that a reduction of the contralateral concha hypertrophy was necessary in subjects with septal deviation. In our study, the intervention involved the application of radiofrequency and lateralization of the lower concha hypertrophy.

Interventions involving the internal valve, that is, spreader grafts, have been recommended by authors such as Sheen (9) and Rohrich et al. (10) to relieve the airways. In our study, adequate airway passage was accomplished through septoplasty and nasal valve interventions.

In another study, Kortbus et al. (11) failed to observe a significant reduction in the dorsal width following osteotomy ($p=0.24$) while there was a statistically significant decrease in the ventral width postoperatively ($p=0.003$). Our osteotomy results were similar to Kortbus et al. (11) study; a significant ventral narrowing occurred in the osteotomy group ($p=0.022$), suggesting that osteotomy is not associated with a significant reduction in the nasal dorsal width when performed in conjunction with spreader graft while it was able to significantly reduce the ventral width.

Several previous studies have reported that the resolution of edema following rhinoplasty is a slow process requiring many months and that

long-term assessment should be delayed until 1 to 2 years after surgery. In this regard, adequate time has been allowed for the postoperative evaluations in our study (mean: 30.4 months).

Gunter et al. (12) examined the analysis and classification of grafts and found that onlay grafts of the nasal dorsum could correct dorsal irregularity, provide dorsal augmentation, and obviate the “step off” deformity that may occur following osteotomy. For this purpose, we utilized various techniques such as the correction of such irregularities and augmentation and correction of dorsal asymmetry by spreader grafts.

Bottini et al. (13) concluded that composite grafts were more effective for opening the valves compared with spreader grafts, which were the preferred approach over composite grafts for the expansion of the nasal valve in our study.

Although nasal endoscopy is used for different purposes by rhinologists, in Lanfranchi et al.'s (14) study involving 96 patients, further interventions were required in 28 patients (30%) because of the use of preoperative endoscopy for several concomitant pathologies during surgery (e.g., Concha bullosa and choanal stenosis). Our patients also underwent endoscopic examination preoperatively and postoperatively and had the required interventions perioperatively (concha bullosoplasty).

Sam examined the effect of functional rhinoplasty on postoperative respiratory functions and determined that there were no statistically significant differences between the nasal obstruction symptom evaluation, a commonly utilized scale, and linear symptom scale, a subjective patient assessment tool ($p<0.01$) (15). In our patients, septoplasty, valve-relieving interventions, or spreader grafting were performed depending on the type of individual respiratory functional requirement. Linear symptom scale assessment was not performed in all patients, considering the reported similarity between these scales.

Study Limitations

Our study has several limitations. The most prominent limitation was the small study population. As a retrospective analysis, we are limited by what is documented in the electronic medical records. On the other hand, radiological evaluations are dependent on gender and age. Therefore, the number of women (14) and men (10) was similar to the control group patients. Also, the proportion of men (8%) included in the

study group did not make a significant difference. Future studies should include a larger number of patients.

Conclusion

Closed septorhinoplasty with good preoperative planning represents a viable alternative to classical rhinoplasty to correct septal, conchal, and nasal valve pathologies and to attain good cosmetic results. We believe that this approach may gain a more widespread popularity among surgeons with increasing numbers of patients undergoing such surgery, due to several advantages such as the efficacy in terms of respiratory functional outcomes, practicability, low postoperative complication risk, secondary surgery facilitation, and low propensity to damage the normal anatomy. Our results suggest that the dorsal width in patients undergoing bilateral osteotomy and bilateral spreader grafts was not significantly different from those in non-operated subjects. Furthermore, contrary to what one may expect, spreader grafts may not be associated with an increased dorsal width. However, this approach may lead to the occurrence of minimal increase in the width of the nasal dorsum that can be detected on palpation, although the difference in non-operated patients was not significant.

Ethics Committee Approval: The study was approved by the Ethics Committee of Kartal Lütfi Kırdar Training and Research Hospital (approval number: 8951337/1009/146).

Informed Consent: Informed consent form was signed.

Peer-review: Externally and internally peer-reviewed.

Authorship Contributions: Surgical and Medical Practices - Z.B.; Concept - Z.B.; Design - O.Ö.; Data Collection or Processing - O.Ö.; Analysis or Interpretation - Z.B.; Literature Search - O.Ö.; Writing - O.Ö.

Conflict of Interest: No conflict of interest was declared by the authors.

Financial Disclosure: The authors declared that this study received no financial support.

References

1. Rohrich RJ, Adams WP Jr. Nasal fracture management: minimizing secondary nasal deformities. *Plast Reconstr Surg* 2000; 106: 266-73.
2. Kim DW, Toriumi DM. *Essentials of septorhinoplasty*. 1st ed. Stuttgart: Thieme; 2004.
3. Mühlbauer W, Holm C. Computer imaging and surgical reality in aesthetic rhinoplasty. *Plast Reconstr Surg* 2005; 115: 2098-104.
4. Ghali GE, Lustig JH. Complications associated with facial cosmetic surgery. *Oral Maxillofacial Surg Clin N Am* 2003; 15: 265-83.
5. Daniel RK. Rhinoplasty: septal saddle nose deformity and composite reconstruction. *Plast Reconstr Surg* 2007; 119: 1029-43.
6. Camirand A, Douced J, Haris J. Nose surgery: how to prevent a middle vault collapse-a review of 50 patients 3 to 21 years after surgery. *Plast Reconstr Surg* 2004; 114: 527-34.
7. Guyuron B. Nasal osteotomy and airway changes. *Plast Reconstr Surg* 1998; 102: 856-60.
8. Egeli E, Demirci L, Yazıcı B, Harputoğlu U. Evaluation of the inferior turbinate in patients with deviated nasal septum by using computed tomography. *Laryngoscope* 2004; 114: 113-7.
9. Sheen JH. Spreader graft revisited. *Perspect. Plast Surg* 1989; 3: 155-63.
10. Rohrich RJ, Krueger JK, Adams WP Jr, Hollier LH Jr. Achieving consistency in the lateral nasal osteotomy during rhinoplasty: an external perforated technique. *Plast Reconstr Surg* 2001; 108: 2122-30.
11. Kortbus MJ, Ham J, Fechner F, Constantinides M. Quantitative analysis of lateral osteotomies in rhinoplasty. *Arch Facial Plast Surg* 2006; 8: 369-73.
12. Gunter J, Landecker A, Cochran CS. Frequently used grafts in rhinoplasty: nomenclature and analysis. *Plast Reconstr Surg* 2006; 118: 14e-29e.
13. Bottini DJ, Gentile P, Arpino A, Dasero G, Cervelli V. Reconstruction of the nasal valve. *Craniofac Surg* 2007; 18: 516-9.
14. Lanfranchi PV, Steiger J, Sparano A, Brigandi L, Lin G, Becker SS, Becker DG. Diagnostic and surgical endoscopy in functional septorhinoplasty. *Facial Plast Surg* 2004; 20: 207-15.
15. Most SP. Analysis of outcomes after functional rhinoplasty using a disease-specific quality-of-life instrument. *Arch Facial Plast Surg* 2006; 8: 306-9.