



# Cytarabine-Induced Corneal Toxicity: Clinical Features and Relief of Symptoms with Loteprednol Etabonate 0.5% in Two Patients

© Gökçen Özcan\*, © Ömür Özlenen Uçakhan\*\*

\*Ahi Evran University Training and Research Hospital, Clinic of Ophthalmology, Kırşehir, Turkey

\*\*Ankara University Faculty of Medicine, Department of Ophthalmology, Ankara, Turkey

## Abstract

We report two patients who developed toxic keratopathy following high-dose cytarabine chemotherapy and whose symptoms resolved following topical loteprednol etabonate 0.5% treatment. A 25-year-old woman and a 26-year-old man with acute myeloid leukemia were referred to our department with symptoms of ocular discomfort, photophobia, and blurred vision after consolidation chemotherapy. Central corneal epithelial microcysts were observed bilaterally in both patients, and *in vivo* confocal microscopy showed highly reflective disseminated granular and irregular intraepithelial opacities, mainly in the basal epithelial layers. Loteprednol etabonate 0.5% relieved both patients' symptoms in less than a week, and the microcysts disappeared in 2 to 3 weeks of treatment. Although there is no standardized treatment protocol for cytarabine-induced corneal toxicity, dexamethasone 0.1% and prednisolone phosphate 1.0% were reported to be effective in the resolution of discomfort and symptoms. In the two patients we report herein, loteprednol etabonate 0.5% four times daily was also effective in suppressing the symptoms.

**Keywords:** Acute myeloid leukemia, cytarabine, cytarabine-induced corneal toxicity, corneal microcysts, loteprednol etabonate, *in vivo* confocal microscopy

## Introduction

Cytarabine is an anti-metabolite used mainly in the treatment of acute non-lymphoblastic leukemia. Corneal toxicity related to cytarabine treatment is dependent on the concentration and duration of treatment and is encountered in patients receiving high-dose intravenous treatment, particularly for consolidation therapy in acute myeloid leukemia (AML).<sup>1,2</sup> Following intravenous infusion, the drug penetrates the blood-brain barrier and reaches the cornea via both the aqueous and tears.<sup>1</sup> Cytarabine-induced corneal toxicity is characterized by corneal epithelial microcyst formation. The corneal toxic keratopathy is reversible without permanent damage or scarring, and vision usually returns to baseline. The resolution of symptoms is within 10 to 14 days and follows the desquamation of the affected cell

line. Although uncommon, cytarabine-induced corneal toxicity has also been reported with low-dose treatment regimens.<sup>3</sup> While there is no standard treatment protocol for cytarabine-induced corneal toxicity, dexamethasone and prednisolone drops have been reported effective in treatment.<sup>1,4,5</sup> In this report we want to emphasize that loteprednol etabonate, a topical soft steroid, is also as effective as dexamethasone and prednisolone in the treatment of cytarabine-induced corneal toxicity.

## Case Reports

### Case 1

A 25-year-old woman with a diagnosis of acute myelomonocytic leukemia (AML-M4) presented with a 2-day history of foreign body sensation and photophobia following

**Address for Correspondence:** Gökçen Özcan, Ahi Evran University Training and Research Hospital, Clinic of Ophthalmology, Kırşehir, Turkey

E-mail: drgokcencondu@gmail.com **ORCID-ID:** orcid.org/0000-0002-2616-5941

**Received:** 16.07.2020 **Accepted:** 05.12.2020

**Cite this article as:** Özcan G, Özlenen Uçakhan Ö. Cytarabine-Induced Corneal Toxicity: Clinical Features and Relief of Symptoms with Loteprednol Etabonate 0.5% in Two Patients. Turk J Ophthalmol 2021;51:114-117

©Copyright 2021 by Turkish Ophthalmological Association  
Turkish Journal of Ophthalmology, published by Galenos Publishing House.

the last dose of consolidation chemotherapy with cytarabine. She had 3 doses of 6 g/m<sup>2</sup>/day cytarabine treatment at 2-day intervals and did not use topical corticosteroid prophylaxis. She complained of ocular discomfort, photophobia, and best-corrected visual acuity was 20/20 in both eyes. Slit-lamp biomicroscopy examination revealed bilateral grade 3 staining in the inferior conjunctiva and corneal epithelial microcysts distributed more densely in the central cornea (Figures 1A and 1E). *In vivo* confocal microscopy (IVCM) showed highly reflective, disseminated granular and irregular intraepithelial opacities 8 to 20 μm in diameter, mainly in the epithelial basal cell layers (Figures 1B and 1F). The epithelial wing cell layers had less numerous intraepithelial opacities compared to the epithelial basal cell layers (Figures 1C and 1G). Loteprednol etabonate 0.5% 4 times daily and artificial preservative-free eye drops were prescribed. Four days after treatment, the patient's complaints wholly subsided. After 3 weeks of treatment, microcysts disappeared completely, and IVCM revealed a few hyperreflective elements mainly in the more superficial rather than the basal epithelial layers (Figures 1D and 1H). The loteprednol eye drop was subsequently tapered and stopped in the following weeks.


#### Case 2

A 26-year-old man with acute monocytic leukemia (AML-M5) presented with a 4-day history of blurred vision and ocular discomfort following the last dose of consolidation chemotherapy with cytarabine. He received 6 g/m<sup>2</sup>/day cytarabine treatment 3 times at 2-day intervals. Although he was advised to use prophylactic topical prednisolone phosphate 1% eye drops

starting the day before initiation of chemotherapy, he failed to do so regularly. Best-corrected visual acuities were 20/25 and 20/20 in the right and left eyes respectively. On slit-lamp biomicroscopy examination, bilateral corneal epithelial microcysts were noted (Figures 2A and 2D). There was no staining on the corneal or conjunctival surface. IVCM showed highly reflective disseminated granular irregular intraepithelial opacities 9 to 18 μm in size, again particularly in the epithelial basal cell layers (Figures 2B and 2E) rather than the epithelial wing cell layers (Figures 2C and 2F). The patient's complaints subsided in 5 days, and the microcysts disappeared in 2 weeks with loteprednol etabonate 0.5% 4 times daily and non-preserved artificial tear drops. The loteprednol eye drop was subsequently tapered and stopped in the following weeks.

#### Discussion

Cytarabine-based consolidation chemotherapy was proven mandatory in preventing relapses after achieving complete remission in AML patients.<sup>6</sup> A high-dose (3 doses of 6g/m<sup>2</sup> daily) cytarabine regimen was reported to be superior to low-dose cytarabine regimens (5 doses of 0.4g/m<sup>2</sup> or 0.1g/m<sup>2</sup>) for consolidation.<sup>7</sup> Ocular symptoms develop within 1 week after the initiation of cytarabine treatment and can be prevented with the use of topical corticosteroids. Patients usually complain of tearing, photophobia, foreign body sensation, and sometimes reduced visual acuity. At slit-lamp biomicroscopy, conjunctival hyperemia, superficial punctate keratopathy, and corneal epithelial microcysts with or without conjunctival punctate staining can be noted.



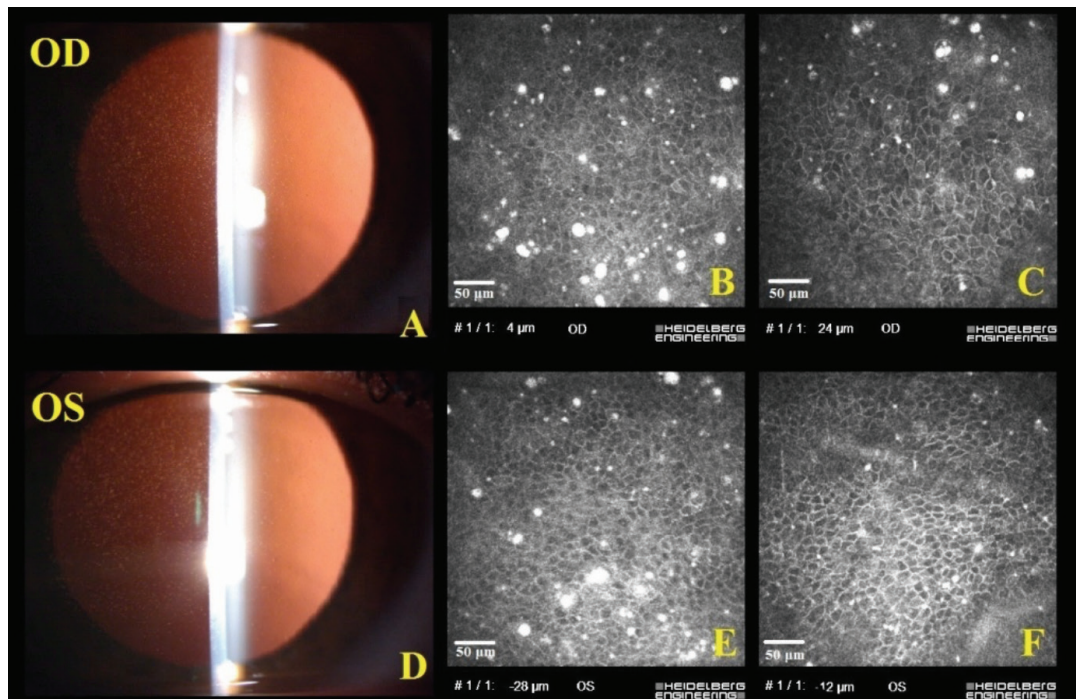
**Figure 1.** Patient 1, right eye (top row) and left eye (bottom row): Slit-lamp biomicroscopy and in-vivo confocal microscopy (IVCM) findings before and after loteprednol etabonate 0.5% treatment. Before treatment, corneal epithelial microcysts were visible on slit-lamp biomicroscopy (A, E) and IVCM revealed hyperreflective opacities that were mainly in the basal epithelial cell layers (B, F) and less numerous in the epithelial wing cell layers (C, G). Two weeks after initiation of treatment, the basal epithelial cell layer was observed to be almost clear of hyperreflective opacities (D, H)

The exact mechanism of corneal microcyst formation is unknown. Since cytarabine inhibits DNA polymerase during the S-phase of cell division, daughter transient amplifying cells that migrate centripetally to populate the basal layer of the corneal epithelium are expected to be more vulnerable to cytarabine toxicity. Since the peripheral epithelial stem cells have a longer cell cycle time compared to the central basal cells, they may not be equally sensitive to the toxic effect of cytarabine; thus, the peripheral cornea typically remains clear, and there remains a clear corneal zone free from microcysts at the corneal periphery.<sup>1</sup> Basal cells are displaced to more superficial layers of the cornea and are desquamated with dynamic turnover and sustained proliferation, hence the resolution of symptoms occurs. In the first few symptomatic days, IVCM shows hyperreflective opacities 8 to 20  $\mu\text{m}$  in size in the basal cell layer. In the following 4 to 9 days, these hyperreflective opacities move to the superficial layers, also affecting the wing-cells and the apical cells. Guthoff et al.<sup>8</sup> also showed intraepithelial highly reflective elements were visualized only in the basal layer in IVCM on first symptomatic day, but at days 9 to 14 they mainly presented in more superficial layers. Histologically, these opacities were shown to represent degenerate cells with pyknotic nuclei intermixed with cytoplasmic debris.<sup>9</sup>

The incidence of cytarabine-induced corneal toxicity was reported to be around 85-92% without topical corticosteroid prophylaxis.<sup>10</sup> In this case, topical steroids are started 1 day before initiation of treatment and are continued throughout the therapy. Topical corticosteroid eye drops have been reported to reduce the incidence to 8-16%.<sup>2,10</sup> Although the mechanism of

action is unknown, corticosteroid eye drops were hypothesized to render the corneal epithelial cells less susceptible to the effects of cytarabine by inducing a partial reduction in DNA replication.<sup>2</sup> In a randomized, double-masked trial that compared placebo to prophylactic steroid use, corticosteroids prevented the development of conjunctival hyperemia and visual reduction, and significantly reduced the degree of microcyst formation.<sup>2</sup> Additionally, prophylactic topical corticosteroid use certainly relieves the symptoms of cytarabine-induced corneal toxicity, such as tearing, photophobia, and foreign body sensation. Betamethasone sodium phosphate 0.1%, dexamethasone 0.1%, and prednisolone phosphate 1% eye drops have been recommended for prophylaxis against cytarabine-induced corneal toxicity.<sup>1,2</sup> In our two patients, loteprednol etabonate 0.5% eye drops were also quite effective in suppressing the patients' symptoms and relieving photophobia. Since these patients are already immunosuppressed, loteprednol etabonate 0.5% use may reduce the risk of secondary infection at the ocular surface, as well as minimizing the risk of short-term topical corticosteroid-induced side effects such as intraocular pressure elevation.

The use of topical 2-deoxycytidine, a competitive inhibitor of cytarabine, has also been shown to be effective in the management of the dose-related corneal toxicity of systemic cytarabine. However, this drug is not commercially available.<sup>11</sup> Artificial tear drops, on the other hand, can help relieve symptoms by diluting cytarabine in tears; therefore, the addition of topical lubricants to topical corticosteroid prophylaxis is usually recommended.<sup>4</sup>



**Figure 2.** Patient 2, right eye (top row) and left eye (bottom row): Before initiation of loteprednol etabonate 0.5% treatment, slit-lamp biomicroscopy with retroillumination revealed numerous central corneal epithelial microcysts bilaterally (A, D). *In vivo* confocal microscopy (IVCM) revealed irregular hyperreflective opacities mainly in the basal epithelial cell layer (B, E) rather than in the epithelial wing cell layer (C, F). Post-treatment IVCM measurements could not be obtained from this patient



Acute anterior uveitis and optic neuropathy are the other rare complications of high dose cytarabine treatment.<sup>12</sup> High dose cytarabine treatment used in conjunction with total-body irradiation in the setting of induction for hematopoietic cell transplantation can rarely induce retinal microvascular damage with capillary nonperfusion, neovascularization, vitreous hemorrhage, and macular edema.<sup>13</sup>

In summary, ophthalmologists should be aware of the signs and symptoms of cytarabine-induced ocular toxicity, whereas oncologists need to know the importance of seeking ophthalmology consultation for initiation of topical corticosteroid treatment together with frequent lubrication in patients who need to receive high-dose chemotherapy regimens with cytarabine. Once cytarabine-induced keratopathy is diagnosed, topical soft steroids such as loteprednol etabonate 0.5% eye drops and frequent lubrication may also be as effective as topical dexamethasone and prednisolone eye drops in relieving ocular discomfort, photophobia, and foreign body sensation.

#### Ethics

**Informed Consent:** Obtained.

**Peer-review:** Externally peer reviewed.

#### Authorship Contributions

Surgical and Medical Practices: Ö.Ö.U., G.Ö., Concept: Ö.Ö.U., G.Ö., Design: Ö.Ö.U., G.Ö., Data Collection or Processing: G.Ö., Ö.Ö.U., Analysis or Interpretation: G.Ö., Ö.Ö.U., Literature Search: G.Ö., Ö.Ö.U., Writing: G.Ö., Ö.Ö.U.

**Conflict of Interest:** No conflict of interest was declared by the authors.

**Financial Disclosure:** This study was supported in part by a grant from Ankara University.

#### References

1. Lochhead J, Salmon JF, Bron AJ. Cytarabine induced corneal toxicity. *Eye (Lond)*. 2003;17:677-678.
2. Lass JH, Lazarus HM, Reed MD, Herzig RH. Topical corticosteroid therapy for corneal toxicity from systemically administered cytarabine. *Am J Ophthalmol*. 1982;94:617-621.
3. Kumar L, Dua H, Agarwal S, Singh S, Kochupillai V. Ocular toxicity of low dose cytosar. *N Z Med J*. 1987;100:361.
4. Higa GM, Gockerman JP, Hunt AL, Jones MR, Horne BJ. The use of prophylactic eye drops during high-dose cytosine arabinoside therapy. *Cancer*. 1991;68:1691-1693.
5. Dhillon VK, Faraj LA, Elalfy MS, Bhatt U, Said DG, Dua HS. Corneal microcysts. *Br J Ophthalmol*. 2014;98:147-148.
6. Mayer RJ, Davis RB, Schiffer CA, Berg DT, Powell BL, Schulman P, Omura GA, Moore JO, McIntyre OR, Frei E 3rd. Intensive postremission chemotherapy in adults with acute myeloid leukemia. *N Engl J Med*. 1994;331:896-903.
7. Magina KN, Pregartner G, Zebisch A, Wölfler A, Neumeister P, Greinix HT, Berghold A, Sill H. Cytarabine dose in the consolidation treatment of AML: A systematic review and meta-analysis. *Blood*. 2004;130:946-948.
8. Guthoff T, Tietze B, Meinhardt B, Becher J, Guthoff R. Cytosine-arabinoside-induced keratopathy: A model of corneal proliferation kinetics keratopathy. *Ophthalmologica*. 2010;224:308-311.
9. Hopen G, Mondino BJ, Johnson BL, Chervenick PA. Corneal toxicity with systemic cytarabine. *Am J Ophthalmol*. 1981;91:500-504.
10. Herzig RH, Wolff SN, Lazarus HM, Phillips GL, Karanes C, Herzig GP. High-dose cytosine arabinoside therapy for refractory leukemia. *Blood*. 1983;62:361-369.
11. Lazarus HM, Hartnett ME, Reed MD, Murphy BF, Lass JH. Comparison of the prophylactic effects of 2-deoxycytidine and prednisolone for high-dose intravenous cytarabine-induced keratitis. *Am J Ophthalmol*. 1987;104:476-480.
12. Hoffman DL, Howard JR, Sarma R, Riggs JE. Encephalopathy, myelopathy, optic neuropathy, and anosmia associated with intravenous cytosine arabinoside. *Clin Neuropharmacol*. 1993;16:258-262.
13. Vogler WR, Winton EF, Heffner LT, Gordon DS, Sternberg P, Crocker I, Reynolds R, Dobbs CK. Ophthalmological and other toxicities related to cytosine arabinoside and total body irradiation as preparative regimen for bone marrow transplantation. *Bone Marrow Transplant*. 1990;6:405-409.