

Clinical Outcomes of Total Hip Arthroplasty in Unilateral Crowe Type IV Hip Dysplasia

Unilateral Crowe Tip IV Kalça Displazisinde Total Kalça Artroplastisi Uygulamasının Klinik Sonuçları

1 Mehmet Özbey Büyükkuşcu¹, 2 Muhammed Bilal Kürk², 3 Yakup Alpay³, 4 Seçkin Basılğan¹, 5 Hakan Başar¹

¹University of Health Sciences Turkey, Gaziosmanpaşa Training and Research Hospital, Clinic of Orthopaedics and Traumatology, İstanbul, Turkey

²University of Health Sciences Turkey, İstanbul Başakşehir Pine and Sakura City Hospital, Clinic of Orthopaedics and Traumatology, İstanbul, Turkey

³Istanbul Sultanbeyli State Hospital, Clinic of Orthopaedics and Traumatology, İstanbul, Turkey

Cite this article as: Büyükkuşcu MÖ, Kürk MB, Alpay Y, Basılğan S, Başar H. Clinical Outcomes of Total Hip Arthroplasty in Unilateral Crowe Type IV Hip Dysplasia. J Acad Res Med 2021;11(1):5-10

ABSTRACT

Objective: To investigate the functional outcomes of femoral shortening osteotomy concomitant with cementless total hip arthroplasty (THA) in unilateral Crowe type IV hip dysplasia.

Methods: A total of 57 patients that underwent THA with femoral shortening osteotomy having the diagnosis of Crowe type IV developmental dysplasia of the hip between January 2005 and March 2016 were retrospectively reviewed. The Harris hip score and Western Ontario and McMaster Universities Osteoarthritis index were used to evaluate functional results. Abductor function was evaluated with the Trendelenburg sign before and after surgery. Major complications were assessed. The pre-operative and post-operative leg height inequality was also measured for all patients.

Results: The mean follow-up period of patients with a follow-up of at least 2 years was 47.8 months. The Trendelenburg sign, which was positive in all patients before surgery, was positive in three patients (5.2%) during the last follow-up. The mean pre-operative leg inequality was 6.9±2.4 cm, and decreased to 1.3±0.3 cm postoperatively. During the last follow-up, five patients (8.7%) had a complaint of leg length discrepancy due to a longer leg on the THA side. Functional scores of patients during the last follow-up were statistically significant higher compared to the pre-operative period.

Conclusion: Applying cementless THA in patients with unilateral Crowe type IV has satisfactory clinical results. To relieve pain and improve functional scores and quality of life, THA is the best treatment option. The rate of complications is high; however, patient can be managed with a secondary intervention or only observation.

Keywords: Developmental dysplasia, total hip arthroplasty, femoral shortening osteotomy, leg length discrepancy

ÖZ

Amaç: Tek taraflı Crowe tip IV kalça displazisinde femoral kısaltma osteotomili sementsiz total kalça artroplastisi (TKA) uygulamasının klinik sonuçlarını araştırmaktır.

Yöntemler: Ocak 2005 ile Mart 2016 yılları arasında Crowe tip IV gelişimsel kalça displazisi tanısıyla femoral kısaltma osteotomili TKA yapılan 57 hasta retrospektif olarak değerlendirildi. Fonksiyonel sonuçları değerlendirmek için Harris hip score ve Western Ontario ve McMaster Osteoartrit indeksi kullanıldı. Majör komplikasyonlar değerlendirildi. Abdüksiyon fonksiyonu ameliyat öncesi ve ameliyat sonrası Trendelenburg işareti ile değerlendirildi. Tüm hastaların ameliyat öncesi ve sonrası bacak boy eşitsizlikleri ölçüldü.

ORCID IDs of the authors: M.Ö.B. 0000-0003-1014-246X; M.B.K. 0000-0001-8956-3819; Y.A. 0000-0001-8448-5081; S.B. 0000-0002-3019-3259; H.B. 0000-0002-7701-9952.



Corresponding Author/Sorumlu Yazar: Mehmet Özbey Büyükkuşcu,

E-mail: o.z.b.e.y@hotmail.com



Received Date/Geliş Tarihi: 18.10.2020 **Accepted Date/Kabul Tarihi:** 13.12.2020

©Copyright 2021 by University of Health Sciences Turkey, Gaziosmanpaşa Training and Research Hospital. Available on-line at www.jarem.org

©Telif Hakkı 2021 Sağlık Bilimleri Üniversitesi, Gaziosmanpaşa Eğitim ve Araştırma Hastanesi. Makale metnine www.jarem.org web sayfasından ulaşılabilir.

Bulgular: En az 2 yıl takibe sahip hastaların, ortalama takip süresi 47,8 aydır. Ameliyat öncesi tüm hastalarda pozitif olan Trendelenburg işareti, son kontrollerde 3 hastada (%5,2) pozitif. Ameliyat öncesi ortalama bacak eşitsizliği $6,9 \pm 2,4$ cm iken, ameliyat sonrası ortalama $1,3 \pm 0,3$ cm'ye düştü. Son kontrolde 5 hastada (%8,7) bacak boy eşitsizliği (TKA yapılan tarafın daha uzun olduğundan şikayetçiydiler) şikayeti vardı. Hastaların son kontrollerinde fonksiyonel skorları, ameliyat öncesi döneme göre istatistiksel olarak anlamlı artış gösterdi.

Sonuç: Tek taraflı Crowe tip IV kalça displazili hastalarda çimentosuz TKA uygulamasının tatmin edici klinik sonuçları vardır. Ağrıyı hafifletmek, fonksiyonel skorları ve yaşam kalitesini iyileştirmek için TKA en iyi tedavi seçeneğidir. Komplikasyon oranı yüksek olmakla birlikte ek müdahale veya sadece gözlemlerle bu sorunlar tedavi edilebilir.

Anahtar kelimeler: Gelişimsel kalça displazisi, total kalça artroplastisi, femoral kısaltma osteotomisi, bacak boy eşitsizliği

INTRODUCTION

Unilateral Crowe type IV developmental dysplasia of the hip (DDH) is one of the most severe hip deformities, resulting to a compensatory scoliosis, leg length discrepancy, walking difficulty and back and hip pain. Total hip arthroplasty (THA) has been performed as the best treatment of choice (1,2); however, this is technically more difficult having higher complication rates when compared to primary THA due to anatomical changes that occur both on the femoral and acetabular sides (3,4). Various methods have been described to prevent complications such as leg length discrepancy and nerve symptoms to facilitate hip reduction in these patients; however, no consensus on the best technique has been reported (5-10). The most common complication after THA in unilateral Crowe type IV hip dysplasia is leg length discrepancy, which significantly reduces patient satisfaction (11,12). The relationship between hip dysplasia and leg length discrepancy depends on various factors and it has been widely investigated in literature (2,5,6,12). Metcalfe et al. (13) reported a postoperatively longer ipsilateral femur length in patients who underwent THA due to unilateral DDH. They argued that this could be an indication for the surgeon and the patient that the shorter side would be longer after surgery. Zhang et al. (14) showed that lengths of the ipsilateral femur and tibia were significantly higher in patients with unilateral DDH. They reported that the pelvic obliquity and leg length discrepancy decreased over time after THA surgery. This current study aimed to evaluate the clinical and functional results of THA with femoral shortening osteotomy in patients with unilateral Crowe type IV hip dysplasia and to compare our results with literature. We hypothesised that patient satisfaction is high in terms of leg length equality.

METHODS

Patient Population

The clinical and radiological data of patients who underwent cementless THA between January 2005 and March 2016 due to unilateral Crowe type IV DDH (15) were retrospectively reviewed. Patients with Crowe type IV hip dysplasia on one side and a healthy hip joint on the other side participated in the study. Patients with unavailable archive records, lost to follow-up and with a history of hip surgery (trauma, infection, osteotomy, etc.) were excluded. A total of 193 consecutive patients with Crowe type IV DDH underwent THA at our hospital between January 2005 and March 2016. Excluded from the study were 67 patients without a

healthy hip joint on the other side, 32 patients for whom archive records are unavailable, four patients that were lost to follow-up (mortality) and 33 patients with a history of hip surgery (trauma in seven, infection in three, and pelvic/femoral osteotomies in 23). After exclusions, a total of 57 patients were included in the study. The study was planned after receiving the approval of the University of Health Sciences Turkey, Metin Sabancı Baltalimani Bone Diseases Training and Research Hospital Ethics Committee (approval number: 262, approval date: 29.11.2018). A written informed consent was obtained from each patient.

Preoperatively, detailed physical examination and radiographic imaging (pelvis, hip and lower extremity) were performed in all patients. THA indications include severe pain, trouble walking and difficulty in performing daily life activities. Patients were evaluated clinically and radiologically at the post-operative 1, 3, 6 and 12-month follow-up visits, and then annually. Post-operative complications (non-union of the osteotomy site, superficial/deep infection, nerve damage, leg length discrepancy and dislocation) were assessed.

Clinical Evaluation

The Harris hip score (HHS) and Western Ontario and McMaster Universities Osteoarthritis Index (WOMAC) were used to evaluate functional outcomes before and after surgery. Abductor arm function was assessed using the Trendelenburg sign before and after surgery. The use and/or requirement of compensatory insoles to compensate for the post-operative leg length discrepancy were questioned in all patients.

Radiologic Evaluation

Preoperative planning was performed to determine the size of the implant to be used in the surgery and the required femoral resection length based on direct radiographs. Wooden blocks were placed in all patients under the short extremity until the pelvis was placed parallel to the floor. Routine pelvis anteroposterior (AP), hip AP and lateral and lower extremity orthoroentgenography images were obtained from all patients (Figure 1). The lower extremity length was defined as the length of the leg measured from the inter-teardrop line to the centre of the ankle joint. Leg length discrepancy was defined as the difference in the bilateral leg length (Figure 2). Subtrochanteric transverse femoral osteotomy was performed when operating on hips which necessitated >4 cm femoral lengthening.

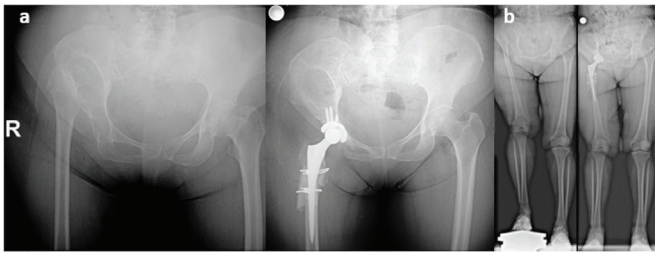


Figure 1. (a) Pre-operative and post-operative pelvis anteroposterior radiograph. (b) Pre-operative and post-operative lower extremity orthoroentgenography

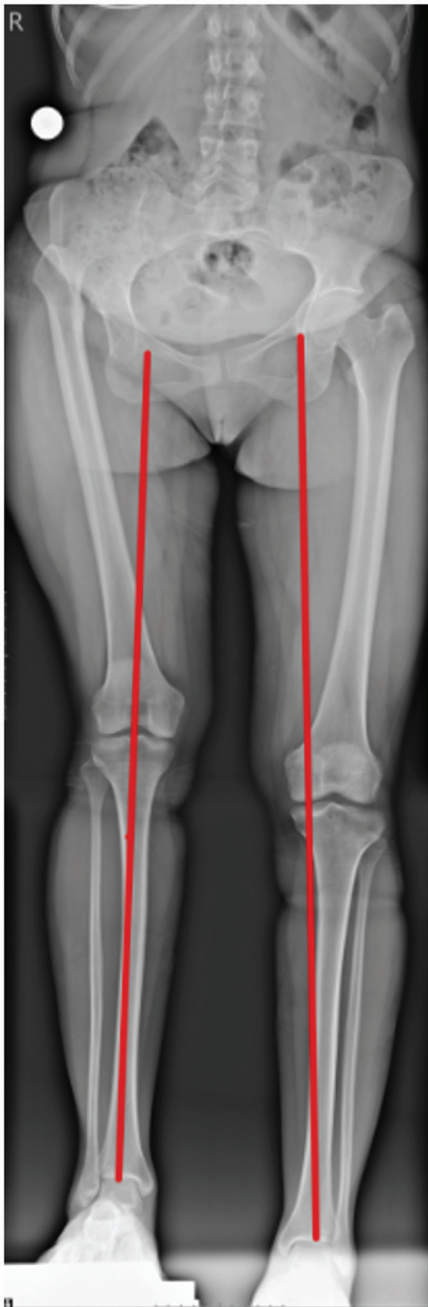


Figure 2. Measurements of leg length on full-length standing anteroposterior radiograph

Surgical Technique

Surgical operations were performed in a training and research hospital by four experienced arthroplasty surgeons. Templates were used to estimate the size of prosthetic components. General anaesthesia was applied to all patients, using posterolateral incision. The operation started in the femur. Rasping was performed on the femoral medullary canal, starting from the smallest size. Then a subtrochanteric transverse osteotomy was performed 1-2 cm distal to the trochanter minor. The amount of resection was determined based on the amount of hip dislocation, and was calculated using the Ranawat method (9), with the following formula: Resection amount (cm) = height (cm) - 3 cm. The true acetabulum became visible after the resection. The acetabular reaming was started with the posterior portion using the smallest reamer in order not to impair the anterior wall with a poorer bone stock. An acetabular cup of 1 or 2 mm larger than the reamer was placed. All patients were ensured that >70% of the acetabular cup was covered with bone, and none required additional acetabular grafting.

Shortening osteotomy had been performed on the femur at the beginning of the operation, thus, the cementless femoral stem was strengthened by providing additional fixation with Dall-Miles cables (Stryker, NJ, USA). Contracted soft tissues (gluteus maximus tendon, iliotibial band, hip adductors, tensor fascia latae, flat head of the rectus femoris tendon and iliopsoas tendon) were released in a controlled manner in cases where necessary.

The Trilogy Acetabular Hip System (Zimmer Inc, Warsaw, IN, USA) was used in 37 (65%) patients and Reflection cup (Smith and Nephew, Memphis, TN, USA) in 20 (35%). A highly cross-linked polyethylene liner was used in patients over 65 years old and a Delta ceramic liner in those younger than 65 years. Cementless femoral stems were employed in all patients. The Wagner Cone Prosthesis Stem (Zimmer Inc, Warsaw, IN, USA) was used in 37 (65%) patients and SL-PLUS Stem (Smith & Nephew, London, UK) in 20 (35%).

Post-operative Follow-up

On the first post-operative day, isometric quadriceps exercises were started, with active straight leg lifting and hip and knee exercises on the second post-operative day. Patients were allowed to sit beside their bed on the first post-operative day. All patients were mobilised with the help of a physiotherapist within 24-48 hours post-operatively after drains were removed without placing any load on the operated side. During the follow-up, patients were asked not to bear any load on the operated side for 6-8 weeks. After this period, the partial load was gradually applied, and full weight-bearing load was allowed at the end of the third month.

Statistical Analysis

Statistical analysis was performed using Statistical Package for the Social Sciences v. 22.0 (SPSS Inc., IBM, NY, USA). Categorical variables (gender and affected side) were presented

as percentages. Distribution of variables was analysed with the Kolmogorov-Smirnov test. The comparison of continuous data was performed using the Student's t-test. Two-sided, paired Student's t-test was used for the statistical analysis of the pre-operative and post-operative WOMAC, HHS and leg length discrepancy value. Statistical differences were considered to be significant when the p-value was <0.05.

RESULTS

Demographics and clinical data of patients are summarised in Table 1. The mean follow-up period was 47.8 months, ranging from 24-122 months. The mean leg length discrepancy values were 6.9 ± 2.4 (4.5-9.8) cm pre-operatively and 1.3 ± 0.3 (0-3) cm postoperatively (Figure 3). All operated legs were shorter than the legs on the contralateral side due to the shortening osteotomy; however, 5 of 57 patients (8.7%) reported a feeling that the operated side was longer than the other.

The mean HHS improved from 41.3 ± 5.2 (28-63) points pre-operatively to 85.2 ± 5.2 (70-98) points during the last follow-up ($p=0.009$) (Table 2). A significant improvement in all WOMAC subscores was observed postoperatively (Table 2).

Within 1 year after THA, complete union was observed in all osteotomy sites. The mean union time was 6.3 ± 2 (3-10) months. No severe limping during the last follow-up; however, three patients (5.2%) had moderate limping.

Intra-operative periprosthetic femoral fractures (distal femoral fragments) were seen in four cases (7%) that were fixed using titanium cable wires. Early post-operative infections were seen in two patients (3.5%) who were treated over two weeks without the need for a radical intervention other than superficial debridement and intravenous antibiotherapy. Deep vein thrombosis developed in one patient (1.75%), and sciatic nerve injury developed in three patients (5.2%) during the post-operative period. Two patients (3.5%) had complete recovery of the sciatic nerve within 6 months. Improvement was observed in one patient during the two-year follow-up with the use of ankle-foot orthosis. Early post-operative non-traumatic dislocation developed in four cases (7%), of which two underwent revision surgery within the first 10 days. Wherein, the femoral component anteversion revision was performed with femoral shortening. Closed reduction was undertaken in the remaining two patients, and no dislocation was observed again.

DISCUSSION

The most important finding of the current study was that complication rates remain high despite advances in prosthetic designs. In our patients, the sum of the intra-operative and post-operative complication rates was 24.5%. However, these complications were easily overcome by a second surgical attempt or by observation alone.

Performing THA in Crowe type IV hip dysplasia involves serious difficulties and risks due to anatomical differences (4,5,7,13,16). Femoral shortening osteotomy concomitant with THA is the most

Table 1. Demographic and clinical data of patients

	n (%)/median (range)
Number of patients (hips)	57 (57)
Age (years)	46 (22-61)
Gender	
Female	49 (86%)
Male	8 (14%)
Affected side	
Left	35 (51.5%)
Right	22 (38.5%)
Crowe classification	
Grade IV	57 (100%)
Follow-up (months)	47.8 (24-122)
Leg length discrepancy	
Pre-operative (cm)	6.9 (4.5-9.8)
Post-operative (cm)	1.3 (0-3)
Positive Trendelenburg gait	
Pre-operative	57 (100%)
Post-operative	3 (5.2%)

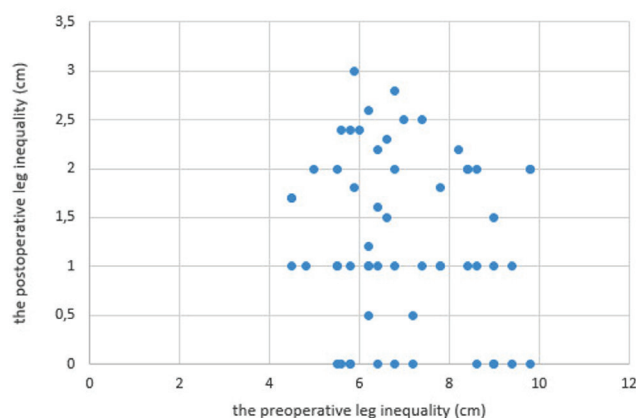


Figure 3. Diagram showing the pre-operative and post-operative leg inequality in patients

preferred technique to overcome these difficulties and minimise risks (14,17,18). In the current literature, a large number of patients that have undergone femoral shortening osteotomy concomitant with cementless THA have been evaluated functionally (11,16,19). Shi et al. (11) reported that THA combined with transverse subtrochanter osteotomy could be an effective method to achieve equal function leg length with most patients having Crowe type IV. Necas et al. (18) demonstrated good results in the treatment of completely dislocated hips with transverse osteotomy. All acetabular components were implanted into the true acetabulum, and all prostheses were stable at the latest examination. They had identified specific complications in seven hips (25%) in total: Intra-operative femoral fracture in four hips, recurrent dislocation in two hips and aseptic stem loosening in one patient. Rollo used

Table 2. Pre-operative and post-operative functional outcome scores of patients

	Pre-operative mean value (SD)	Post-operative mean value (SD)	p-value
Harris hip score	41.33 (±11.2)	85.27 (±19.8)	0.009
WOMAC pain	23 (±5.03)	6.24 (±2.12)	0.021
WOMAC stiffness	3.34 (±2.04)	0.62 (±0.18)	0.012
WOMAC function	59.73 (±15.80)	24 (±7.32)	0.001
WOMAC global	76.33 (±17.42)	30.85 (±8.98)	0.001

SD: standard deviation, WOMAC: Western Ontario and McMaster Universities Arthritis Index

transverse subtrochanter osteotomy and observed no migrations without requiring revision on implants. No cases of delayed union or non-union were detected. Two patients (11%) showed early symptoms of sciatic nerve palsy which resolved uneventfully in 6 months. Rollo reported that THA with shortening subtrochanteric osteotomy is an effective method in the treatment for patients with Crowe type IV DDH (19). According to our study, the mean HHS and WOMAC scores significantly improved after THA similar to previous studies. Post-operative improvement in patients' gait patterns and correction of pre-operative limping were satisfactory. No patient had any complaint of severe limping in the post-operative period. THA is considered to be extensively invasive with high complication rates; however, it is still the gold standard for Crowe type IV dysplasia treatment.

The current literature describes many types of osteotomy (transverse, oblique, double-chevron and step-cut) (20-25). Li et al. (23) reported that transverse femoral osteotomy has a high rate of complications, especially non-union or delayed union, due to the low bone contact area and provision of less rotational stability. In contrast, the transverse osteotomy is technically simple that allows for the correction of torsional deformities (26). In our patients, we did not see any union problems. The osteotomy sites of all patients healed within the first year of surgery. Our results confirm that transverse osteotomy is simple and safe in patients with Crowe type IV with low rate osteotomy site complications.

Ergin et al. (27) concluded that patients with unilateral DDH, pelvic height and femoral and tibial lengths on the affected side might be shorter compared to the unaffected side regardless of the Crowe type. In patients with unilateral hip osteoarthritis, the opposite side joint is intact. Prosthesis is not applied to the healthy hip, thus, the difference in the leg length cannot be overcome by another hip surgery. Therefore, these patients should be carefully evaluated in the pre-operative period to predict post-operative leg length discrepancy. According to our findings, measurements showed shorter operated legs; however, five patients complaint of having a longer lower limb on the operated side. Patients should be made aware of this issue and informed that residual leg length differences can be treated ground sill.

Study Limitations

Certain limitations were encountered in this study. First concerns the retrospective design. Second, patients with a unilateral high

hip develop a compensatory low lumbar curvature to decrease the leg length differences; however, the extent of improvement in the lumbar pathology after surgery was not evaluated. Third, our follow-up period was relatively short, and longer-term results are necessary in these patients. Component loosening and revision rates should be evaluated with the Kaplan-Meier survival curve over a long period of time.

CONCLUSION

Applying cementless THA in patients with unilateral Crowe type IV has satisfactory functional results. To relieve pain and improve functional scores and quality of life, THA remains the best treatment option. The rate of associated complications is high; however, they can be usually managed with a secondary intervention or only observation.

Ethics Committee Approval: The study was planned after receiving the approval of the University of Health Sciences Turkey, Metin Sabancı Baltalimanı Bone Diseases Training and Research Hospital Ethics Committee (approval number: 262, approval date: 29.11.2018).

Informed Consent: A written informed consent was obtained from each patient.

Peer-review: Externally peer-reviewed.

Author Contributions: Surgical and Medical Practices - M.Ö.B., Y.A., S.B.; Concept - M.Ö.B., S.B., H.B.; Design - M.B.K.; Data Collection and/or Processing - M.B.K., H.B.; Analysis and/or Interpretation - Y.A., H.B.; Literature Search - M.B.K., S.B.; Writing - M.Ö.B., S.B.

Conflict of Interest: The authors have no conflict of interest to declare.

Financial Disclosure: The authors declared that this study has received no financial support.

Etik Komite Onayı: Çalışma, Sağlık Bilimleri Üniversitesi, Metin Sabancı Baltalimanı Kemik Hastalıkları Eğitim ve Araştırma Hastanesi Etik Kurulu'nun (onay no: 262, onay tarihi: 29.11.2018) onayı alındıktan sonra planlandı.

Hasta Onamı: Her hastadan yazılı bilgilendirilmiş onam alındı.

Hakem Değerlendirmesi: Editörler kurulu dışında olan kişiler tarafından değerlendirilmiştir.

Yazar Katkıları: Cerrahi ve Medikal Uygulama - M.Ö.B., Y.A., S.B.; Konsept - M.Ö.B., S.B., H.B.; Dizayn - M.B.K.; Veri Toplama veya İşleme - M.B.K., H.B.; Analiz veya Yorumlama - Y.A., H.B.; Literatür Arama - M.B.K., S.B.; Yazan - M.Ö.B., S.B.

Çıkar Çatışması: Yazarlar tarafından çıkar çatışması bildirilmemiştir.

Finansal Destek: Yazarlar tarafından finansal destek almadıkları bildirilmiştir.

REFERENCES

1. Anwar MM, Sugano N, Masuhara K, Kadowaki T, Takaoka K, Ono K. Total hip arthroplasty in the neglected congenital dislocation of the hip. A five to 14-year follow-up study. *Clin Orthop* 1993; 295: 127-34.
2. Lai KA, Shen WJ, Huang LW, Chen MY. Cementless total hip arthroplasty and limb-length equalization in patients with unilateral crowe type-IV hip dislocation. *J Bone Joint Surg Am* 2005; 87: 339-45.
3. Dırvar F, Ezici A, Özcafer R, Bayhan İA. Location of femoral vessels around the acetabulum in crowe type 4 dysplastic hips. *J Arthroplasty* 2020; 35: 3765-8.
4. Buyukkücü MO, Camurcu İY, Misir A, Gursu SS, Sahin V. Previous hip surgery due to developmental dysplasia of the hip affects major complication rates but not revision rates in total hip arthroplasty. *Ann Med Res* 2020; 27: 1121-5.

5. Yetkin C, Yildirim T, Alpay Y, Tas SK, Buyukkusu MO, Dirvar F. Evaluation of dislocation risk factors with total hip arthroplasty in developmental hip dysplasia patients: a multivariate analysis. *J Arthroplasty* 2021; 36: 636-40.
6. Li Y, Zhang X, Wang Q, Peng X, Wang Q, Jiang Y, et al. Equalisation of leg lengths in total hip arthroplasty for patients with crowe type-IV developmental dysplasia of the hip: classification and management. *Bone Joint J* 2017; 99-B: 872-9.
7. Hasegawa Y, Iwase T, Kanoh T, Seki T, Matsuoka A. Total hip arthroplasty for Crowe type IV developmental dysplasia. *J Arthroplasty* 2012; 27: 1629-35.
8. Kerboul M, Hamadouche M, Kerboul L. Total hip arthroplasty for Crowe type IV developmental hip dysplasia: a long-term follow-up study. *J Arthroplasty* 2001; 16: 170-6.
9. Bernasek TL, Haidukewych GJ, Gustke KA, Hill O, Levering M. Total hip arthroplasty requiring subtrochanteric osteotomy for developmental hip dysplasia: 5- to 14-year results. *J Arthroplasty* 2007; 22: 145-50.
10. Fujishiro T, Nishiyama T, Hayashi S, Kurosaka M, Kanno T, Masuda T. Leg length change in total hip arthroplasty with subtrochanteric femoral shortening osteotomy for Crowe type IV developmental hip dysplasia. *J Arthroplasty* 2012; 27: 1019-22.
11. Shi XT, Cheng CM, Feng CY, Li C, Li S, Liu J. Crowe type IV hip dysplasia treated by the combined with osteotomy to balance functional leg length discrepancy: a prospective observational study. *Orthop Surg* 2020; 12: 533-42.
12. Du YQ, Sun JY, Ma HY, Wang S, Ni M, Zhou YG. Leg length balance in total hip arthroplasty for patients with unilateral crowe type IV developmental dysplasia of the hip. *Orthop Surg* 2020; 12: 749-55.
13. Metcalfe JE, Banaszkiwicz P, Kapoor B, Richardson J, Jones CW, Kuiper J. Unexpected long femur in adults with acetabular dysplasia. *Acta Orthop Belg* 2005; 71: 424-8.
14. Zhang Z, Luo D, Cheng H, Xiao K, Zhang H. Unexpected long lower limb in patients with unilateral hip dislocation. *J Bone Joint Surg Am* 2018; 100: 388-95.
15. Crowe JF, Mani VJ, Ranawat CS. Total hip replacement in congenital dislocation and dysplasia of the hip. *J Bone Joint Surg Am* 1979; 1: 15-23.
16. Kocabiyik A, Misir A, Kizkapan TB, Yildiz KI, Kaygusuz MA, Alpay Y, et al. Changes in hip, knee, and ankle coronal alignments after total hip arthroplasty with transverse femoral shortening osteotomy for unilateral crowe type IV developmental dysplasia of the hip. *J Arthroplasty* 2017; 32: 3449-56.
17. Parmaksizoglu AS, Ozkaya U, Bilgili F, Basilgan S, Kabukcuoglu Y. Large diameter metal-on-metal total hip arthroplasty for Crowe IV developmental dysplasia of the hip. *Hip Int* 2009; 19: 309-14.
18. Necas L, Hrubina M, Melisik M, Zoltan C, Michal C, Matej D, et al. Cementless hip arthroplasty and transverse shortening femoral osteotomy with the S-ROM stem for Crowe type IV developmental dysplasia. *Eur J Orthop Surg Traumatol* 2019; 29: 1025-33.
19. Rollo G, Solarino G, Vicenti G, Picca G, Carrozzo M, Moretti B. Subtrochanteric femoral shortening osteotomy combined with cementless total hip replacement for Crowe type IV developmental dysplasia: a retrospective study. *J Orthop Traumatol* 2017; 18: 407-13.
20. Eskelinen A, Helenius I, Remes V, Ylinen P, Tallroth K, Paavilainen T. Cementless total hip arthroplasty in patients with high congenital hip dislocation. *J Bone Joint Surg Am* 2006; 88: 80-91.
21. Yalcin N, Kilicarslan K, Karatas F, Mutlu T, Yildirim H. Cementless total hip arthroplasty with subtrochanteric transverse shortening osteotomy for severely dysplastic or dislocated hip. *Hip Int* 2010; 20: 87-93.
22. Huo MH, Zatorski LE, Keggi KJ. Oblique femoral osteotomy cementless total hip arthroplasty. Prospective consecutive series with a 3-year minimum follow-up period. *J Arthroplasty* 1995; 10: 319-27.
23. Li C, Zhang C, Zhang M, Ding Y. Comparison of transverse and modified subtrochanteric femoral shortening osteotomy in total hip arthroplasty for developmental dysplasia of hip: a meta-analysis. *BMC Musculoskelet Disord* 2014; 15: 331.
24. Li X, Sun J, Lin X, Xu S, Tang T. Cementless total hip arthroplasty with a double chevron subtrochanteric shortening osteotomy in patients with Crowe type-IV hip dysplasia. *Acta Orthop Belg* 2013; 79: 287-92.
25. Ozden VE, Dikmen G, Beksac B, Tozun IR. Total hip arthroplasty with step-cut subtrochanteric femoral shortening osteotomy in high riding hip dislocated patients with previous femoral osteotomy. *J Orthop Sci* 2017; 22: 517-23.
26. Hotokebuchi T, Sonohata M, Shigematsu M, Mawatari M. A new device for a v-shaped subtrochanteric osteotomy combined with total hip arthroplasty. *J Arthroplasty* 2006; 21: 135-7.
27. Ergin ÖN, Bayram S, Anarat FB, Ekinci M, Mert L, Özmenet E, et al. An analysis of the potential relationship between crowe type and lower extremity morphology in patients with developmental dysplasia of the hip. *Hip Pelvis* 2020; 32: 85-92.