

DOI: 10.4274/jarem.galenos.2020.3640

J Acad Res Med 2021;11(1):117-119

# Relapse of T-Cell Lymphoma as Isolated Brachial Plexus Neurolymphomatosis: A Case Report

## T-Hücreli Lenfomanın İzole Brakial Pleksus Nörolenfomatozisi Olarak Relapsı: Olgu Sunumu

Kenan Kibıcı<sup>1</sup>, Berrin Erok<sup>2</sup>, Ali Önder Atça<sup>3</sup>, Gülçin Yeğen<sup>4</sup>

<sup>1</sup>Altınbaş University Faculty of Medicine, Bahçelievler Medical Park Hospital, Department of Neurosurgery, İstanbul, Turkey

<sup>2</sup>University of Health Sciences Turkey, Prof. Dr. Cemil Taşcıoğlu City Hospital, Clinic of Radiology, İstanbul, Turkey

<sup>3</sup>Altınbaş University Faculty of Medicine, Bahçelievler Medical Park Hospital, Department of Radiology, İstanbul, Turkey

<sup>4</sup>İstanbul University Faculty of Medicine, Department of Pathology, İstanbul, Turkey

**Cite this article as:** Kibıcı K, Erok B, Atça AÖ, Yeğen G. Relapse of T-Cell Lymphoma as Isolated Brachial Plexus Neurolymphomatosis: A Case Report. *J Acad Res Med* 2021;11(1):117-119

### ABSTRACT

Neurolymphomatosis (NL) is the neoplastic endoneurial invasion of the peripheral nervous system. It is a rare and challenging diagnosis, but it should be taken into account in the differential diagnosis of peripheral neuropathy, particularly in patients with a documented history of haematologic malignancy. Magnetic resonance (MR) neurography is very useful in diagnosis and especially when correlated with positron emission tomography/computed tomography (PET/CT). In equivocal cases, nerve biopsy can be considered when the benefit outweighs the risk. We aimed to report a case of a 30-year-old male patient who was in complete remission from T-lymphoblastic lymphoma, presenting with clinical findings indicating initially ulnar entrapment. However, with the demonstration of brachial plexopathy with axonal loss in electrodiagnostic studies, MR imaging neurography dedicated to brachial plexus was carried out and revealed pathological enhancement associated with mild fluorodeoxyglucose (FDG) uptake on PET/CT. Moreover, NL, due to the relapse of T-cell lymphoma, was diagnosed through incisional biopsy, showing diffuse infiltration of blast cells positive for terminal deoxynucleotidyl transferase, CD3 and CD10. Further, radiotherapy and systemic chemotherapy were initiated, and symptoms recovered with regression of pathological FDG uptake.

**Keywords:** Neurolymphomatosis, T-cell lymphoblastic lymphoma, brachial plexopathy

### ÖZ

Nörolenfomatoz (NL) periferik sinir sisteminin neoplastik endonöral invazyonudur. Nadir ve zorlayıcı bir tanıdır ancak, özellikle hematolojik malignite öyküsü bulunan hastalarda periferik nöropatinin ayırıcı tanısında düşünülmelidir. Magnetik rezonans (MR) nörografi özellikle pozitron emisyon tomografisi-bilgisayarlı tomografi (PET/BT) ile beraber kullanıldığında tanıda çok yararlıdır. Arada kalınan olgularda fayda riskten ağır bastığında sinir biyopsisi tanıda düşünülebilir. Bizde, T-lenfoblastik lenfomada tam remisyonda olan, başlangıçta ulnar tuzak nöropatisini düşündüren bulgularla prezente olan 30 yaşındaki erkek hastamızı sunmayı amaçladık. Ancak, elektrodagnostik çalışmalarda aksonal kaybın eşlik ettiği brakial pleksopatinin gösterilmesi üzerine brakial pleksusa yönelik yapılan MR nörografide sağ brakial pleksusta patolojik kontrastlanma ve bu alanda PET/BT’de patolojik florodeoksiglukoz (FDG) tutulumu izlendi. Terminal deoksinükleotidil transferaz, CD3 ve CD10 için pozitif olan yaygın blastik hücre infiltrasyonları gösterilerek T-hücreli lenfoma relapsı ile oluşan NL tanısı insizyonel biyopsi ile konuldu. Radyoterapi ve sistemik kemoterapi tekrar başlandı ve hastanın bulgularında patolojik FDG tutulumunda gerileme ile beraber iyileşme oldu.

**Anahtar kelimeler:** Nörolenfomatozis, T-hücreli lenfoblastik lenfoma, brakial pleksopati

### INTRODUCTION

Neurolymphomatosis (NL) is the neoplastic endoneurial invasion of the peripheral nervous system (PNS). It differs from meningeal lymphomatosis, which is the infiltration of the PNS due to subarachnoid seeding (1). Furthermore, NL occurs more

frequently with the spread of a known malignancy into the PNS from systemic sites or from the primary central nervous system (CNS) lymphoma (PCNSL) as a progression in the course of the disease or as a relapse following complete remission. More rarely, it may occur as an initial manifestation of the disease. We report a

**ORCID IDs of the authors:** K.K. 0000-0002-5912-9648; B.E. 0000-0001-8036-547X; A.Ö.A. 0000-0002-7500-3316; G.Y. 0000-0003-2497-219X.

**Corresponding Author/Sorumlu Yazar:** Berrin Erok,

E-mail: drberrinerok@hotmail.com



**Received Date/Geliş Tarihi:** 29.07.2020 **Accepted Date/Kabul Tarihi:** 22.12.2020

©Copyright 2021 by University of Health Sciences Turkey, Gaziosmanpaşa Training and Research Hospital. Available on-line at www.jarem.org

©Telif Hakkı 2021 Sağlık Bilimleri Üniversitesi, Gaziosmanpaşa Eğitim ve Araştırma Hastanesi. Makale metnine www.jarem.org web sayfasından ulaşılabilir.

case of a 30-year-old male patient with right brachial plexopathy caused by the relapse of T-lymphoblastic lymphoma.

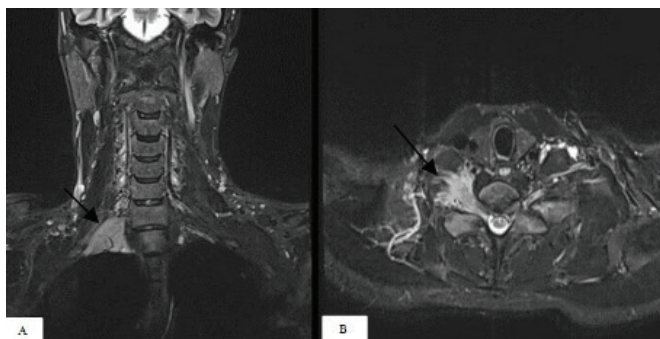
## CASE PRESENTATION

A 30-year-old male patient presented with right medial forearm and hand pain and numbness in the fourth and fifth fingers, initially indicating ulnar nerve entrapment. A year ago, he was treated for T-lymphoblastic leukaemia/lymphoma and achieved complete remission with no pathological fluorodeoxyglucose (FDG) uptake in positron emission tomography/computed tomography PET/CT. In neurological examination, muscular strengths of the forearm flexors and intrinsic hand muscles were poor, and there was pain-related paraesthesia. Moreover, no disc impingement was demonstrated by cervical magnetic resonance imaging (MRI). Ulnar nerve entrapment was considered; however, electrodiagnostic studies revealed right lower truncus brachial plexopathy associated with axonal loss and active denervation. Gadolinium-enhanced MRI neurography showed a 25x32x41 mm-sized enhancing extrapulmonary lesion located at the apical part of the right hemithorax, affecting the middle and lower part of the brachial plexus (BP) (Figure 1). No pathological signal was detected in the adjacent pulmonary parenchyma. Also, there was no extension into the spinal canal. PET/CT showed a mild hypermetabolic FDG uptake (maximum standardized uptake value: 3.04) in the lesion. Moreover, NL was considered and incisional biopsy was performed to make an exact diagnosis. During the antigenic assessment, diffuse infiltration of blast cells positive for terminal deoxynucleotidyl transferase, CD3 and CD10 was demonstrated (Figure 2). Once again, radiotherapy and systemic chemotherapy was started. With the regression of pathological FDG uptake in PET/CT, his symptoms recovered with improvement of muscle strengths from 3/5 to 5/5.

Written informed consent has been taken from the patient.

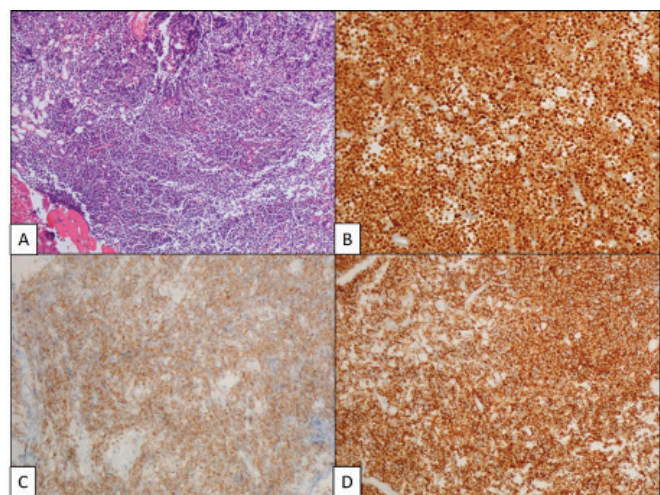
## DISCUSSION

NL is a very rare neurological manifestation of haematologic malignancies that should be distinguished from the more prevalent causes of PNS involvement, such as radiation-induced



**Figure 1.** Brachial plexus magnetic resonance imaging neurography with gadolinium, short-tau inversion recovery sequence sagittal (A) and axial (B) images showing pathologic enhancement in the right brachial plexus (black arrows)

peripheral neuropathy or paraneoplastic syndromes. Most cases of NL are associated with diffuse large B-cell non-Hodgkin's lymphoma (DLBCL) but can also occur in T-cell and NK-cell lymphomas or acute leukaemias. According to the report of the International Primary CNS Lymphoma Collaborative Group, NL developed in 50 patients over a 16-year period, of which 90% were associated with non-Hodgkin's lymphoma (NHL) and 10% with acute leukaemia (2). In a 12-year retrospective analysis of 1,181 patients with NHL, 22 cases of NL were identified, of which 20 patients were associated with DLBCL, 1 patient with mantle cell lymphoma, and 1 patient with peripheral T-cell lymphoma (3). In another report of 23 cases with NL of lumbosacral plexus, B-cell histology was seen in 21 cases and T-cell histology in only 2 cases (4). In our patient, NL was related to a relapse of T-cell lymphoma. Since the clinical findings are not clear, it is frequently misdiagnosed, especially when the neuropathy is the initial presentation or manifests after a period of complete remission, as in our case. When the BP is affected, the presenting symptoms are weakness, paraesthesia and pain radiating down to the upper limb or localised in the forearm and hand in cases of middle and lower trunk involvement, as in our case. In contrast to the radiation-induced brachial plexopathy that commonly affects the upper trunk or metastatic brachial plexopathy that has a predilection for the lower trunk, all parts of BP may be invaded by lymphomatous cells from the roots to the distal branches with no distinctive distribution (5). As suggestive of NL, severe pain, rapid evolution and asymmetric distribution have been reported (2). However, relatively painless or symmetrical neuropathy has also been defined (6,7). Although axonal sensory motor neuropathy is more frequent in nerve conduction studies, pure demyelinating and mixed neuropathy have also been reported (7). Moreover, due to its low sensitivity, cerebrospinal fluid (CSF) cytology is used in the diagnosis but is not always helpful (6). Neuroimaging studies with MRI neurography often provide a correct diagnosis, especially when performed together with PET/CT. On MRI,



**Figure 2.** Incisional biopsy of the brachial plexus lesion showing diffuse infiltration of blast cells (H&E) (A), which were positive for terminal deoxynucleotidyl transferase (B), CD3 (C) and CD10 (D) in the antigenic assessment

normal nerves are usually smaller than the accompanying arteries, showing gradual tapering in a well-organised fascicular distribution with isointensity to skeletal muscles on both T1w and T2w images without enhancement, except the dorsal root ganglia which should not be confused with a tumoral process. In NL, focal or diffuse nerve enlargement, fascicular disorganisation, hyperintensity on T2w or short-tau inversion recovery sequences and significant focal or diffuse gadolinium enhancement are seen. Although these are not specific for NL, they are highly suggestive when associated with PET/CT, which is the most accurate modality in the evaluation of nodal and extranodal spread of lymphoma (8,9). In nerve pathology, the gold standard method of diagnosis is nerve biopsy, but it is not performed in all patients because of a significant risk of permanent nerve damage. Moreover, it is concerned when the benefit outweighs the risk and the imaging studies along with CSF examinations are inconclusive. In general, treatment of NL is similar to that of PCNSL, which includes systemic and/or intrathecal chemotherapy with or without radiotherapy (8). In rare instances, surgical intervention, such as emergent decompression, is needed. Our patient was treated with radiotherapy and systemic chemotherapy with achievement of complete remission. Since the relapse of the lymphoma in our patient was localised to the right BP, radiotherapy was performed with limited-field radiation. Despite the treatment, the prognosis is worse in patients with NL than in those without (10). Although the lack of optimal treatment one of the causes, it may also be due to misdiagnosis that leads to delayed targeted treatment.

## CONCLUSION

NL remains a rare and challenging diagnosis. It should be considered when a patient with a known history of haematologic malignancy presents with peripheral neuropathy, especially when the symptoms are asymmetric and rapidly evolving. MRI neurography and PET/CT are very helpful and should be used together to improve sensitivity. In equivocal cases, nerve biopsy can be used for early diagnosis when the benefit outweighs the risk, especially when, as in our case, there is an already existing axonal pattern of damage.

**Informed Consent:** Written informed consent has been taken from the patient.

**Peer-review:** Externally and internally peer-reviewed.

**Author Contributions:** Surgical and Medical Practices - K.K.; Concept - K.K., B.E., A.Ö.A., G.Y.; Design - B.E., A.Ö.A.; Data Collection or Processing - B.E.; Analysis or Interpretation - K.K., B.E. G.Y.; Literature Search - B.E.; Writing - K.K., B.E.

**Conflict of Interest:** The authors have no conflict of interest to declare.

**Financial Disclosure:** The authors declared that this study has received no financial support.

**Hasta Onamı:** Hastadan yazılı onam alındı.

**Hakem Değerlendirmesi:** Editörler kurulu ve editörler kurulu dışında olan kişiler tarafından değerlendirilmiştir.

**Yazar Katkıları:** Cerrahi ve Medikal Uygulamalar - K.K.; Fikir - K.K., B.E., A.Ö.A., G.Y.; Tasarım - B.E., A.Ö.A.; Veri Toplanması ve/veya İşlemesi - B.E.; Analiz ve/veya Yorum - K.K., B.E. G.Y.; Literatür Taraması - B.E.; Yazıyı Yazan - K.K., B.E.

**Çıkar Çatışması:** Yazarların beyan edecek çıkar çatışması yoktur.

**Finansal Destek:** Yazarlar bu çalışma için finansal destek almadıklarını beyan etmişlerdir.

## REFERENCES

1. Stark, AM, Mehdorn, HM. Leptomeningeal metastasis of an intradural malignant peripheral nerve sheath tumor. *J Clin Neurosci* 2013; 20: 1181-3.
2. Grisariu S, Avni B, Batchelor TT, van den Bent MJ, Bokstein F, Schiff D, et al. Neurolymphomatosis: an International Primary CNS Lymphoma Collaborative Group report. *Blood* 2010; 115: 5005-11.
3. Narita K, Terao T, Tsushima T, Kitadate A, Miura D, Takeuchi M, et al. Clinical features, diagnosis, and prognosis of 22 cases of neurolymphomatosis: a single-institution experience over 12 years. *Blood* 2019; 134(Suppl 1): 1630.
4. Bourque PR, Sampaio ML, Warman-Chardon J, Samaan S, Torres C. Neurolymphomatosis of the lumbosacral plexus and its branches: case series and literature review. *BMC Cancer* 2019; 19: 1149
5. Khadilkar SV, Khade SS. Brachial plexopathy. *Ann Indian Acad Neurol* 2013; 16: 12-8.
6. Baehring JM, Damek D, Martin EC, Betensky RA, Hochberg FH. Neurolymphomatosis. *Neuro Oncol* 2003; 51: 104-15.
7. Shree R, Goyal MK, Modi M, Gaspar BL, Radotra BD, Ahuja CK, et al. The diagnostic dilemma of NL. *J Clin Neurol* 2016; 12: 274-81.
8. Saji E, Kawachi I, Nishizawa M. [Diagnosis and management of paraneoplastic neurological syndromes]. *Brain Nerve* 2010; 62: 319-30.
9. Bourque PR, Warman Chardon J, Bryanton M, Toupin M, Burns BF, Torres C. Neurolymphomatosis of the brachial plexus and its branches: case series and literature review. *Can J Neurol Sci* 2018; 45: 137-43.
10. Sideras PA, Matthews J, Sakib SM, Ofikwu F, Spektor V. Neurolymphomatosis of the peripheral nervous system: a case report and review of the literature. *Clin Imaging* 2016; 40: 1253-6.