

© Ayşe Vahapoğlu,
© Döndü Genç Moralar,
© Ferhat Çengel,
© Zuhul Çavuş,
© Ülkü Aygen Türkmen

Evaluation of the Correlation Between Thoracic Ultrasound and Thoracic Computed Tomography Scores of Patients with Severe COVID-19 Pneumonia Receiving Intensive Care

Yoğun Bakımda Şiddetli COVID-19 Pnömonili Hastalarda, Toraks Ultrason ve Toraks Bilgisayarlı Tomografi Skorlamaları Arasındaki Korelasyonun Değerlendirilmesi

Received/Geliş Tarihi : 19.10.2020
Accepted/Kabul Tarihi : 20.01.2021

Ayşe Vahapoğlu, Döndü Genç Moralar, Zuhul Çavuş,
Ülkü Aygen Türkmen
University of Health Sciences Turkey, Gaziosmanpaşa
Training and Research Hospital, Clinic of
Anaesthesiology and Reanimation, Istanbul, Turkey

Ayşe Vahapoğlu MD, (✉),
University of Health Sciences Turkey, Gaziosmanpaşa
Training and Research Hospital, Clinic of
Anaesthesiology and Reanimation, Istanbul, Turkey

E-mail : aysevahapoglu@yahoo.com

Phone : +90 505 819 47 64

ORCID ID : orcid.org/0000-0002-6105-4809

ABSTRACT Objective: The coronavirus disease-19 (COVID-19) pandemic has become a global health problem within a short time because of its high infection rate and increasing mortality. Since it is not possible to perform thoracic computed tomography (CT) and transfer patients with COVID-19 pneumonia who are followed-up in the intensive care unit, diagnosis and follow-up using lung ultrasound (LUS) has become a great advantage nowadays. This study aimed to evaluate the correlation between the thoracic CT score and LUS score and to determine their relationship with mortality.

Materials and Methods: Patients who were admitted to the intensive care unit with the diagnosis of COVID-19 pneumonia, who had an initial thoracic CT examination and who underwent LUS during admission to the intensive care unit were included in the study. The demographic characteristics, clinical parameters, prognosis and thoracic CT and LUS scores of the patients were recorded prospectively. The characteristics of the survivors and deceased patients were compared.

Results: The mean age of the 29 patients included in this study was 61.93 ± 14.21 years, and the male-to-female ratio was 18/11 (62.1%/37.9%). A strong positive correlation was found between the thoracic CT score and LUS score ($r = 0.964$; $p < 0.001$). The thoracic CT and LUS scores of the survivors were 15.5 ± 2.7 and 27.3 ± 4.9 , respectively, while those of the deceased patients were 14.1 ± 3.4 and 25.6 ± 5.8 , respectively, and no significant difference was found between the two groups.

Conclusion: A strong positive correlation was found between the thoracic CT score and LUS score of patients with severe COVID-19 pneumonia admitted to the intensive care unit. This result shows that LUS is easily preferred for patients who require imaging for diagnosis and follow-up under intensive care conditions. The mortality rates of patients with COVID-19 pneumonia could not be predicted by either thoracic CT score or LUS score.

Keywords: COVID-19 pneumonia, critical care, lung ultrasound, computed tomography

ÖZ Amaç: Coronavirus Disease 19 (COVID-19) pandemisi, yüksek enfeksiyon oranı ve artan mortalite nedeniyle kısa sürede küresel bir sağlık sorunu haline gelmiştir. Yoğun bakımda takip edilen COVID-19 pnömonili hastaların sık sık toraks computed tomography (CT) çekilmesi ve transferi mümkün olmadığından, günümüzde teşhis ve takiplerinin lung ultrasound (LUS) ile yapılması büyük avantaj sağlamaktadır. Çalışmamızda, yoğun bakımda yatan, şiddetli COVID-19 pnömonili hastaların, toraks CT skoru ile LUS skoru arasındaki korelasyonu değerlendirip, mortalite ile ilişkisini saptamayı amaçladık.

Gereç ve Yöntem: Çalışmada COVID-19 pnömoni tanısı ile yoğun bakıma yatırışı yapılan, başlangıç toraks CT tetkiki bulunan ve yoğun bakım yatışında LUS yapılan hastalar dahil edildi. Hastaların demografik özellikleri, klinik parametreleri, prognozu, toraks CT ve LUS skorları, prospektif olarak kaydedildi. Hayatta kalan hastalar ile ex olan hastaların özellikleri kıyaslandı.

Bulgular: Çalışmaya alınan 29 hastanın, yaş ortalaması 61.93 ± 14.21 , erkek / kadın oranı 18/11

(%62.1/%37.9) tesbit edildi. Toraks CT skoru ile LUS skoru arasında güçlü pozitif bir korelasyon saptandı ($r=0.964$; $p<0.001$). Sağ kalanların toraks CT skoru 15.5 ± 2.7 , LUS skoru 27.3 ± 4.9 ; Ex olanların toraks CT skoru 14.1 ± 3.4 , LUS skoru 25.6 ± 5.8 olup iki grup arasında anlamlı fark saptanamadı.

Sonuç: Yoğun bakıma yatırışı yapılan, şiddetli COVID-19 pnömonili hastaların toraks CT skoru ile LUS skoru arasında güçlü pozitif bir korelasyon saptanmıştır. Bu sonuç yoğun bakım şartlarında teşhis ve takipte, görüntüleme gereken hastalarda LUS'un kolaylıkla tercih edilebileceğini göstermektedir. Ne toraks CT ne de LUS skoru ile COVID-19 pnömonili hastaların mortalitesi predikte edilememiştir.

Anahtar Kelimeler: COVID-19 pnömoni, yoğun bakım, akciğer ultrasonu, bilgisayarlı tomografi

Introduction

The world is currently facing a pandemic that is rapidly spreading due to complications in the respiratory system that results in pneumonia, caused by a new coronavirus (SARS-COV-2) and called COVID-19 in 2019 (1). It is estimated that 15–20% of infected people develop severe pneumonia and 5–10% of the infected require critical care (2).

Imaging modalities play a crucial role in the diagnosis and management of suspected COVID-19 patients (3). Chest radiograph shows low-density pneumonia foci (viral pneumonia), which mostly involve bilateral mid-lower zones in this disease. However, the sensitivity of chest X-ray is low (30-60%) (4), and normal chest radiograph does not exclude pneumonia (1-5). CT findings have proven to be diagnostic in most of the cases with an initial false-negative reverse transcriptase-polymerase chain reaction (RT-PCR) screening test (6,7). Patients with COVID-19 typically present with bilateral multilobar ground-glass opacification, crazy-paving pattern and consolidation etc. with a peripheral distribution (8). Although CT is a highly sensitive and specific imaging technique, it has some disadvantages, especially for critically ill patients who are monitored in intensive care. The transfer of a patient with COVID-19 from the intensive care unit for CT, who is monitored in invasive mechanical ventilation (IMV), has drawbacks both in terms of the spread of infection and the patients' exposure to ionized radiation due to the patient's critical condition. The CT scanner needs to be thoroughly cleaned after each suspected case of COVID-19, to prevent the spread of the infection to other patients and healthcare staff (9).

LUS, which is currently used as a diagnostic tool in emergency departments (1), is a promising imaging tool for COVID-19, considering both the peripheral involvement of the lung and the disadvantages of CT and plain radiograph (8). This imaging modality is portable, quick, repeatable, easy to learn, with high inter-rater and intra-rater reproducibility (10). Due to its ease of use at the bedside (11), it can also be guiding in the management of the disease and follow-up

in patients having a high mortality risk who are monitored with invasive mechanical ventilation (12) in the intensive care unit. Although patients with COVID-19 receiving invasive ventilation will often have non-recrutable lung lesions early on, recruitable lesions may develop later in the disease course (9). LUS could titrate ventilator settings in positive end-expiratory pressure (PEEP) -induced lung recruitment, and also facilitates successful weaning from mechanical ventilation (12). Its easy repeatable can also be useful in the early diagnosis of complications. In this study, the evaluation of the correlation between the baseline LUS score and CT score of patients with severe COVID-19 pneumonia who were followed up in the intensive care unit was determined as the primary end point and its correlation with mortality was determined as the secondary end point.

Materials and Methods

Patients

The study was approved by the local Ethics Committee of our hospital (No: 28.05.2020 / 87). Written informed consent was obtained from the patients to be included in the study and/or their relatives. The study was conducted prospectively between June 2020 and July 2020. The inclusion criteria were as follows: among patients and/or their relatives those who gave written consent, who were over 18 years of age, hospitalized in intensive care with a diagnosis of COVID-19 pneumonia, had a definite diagnosis by PCR, had an initial thorax CT examination, and underwent LUS at admission to intensive care. The exclusion criteria were as follows: patients under 18 years of age who did not give written consent, had no definitive diagnosis by PCR, previous lung resection, no thorax CT and LUS at admission to intensive care. Thorax CT scoring was performed by an experienced radiologist, while LUS scoring was performed an experienced anesthesia and reanimation specialist. The demographic characteristics, clinical parameters, prognosis, thorax CT and LUS scores of the patients were recorded

prospectively. The correlation between thorax CT score and LUS score was evaluated.

Radiological Evaluation

Lung Ultrasound Score (LUSS)

LUS was performed by an intensive care specialist with experience in this field using a 2- to 5-MHz transducer (Esaote MyLabSeven, Getz Healthcare Malaysia). The transducer was covered with a probe cover, and the transducer and ultrasound device were cleaned with disinfectant wipes after each use. LUS examinations were performed at the bedside, in the supine position, and twelve-zone examinations were performed. Each hemithorax is separated into 6 quadrants: anterior, lateral, and posterior zones (separated by the anterior and posterior axillary lines) each divided in upper and lower portion (Figure 1). Each zone was scored according to the LUS pattern as follows: the presence of lung sliding with A-lines or fewer than two isolated B-lines, scored 0; when multiple well-defined B-lines presented, scored 1; the presence of multiple coalescent B-lines, scored 2; and when presented with a tissue pattern characterized by dynamic air bronchograms (lung consolidation), scored 3. The worst ultrasound pattern observed in each zone was recorded and used to calculate the sum of the scores (total score = 36).

CT Technique and Image Interpretation

The thorax CT scans in the study were obtained using the low dose protocol of our hospital with a 128-slice multi-detector CT scanner (Optima; General Electric Healthcare, Wisconsin, USA). All CT scans were performed during a single breath-hold without contrast administration. All

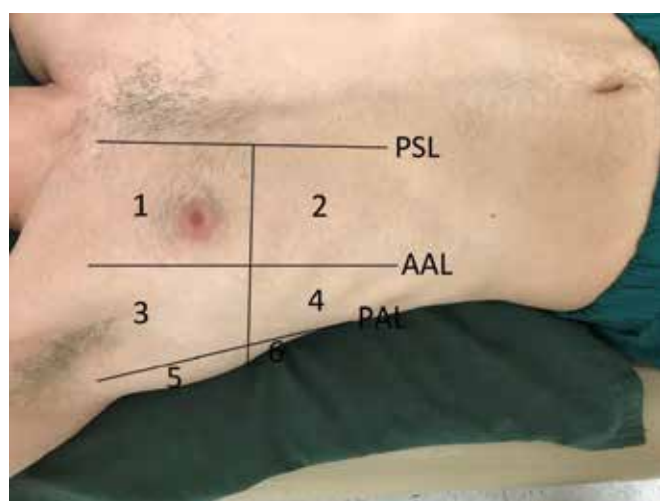


Figure 1. Chest segments in lung ultrasound
AAL: Anterior axillary line, PAL: posterior axillary line, PSL: parasternal line

CT images were reviewed by a radiologist with 9 years of experience in interpreting thorax CT imaging (FC), on a PACS imaging workstation (Infinitt PACS; Infinitt Healthcare, Seoul, Korea).

As in the ultrasound evaluation, each lung was divided into anterior, lateral and posterior quadrants based on the anterior and posterior axillary lines, and then each quadrant was divided into upper and lower sections. Each quadrant was scored between 0-3. It was scored 0 when there was no parenchymal involvement, 1 score when the parenchymal involvement rate was between 0 and 33%, 2 score when it was between 33% and 66%, and 3 score when it was above 66%.

Statistical Analysis

SPSS statistical software package (SPSS, version 17.0 for windows) was used for the statistical analyses and G-power 3 for MacOs program was used for power analysis. Intergroup power analysis between more than two independent groups was performed priori based on the Pearson correlation one tail test, ($q:0,8$; power: $0,8$; alpha error: $0,05$). In order for the total sample size to generate 0.8 power, a total of 46 data (thorax USG and thorax CT) of 23 patients were planned to be included in the study, the distribution of parameters is homogeneous or not was checked with the Kolmogorov – Smirnov test. Parametric tests were used for the data with homogeneous distribution, while nonparametric tests were used for the data with non-normally distribution. Pearson’s correlation test was used to determine whether there is a significant relationship between CT score and LUS score. Results were given as mean \pm standard deviation. A p-value of less than 0.05 was considered statistically significant.

Results

The study included 29 patients with thorax CT and LUS at intensive care admission. The mean age of the patients was 61.93 ± 14.21 years, 37% of them were female. The demographic characteristics of the patients are given in Table 1. Of the 29 patients, 13 died in intensive care. There was no significant difference between the mean age of survived and dead patients (57.6 ± 12.8 vs. 67.3 ± 14.4 ; $p = 0.065$). Regarding the gender distribution, the ratio of males was higher among the survived patients, and the ratio of females was higher among the patients who died (0.018). There was no difference between the two groups in terms of BMI,

length of stay in the intensive care unit and co-morbidities (Table 1).

Of the survived patients, 5 were followed up with high flow nasal oxygen (HFNO), 8 with non-invasive mechanical ventilation (NIMV) and 3 with invasive mechanical ventilation (IMV). Of the patients who died, 3 were followed with HFNO, 8 with NIMV and 2 with IMV. A strong positive correlation was found between thorax CT score and LUS score ($r = 0.964$; $p < 0.001$) (Figure 2). The thorax CT score of the survivors was 15.5 ± 2.7 , and the LUS score was 27.3 ± 4.9 . The thorax CT score of those who died was 14.1 ± 3.4 , and the LUS score was 25.6 ± 5.8 . No significant difference was found between the two groups in terms of thorax CT score and LUS score (Table 2).

Discussion

In the study, the correlation of LUS with CT score and its role in determining mortality was evaluated in patients requiring intensive care follow-up due to COVID-19 pneumonia. As a result of the study, a strong positive correlation was found between thorax CT score and LUS score, but it was found that the thorax CT score and LUS score were not effective in determining mortality.

Poggiali et al (13). reported that there was a strong harmony between thorax CT and simultaneous LUS in COVID-19 patients presenting with flu-like symptoms.

The authors of this study suggested the use of LUS as an alternative to thorax CT for early diagnosis of COVID-19 infection. Yin et al. (14). showed that there was a significant correlation between higher LUS score and 28-day increase in mortality in 175 patients admitted to the intensive care unit in their study. In our study, no significant correlation was found between thorax CT score and LUS score and the mortality of patients with severe COVID-19 pneumonia. We thought it might be depending on our less number of patients.

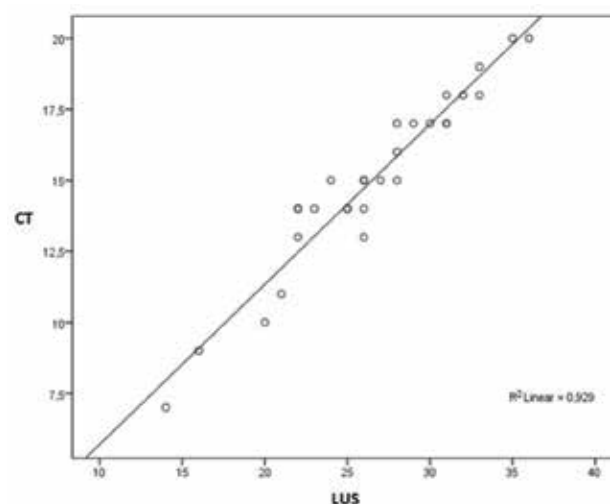


Figure 2. Correlation of thorax CT and LUS scores. There is a strong positive correlation between CT and LUS scorings. ($r=0.964$; $p=0.001$)

Table 1. comparison of demographic and clinical data			
	Group 1 (survivors) (n=16)	Group 2 (non-survivors) (n=13)	p-value
Age	57.6±12.8	67.3±14.4	0.065
Gender (M/F)	13/3	5/8	0.018
BMI	29.7±7.3	33.5±6.8	0.164
Duration of ICU stay (days)	13.2±8.5	11.5±8.9	0.602
Co-morbidite (exist/not exist)	12/4	11/2	0.525
Ventilation (n)			
*HFNO	5	3	0.689
†NIMV	8	8	
‡IMV	3	2	

* High Flow Nasal Oxygen, †Non-invasive Mechanical Ventilation, ‡Invasive Mechanical Ventilation

Table 2. Comparison of survivors and non-survivors CT and LUS scorings			
	Group 1 (survivors) (n=16)	Group 2 (non-survivors) (n=13)	p-value
CT score	15.5±2.7	14.1±3.4	0.244
LUS score	27.3±4.9	25.6±5.8	0.401

LUS is increasingly used as a reliable tool for evaluating lung diseases, especially in intensive care. Since COVID-19 pneumonia lesions are predominantly peripheral and subpleural, the use of LUS is more appropriate (5). Typical patterns detected by LUS are characterized by both split (figure 3) and combined B-lines of different shapes (figure 4), irregular and/or split pleural line, peripheral small consolidations (figure 5), and large consolidations with dynamic air bronchograms (15, 16). These patterns are often interleaved with “protected areas” (A-lines) (17). A large pleural effusion is not a common finding (15). Yasukawa K. et al. (8) evaluated the LUS findings of 10 patients who presented to the Internal Medicine Department with COVID-19, and all patients had thick irregular pleural lines and converging B lines. They reported small subpleural consolidations in five of 10 patients. Peng et al. (18) reported the recurrence of A lines following treatment. They recommended the use of ultrasound to

assess critical treatment response and prognosis prior to the COVID-19 outbreak, that their recurrence indicates a reduction in interstitial infiltration. In our study, abnormal LUS findings, mainly B-lines, consolidation, and pleural line abnormalities were found in patients infected with COVID-19 pneumonia. Bilateral involvement was observed with a dominant distribution in the posterior segment of the lungs. The composition of the different B-lines density and areas of consolidation varied in parallel with clinical severity.

NIMV, HFNO, continuous positive airway pressure devices (CPAP) and IMV were used for the intensive care treatment of COVID-19 pneumonia (18-19). In our study, 16 of 29 patients were followed with NIMV, 8 with HFNO and 5 with IMV, daily lung examinations were performed with USG and treatment was planned. LUS is used for PEEP titration, changing ventilation parameters, and extubation planning (24-25). In their study, Schultz et al. (9) stated that the follow-up of patients with a diagnosis of COVID-19 under invasive mechanical ventilation could be performed with LUS as an easy bedside tool. Bouhemad et al. (20) demonstrated the significance of LUS in determining ventilator settings by recruitment with PEEP. With the repeated LUS and scoring system, it made it possible to follow up the lung pathology.

The significance of lung imaging in areas affected by the COVID-19 outbreak was reported by Ai et al. (21). stating that 60-93% of patients had positive thorax CT findings consistent with COVID-19 before RT - PCR results turn positive. In a study by Kalafat et al. (22), they found positive LUS findings consistent with COVID-19 pneumonia in a woman who initially had a negative RT-PCR result. They reported that the patient, whose RT-PCR tests were negative

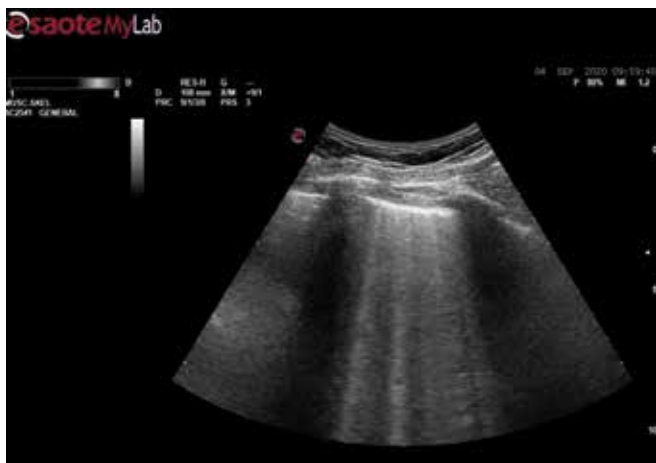

Figure 3. Lung ultrasound shows multiple B-lines

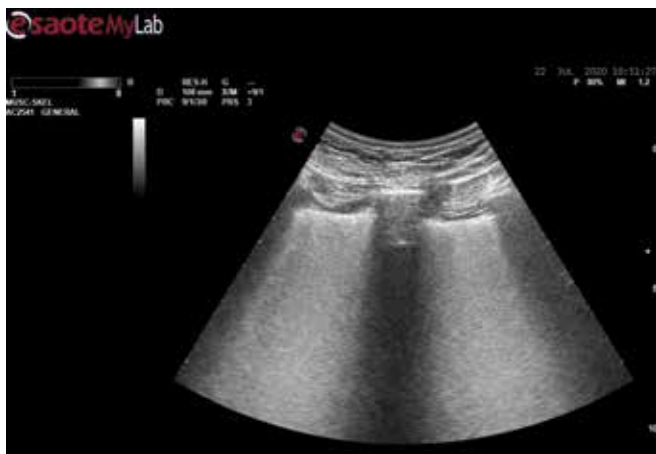

Figure 4. Lung ultrasound shows confluent B-lines

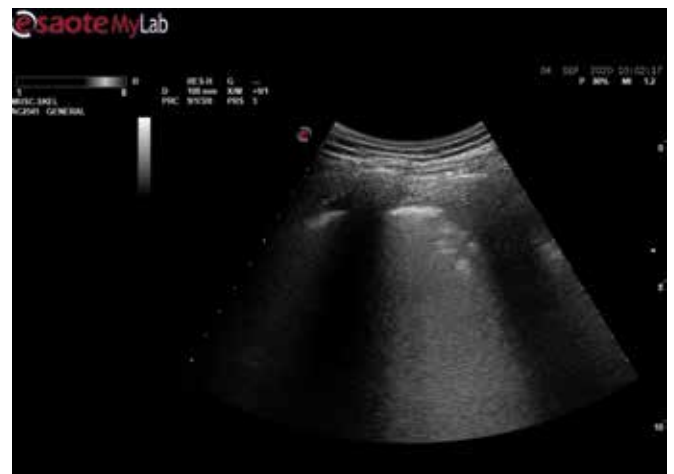

Figure 5. Lung ultrasound shows small subpleural consolidation

and positive in the repeated follow-up, correlated with the LUS score and CT score. The study by Yasukawa et al. (8) showed that LUS was a promising additional lung imaging tool in COVID-19 pneumonia, especially in environments with limited resources. LUS was easy to perform in our study, and therefore it guided us in the triage of the patient suspected of having COVID-19 pneumonia.

In their study, Pan et al (23). followed up lung involvement by performing multiple thorax CT scans at different times (at least three). Ai. et al. (21) concluded in their study that multiple RT-PCR assays and serial thorax CT scans had high sensitivity for the diagnosis of COVID-19. CT has been used predominantly for the diagnosis of COVID-19; however, limitations such as radiation exposure, limited mobility, and expensive devices may limit its usefulness, especially during emergencies with insufficient medical resources. Vetrugno et al. (24) stated in their study that they achieved a significant reduction using chest X-rays and CT scans during this pandemic with LUS, which helped them perform the care and management of their patients a little more efficient.

Considering its sensitivity, portability, and safety, LUS is the preferred imaging modality to aid in the early diagnosis and evaluation of COVID-19 pneumonia. In addition, ultrasound is the only imaging technique accessible near patients' beds for timely diagnosis of pulmonary complications and follow-up of disease changes (25).

Considering that approximately 9 to 12% of healthcare workers are infected in light of data from Italy and Spain, the two countries with the highest rate of COVID-19, this is a very important point (9). In our study, the same physician responsible for the patient obtained pulmonary images with with LUS at the bedside, so that the number of healthcare professionals who could be exposed to the virus could be minimized.

Conclusion

Thorax CT is an effective imaging technique used for the diagnosis and follow-up of patients with COVID-19 pneumonia. LUS can assist in the diagnosis of COVID-19 pneumonia in environments with limited resources where chest X-ray, CT, and RT-PCR are not readily available or have a long turnaround time. The strong correlation between LUS score and CT score in patients with COVID-19 pneumonia shows that LUS can be preferred when CT is required. This may provide early detection and intervention for complications, especially during follow-up. The mortality of patients with COVID-19 pneumonia cannot be predicted with thorax CT score and LUS score. Future studies including more patients will shed light on this issue.

Ethics

Ethics Committee Approval: The study was approved by the local Ethics Committee of Gaziosmanpaşa Training and Research Hospital (decision no: 87, date: 28.05.2020).

Informed Consent: Written informed consent was obtained from the patients to be included in the study and/or their relatives.

Peer-review: Externally peer-reviewed.

Authorship Contributions

Concept: A.V., F.Ç., Design: D.G.M., F.Ç., Data Collection and Process: A.V., F.Ç., Analysis or Interpretation: D.G.M., Ü.A.T., Literature Search: D.G.M., Z.S., Writing: A.V.

Conflict of Interest: No conflict of interest was declared by the authors.

Financial Disclosure: The authors declared that this study received no financial support.

References

- Vieira ALS, Junior JMP, Bastos MG. Role of point-of-care ultrasound during the COVID-19 pandemic: our recommendations in the management of dialytic patients. *Ultrasound J.* 2020 Dec; 12: 30.
- Chua F, Armstrong-James D, Desai SR, Barnett J, Kouranos V, Kon OM. The role of CT in case ascertainment and management of COVID-19 pneumonia in the UK: insights from high-incidence regions. *Lancet Respir Med.* 2020;8(5):438-440.
- Yuan M, Yin W, Tao Z, Tan W, Yi Hu. Association of radiologic findings with mortality of patients infected with 2019 novel coronavirus in Wuhan, China. *PLoS One.* 2020; 15(3): e0230548.
- Yoon SH, Lee KH, Kim JY, Lee YK, Ko H, Kim KH, et al. Chest Radiographic and CT Findings of the 2019 Novel Coronavirus Disease (COVID-19): Analysis of Nine Patients Treated in Korea. *Korean J Radiol* 2020 Apr;21:494-500.
- Ye Z, Zhang Y, Wang Y, Huang Z, Song B. Chest CT manifestations of new coronavirus disease 2019 (COVID-19): a pictorial review. *European Radiology* (2020).30:4381-4389
- Huang P, Liu T, Huang L, Liu H, Lei M, Xu W, et al. Use of chest CT in combination with negative RT-PCR assay for the 2019 novel coronavirus but high clinical suspicion. *Radiology* 2020; 295:22-23.
- Xie X, Zhong Z, Zhao W, Zheng C, Wang F, Liu J. Chest CT for Typical Coronavirus Disease 2019 (COVID-19) Pneumonia: Relationship to Negative RT-PCR Testing. *Radiology.* 2020 Aug;296(2):E41-E45.
- Yasukawa K, Minami T. Point-of-Care Lung Ultrasound Findings in Patients with COVID-19 Pneumonia. *Am J Trop Med Hyg.* 2020;102(6):1198-1202.
- Schultz MJ, Sivakorn C, Dondorp AM. Challenges and Opportunities for Lung Ultrasound in Novel Coronavirus Disease (COVID-19). *Am J Trop Med Hyg.* 2020 Jun; 102(6): 1162-1163.
- Drake DH, Bonis MD, Covella M, Agricola E, Zangrillo A, Zimmerman KG, et al. Echocardiography in Pandemic: Front-Line Perspective, Expanding Role of Ultrasound, and Ethics of Resource Allocation. *J Am Soc Echocardiogr.* 2020 Jun; 33(6): 683-689
- Soldati G, Smargiassi A, Inchingolo R, Buonsenso D, Perrone T, Briganti DF, et al. Is There a Role for Lung Ultrasound During the COVID 19 Pandemic?. *J Ultrasound Med.* 2020 Jul;39(7):1459-1462.
- Volpicelli G, Lamorte A, Villén T. What's new in lung ultrasound during the COVID-19 pandemic. *Intensive Care Med.* 2020 Jul;46(7):1445-1448.
- Poggiali E, Dacrema A, Bastoni D, Tinelli V, Demichele E, Ramos PM, et al. Can Lung US Help Critical Care Clinicians in the Early Diagnosis of Novel Coronavirus (COVID-19) Pneumonia?. *Radiology.* 2020 Jun;295(3):E6.
- Yin W, Zou T, Qin Y, Yang J, Li Y, Zeng X, et al. Poor lung ultrasound score in shock patients admitted to the ICU is associated with worse outcome. *BMC Pulm Med.* 2019 Jan 3;19(1):1.
- Peng QY, Wang XT, Zhang LN; Chinese Critical Care Ultrasound Study Group (CCUSG). Findings of lung ultrasonography of novel coronavirus pneumonia during the 2019-2020 epidemic. *Intensive Care Med.* 2020 May;46(5):849-850.
- Sultan LR, Sehgal CM. A Review of Early Experience in Lung Ultrasound in the Diagnosis and Management of COVID-19. *Ultrasound Med Biol.* 2020 Sep; 46(9): 2530-2545.
- Volpicelli G, Gargani L. Sonographic signs and patterns of COVID-19 pneumonia. *Ultrasound J.* 2020;12(1):22.
- Kaya AG, Öz M, Erol S, Çiftçi F, Çiledağ A, Kaya A. High flow nasal cannula in COVID-19: A literature review. *Tuberk Toraks.* July 2020;68(2):168-174
- González-Castro A, Fajardo Campoverde A, Medina A, Alapont VMI. Non-invasive mechanical ventilation and high-flow oxygen therapy in the COVID-19 pandemic: the value of a draw. *Med Intensiva.* 2020 May 4:S0210-5691(20)30156-X.
- Bouhemad B, Brisson H, Le-Guen M, Arbelot C, Lu Q, Roubay JJ. Bedside ultrasound assessment of positive end-expiratory pressure-induced lung recruitment. *Am J Respir Crit Care Med.* 2011 Feb 1;183(3):341-7.
- Ai T, Yang Z, Hou H, Zhan C, Chen C, Lv W, et al. Correlation of Chest CT and RT-PCR Testing for Coronavirus Disease 2019 (COVID-19) in China: A Report of 1014 Cases. *Radiology.* 2020 Aug;296(2):E32-E40.
- Kalafat E, Yaprak E, Cinar G, Varli B, Ozisik S, Uzun C, et al. Lung ultrasound and computed tomographic findings in pregnant woman with COVID-19. *Ultrasound Obstet Gynecol.* 2020 Jun;55(6):835-837.
- Pan F, Ye T, Sun P, Gui S, Liang B, Li L, et al. Time Course of Lung Changes at Chest CT during Recovery from Coronavirus Disease 2019 (COVID-19). *Radiology.* 2020 Jun;295(3):715-721.
- Vetrugno L, Orso D, Deana C, Bassi F, Bove T. COVID-19 Diagnostic Imaging: Caution Need Before the End of the Game. *Acad Radiol.* 2020 Sep;27(9):1331.
- Ji L, Li Y, Cao C, Lv Q, Xie M. Serial bedside lung ultrasonography in a critically ill COVID-19 patient. *QJM.* 2020 Jul 1;113(7):491-493.