Case Report

Eur J Breast Health 2022; 18(1): 94-101
DOI: 10.4274/ejbh.galenos.2021.2021-7-2

Cystic Neutrophilic Granulomatous Mastitis Regression with the Tumor Necrosis Factor-α Inhibitor, Adalimumab

Le Wen Chiu[1], Karen Goodwin[2], Poonam Vohra[3], Erin Amerson[4]

[1]School of Medicine, University of California San Francisco, California, USA
[2]Department of Surgery, University of California San Francisco, California, USA
[3]Department of Pathology, University of California San Francisco, California, USA
[4]Department of Dermatology, University of California San Francisco, California, USA

ABSTRACT

Idiopathic granulomatous mastitis (IGM) is a rare, benign, inflammatory breast disease that primarily affects parous women within a period of five years post-partum. Cystic neutrophilic granulomatous mastitis (CNGM) is clinically identical to IGM, but histopathology demonstrates distinct central lipid vacuoles rimmed by neutrophils with an outer cuff of epithelioid histiocytes/granulomas, with inconsistent presence of Coryneform bacteria within the vacuoles. There is no consensus on the treatment for either IGM or CNGM, which may be managed surgically with wide local excision or mastectomy or medically with antibiotics, steroids, and steroid-sparing immunosuppressive agents. We present a 30-year-old woman with plaque psoriasis and CNGM whose breast symptoms resolved after treatment with the tumor necrosis factor alpha (TNF-α) inhibitor adalimumab, which has not previously been described as a treatment option for CNGM.

Keywords: Cystic neutrophilic granulomatous mastitis, idiopathic granulomatous mastitis, adalimumab, tumor necrosis factor alpha inhibitor, case report

Cite this article as: Chiu L, Goodwin K, Vohra P, Amerson E. Cystic Neutrophilic Granulomatous Mastitis Regression with the Tumor Necrosis Factor-α Inhibitor, Adalimumab. Eur J Breast Health 2022; 18(1): 94-101

Key Points

- Cystic neutrophilic granulomatous mastitis (CNGM) has an identical clinical presentation to idiopathic granulomatous mastitis (IGM)
- IGM and CNGM are managed surgically and/or with antibiotics, steroids, and steroid-sparing immunosuppressives
- Tumor necrosis factor alpha (TNF-α) inhibitors are considered safe and effective as long-term treatment for chronic autoimmune granulomatous diseases, such as inflammatory bowel disease and sarcoidosis
- TNF-α inhibitors may be a potential non-steroidal, non-anti-microbial and non-surgical treatment alternative for refractory IGM and CNGM

Introduction

Idiopathic granulomatous mastitis (IGM) is a rare, benign, inflammatory breast disease, the etiology and management of which are poorly defined in the literature. Patients classically present with a painful, unilateral inflammatory breast mass. Cystic neutrophilic granulomatous mastitis (CNGM) presents identically to IGM. Although no treatment consensus exists, IGM and CNGM may be managed surgically with wide local excision or mastectomy or medically with antibiotics, intralesional or systemic steroids, or other immunosuppressive therapies, such as methotrexate (1-4). Adalimumab is a humanized monoclonal antibody to tumor necrosis factor alpha (TNF-α) that is used to treat a variety of autoimmune conditions, including plaque psoriasis. We describe a case of CNGM that responded to adalimumab prescribed for the patient's comorbid plaque psoriasis. Adalimumab has not previously been reported as a treatment option for CNGM.

Case Presentation

A 30-year-old Hispanic woman presented with a one-week history of a firm, tender mass under the left nipple. She was a gravida 1 para 1, who delivered at age 25 and did not breastfeed. Her medical history was significant for poorly controlled psoriasis, treated latent tuberculosis infection, and a prolactinoma.

Corresponding Author:
Erin Amerson; erin.amerson@ucsf.edu

Received: 19.08.2021
Accepted: 17.10.2021

Physical examination of the left breast revealed a firm, subcutaneous mass measuring 2.5 centimeters at the 9 o'clock position under and medial to the nipple, centered at 1 cm from the nipple. There were no overlying skin changes, although there were psoriatic plaques affecting the skin on both breasts and over 10% of her body surface area. No other masses or nipple discharge were observed.

Ultrasound revealed a heterogeneous, hypoechoic, irregular mass with extension to the skin/nipple (Figure 1a).

A round, isoechoic and hypervascular lesion, less than 1 cm in diameter, was also found within the mass, correlating with the physical exam finding. Given the appearance of an abscess, the patient was started on a course of trimethoprim/sulfamethoxazole.

Aspirate fluid from the mass was sent for culture and revealed moderate *Corynebacterium tuberculostearicum*. However, as the patient felt well after her antibiotic course, she opted for observation only.

About one month later, her symptoms persisted, and the mass had slightly enlarged. Ultrasound-guided vacuum-assisted core needle biopsy revealed sheets of histiocytes and mixed acute and chronic inflammation with granulation tissue formation in a background of a few benign breast lobules. Interspersed granulomas with central neutrophilic abscess formation or large "punched out" spaces were present. The gram stain highlighted gram-positive bacilli within the cystic spaces. In the absence of features suggestive of a more specific etiology, these findings were most consistent with IGM. Specifically, the neutrophilic micro-abscesses within granulomas, in association with punched-out spaces and gram-positive bacilli, were morphologically consistent with CNGM (Figure 2a-d).

The patient elected to try co-managing her psoriasis and CNGM with adalimumab. She injected herself with 40 mg/0.8 mL of adalimumab subcutaneously every 14 days. After one month of treatment, the patient reported her breast pain had resolved, and repeat ultrasound revealed decreased size of the mass (Figure 1b). Her skin significantly improved after treatment with adalimumab, with her psoriasis affecting only about 1% of her body surface area.

During a temporary discontinuation of adalimumab two months later, her breast symptoms recurred. One week after resuming treatment, the breast mass again decreased in size and induration, and her pain and swelling again resolved.

Figure 1a. Ultrasound image of left breast mass after core biopsy, prior to start of treatment (hypoechoic mass measures 26 x 19 x 21 mm)

Discussion and Conclusion

Adalimumab and other TNF-α inhibitors are considered safe and effective as long-term treatment for other chronic autoimmune granulomatous diseases, such as inflammatory bowel disease and sarcoidosis (5). Only one previously published case described successful treatment of IGM with a TNF-α inhibitor (etanercept), in combination with methotrexate (6). The immunological etiopathogenesis of IGM is poorly understood. Investigations are limited to a single study,

Figure 1b. Follow-up ultrasound image of left breast mass 1 month into treatment (hypoechoic mass measures 20 x 11 x 19 mm)

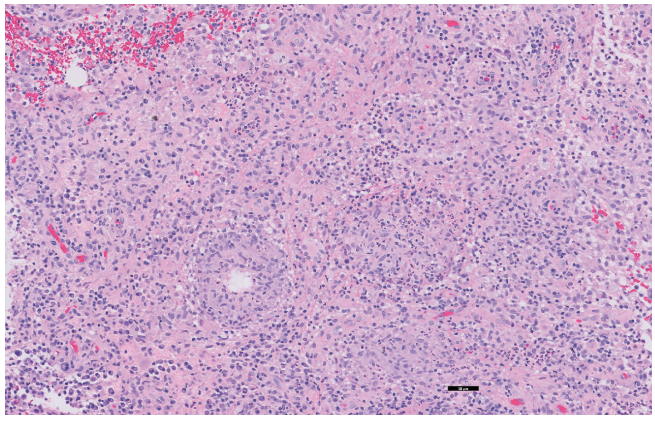

Figure 2a. Non-necrotizing granulomatous inflammation with a mixed inflammatory infiltrate and destruction of lobules (H&E, 200x)

H&E: Hematoxylin and eosin

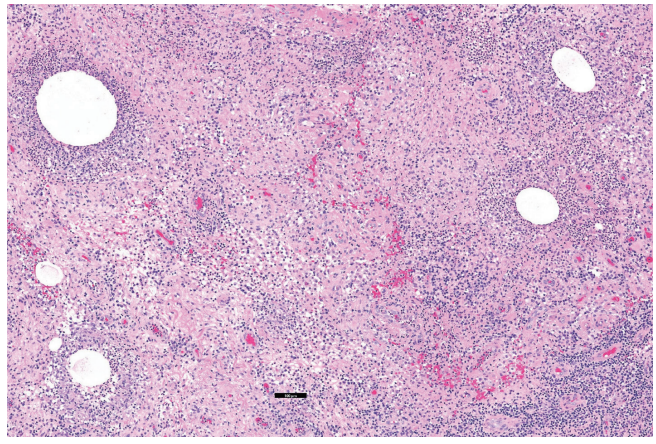

Figure 2b. Granulomatous inflammation with cystic spaces (H&E, 200x)

H&E: Hematoxylin and eosin

which found serum levels of proinflammatory cytokines, such as interleukin-8 (IL-8) and interleukin-17 (IL-17), were elevated in cases of IGM compared with controls (7). While TNF-α levels have not been reported to be significantly higher in patients with IGM or CNGM, other T helper 17/IL-17- driven diseases, such as psoriasis, and diseases exhibiting elevated IL-8 levels, such as rheumatoid arthritis, respond to TNF-α blockade (8). Notably, treatment with adalimumab resolved the CNGM symptoms in our patient without requiring prolonged antibiotic therapy or surgical management, which is associated with high morbidity and recurrence rates (9, 10). TNF-α inhibitors are widely viewed as having a more favorable safety profile than systemic steroids, which are associated with potentially serious sequelae, including weight gain, osteoporosis, hypertension, glucose intolerance, and risk for opportunistic infection. Though further study is needed to determine the efficacy of TNF-α inhibitors in CNGM, their therapeutic potential for this challenging condition is evident.

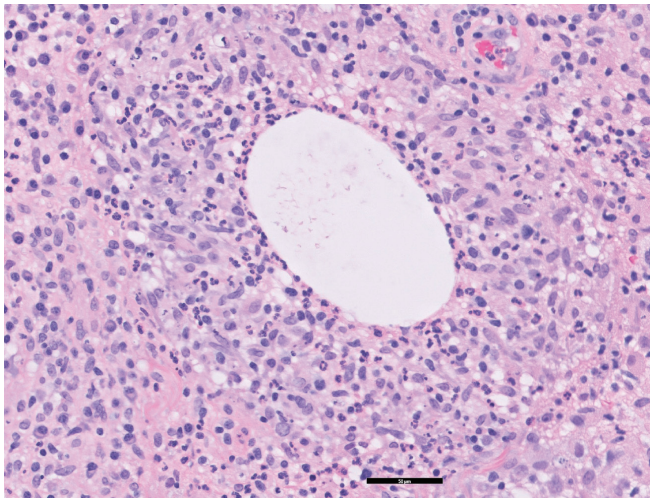

Figure 2c. Cystic vacuoles lined by neutrophils with surrounding histiocytes and lymphocytes (H&E, 400x)

H&E: Hematoxylin and eosin

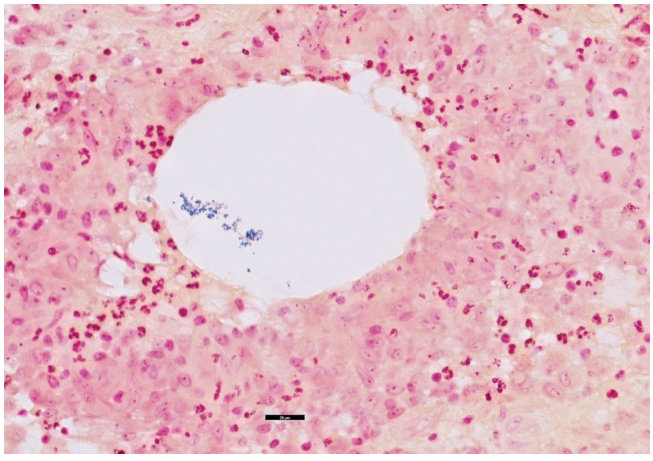

Figure 2d. Gram-positive bacilli with palisaded arrangement typical for *Corynebacterium* species are identified within cystic spaces (Gram stain, 400x)

H&E: Hematoxylin and eosin

While the clinical presentations of IGM and CNGM are indistinguishable, CNGM has been described as a histologically distinct entity characterized by clear spaces/vacuoles rimmed by neutrophils and cuffs of epithelioid histiocytes/granulomas in the background of a mixed inflammatory infiltrate comprised of lymphocytes, giant cells and neutrophils (11). Distinguishing features of CNGM and IGM are summarized in Table 1. CNGM has been reported to be often, but inconsistently, associated with various *Corynebacterium* species (3, 6, 12) with gram-positive rods localized in the clear cystic spaces, which are absent in the non-cystic neutrophilic presentation of IGM (13). Non-diphtheriae *Corynebacterium* species have not been reported to cause adverse systemic sequelae in the setting of TNF blockade.

A summary of published cases describing CNGM is presented in Table 2. Many cases of both IGM and CNGM are treated with variable, serial combinations of surgery, antibiotics, and/or immunosuppression, such as intralesional or systemic steroids or methotrexate (1-4) with one study reporting the protracted clinical course of both to range from 6 to 50 months (3). Some authors have suggested CNGM should be treated with long-term lipophilic antibiotics targeted at *Corynebacterium* spp. (6, 12, 14). However, of 328 cases previously described in the literature, only one report of three patients (12) clearly describes improvement after four weeks or less of tetracycline antibiotics as monotherapy. A recently published report describes 18 patients who improved after an average of seven months on antibiotic monotherapy, the majority of whom received a course of clarithromycin (5). The remaining cases report varying clinical outcomes, from recurrence of mastitis in the contralateral breast (14), to persistent symptoms after antibiotic and surgical management (2, 3, 15), to eventual resolution after combination therapy with empirical antibiotics, immunosuppression, and/or multiple procedures including incision and drainage, lumpectomy, and/or mastectomy (2-4). Many cases of IGM spontaneously resolve without intervention (15). We believe that there are insufficient data to clearly conclude that antibiotics lead to improved outcomes for CNGM compared with other forms of IGM.

Our patient's swift response to adalimumab provides supporting evidence that patients with CNGM may respond to immunosuppression alone, and the distinction between IGM and CNGM may be histopathologic rather than clinical. Our case illustrates the near-immediate improvement of symptoms, compared with an average of 6–8 months reported for improvement of CNGM with antibiotic

Table 1. Features of cystic neutrophilic granulomatous mastitis and idiopathic granulomatous mastitis

Diagnosis	Cystic neutrophilic granulomatous mastitis	Idiopathic granulomatous mastitis
Pathologic findings	Suppurative lipogranulomas comprised of central lipid vacuoles rimmed by neutrophils and an outer cuff of epithelioid histiocytes	Noncaseating granulomatous inflammation, with epithelioid histiocytes, centered on breast lobules, with or without microabscesses
	Some lipid vacuoles may contain Gram-positive bacilli	No lipid vacuoles
		No Gram-positive bacilli
Treatment options	Antibiotic therapy, immunosuppression, surgery	Antibiotic therapy, immunosuppression, surgery

Table 2. Summary of case reports describing CNGM

Diagnosis	Authors, year	Number of cases	Clinical features	Histopathologic features	Treatment	Time from treatment to resolution
Granulomatous lobar mastitis	Paviour et al, 2002	24	Breast abscess, mastitis	- Lobule-centered inflammation - Granulomas with an outer cuff of epithelioid histiocytes and giant cells around a central collection of polymorphonuclear leukocytes (PMNs) surrounding an empty space - Coryneform Gram-positive bacilli within the empty spaces surrounded by PMNs	- Surgery (incision and drainage, biopsy, excision, aspiration) - Antibiotics (penicillin, doxycycline, unspecified)	Unknown
Granulomatous mastitis (GM)	Taylor et al, 2003	34	Fever, neutrophilia, unilateral and bilateral nipple inversion, nipple discharge, sinus formation	- Suppurative lipogranulomas with microabscesses outside of the granulomas - Coryneform bacteria confined to empty spaces, which were surrounded by numerous neutrophils	- Surgery (excisional, drainage procedure) - Antibiotics (unspecified) - Immunosuppression (steroids)	Unknown
Cystic neutrophilic granulomatous mastitis (CNGM)	Renshaw et al, 2011	3	Breast mass, erythematous and indurated mass, breast abscess	- Neutrophilic inflammation with cystic spaces and granulation tissue - Gram-positive bacilli in a single cystic space	- Surgery (debridement, biopsy) - Antibiotics (tetracycline, doxycycline)	2 to 4 weeks
CNGM	D'Alfonso et al, 2015	12	Palpable, tender breast mass with skin erythema, persistent abscess, nipple inversion, breast firmness, swelling, draining sinus	- Lobulocentric granulomas with epithelioid histiocytes, Langhans giant cells, lymphocytes, plasma cells, and neutrophils - Clear vacuoles in the center of granulomas, surrounded by neutrophils	- Surgery (incision and drainage, excision, biopsy) - Antibiotics (cephalexin, ciprofloxacin, doxycycline, vancomycin, trimethoprim-sulfamethoxazole, amoxicillin/clavulanate, tetracycline) - Immunosuppression (prednisone)	2 weeks to 6 months
CNGM	Troxell et al, 2016	19	Unknown	- Clear space, surrounded by a rim of neutrophils, surrounded by granulomatous inflammation - Lobular and periductal involvement	- Surgery (aspiration, excision, incision and drainage, biopsy, mastectomy) - Antibiotics (daptomycin, vancomycin, ceftriaxone, cephalexin, dicloxacillin, amoxicillin-clavulanate, trimethoprim-sulfamethoxazole, metronidazole, moxifloxacin, ciprofloxacin, clindamycin, tetracycline, doxycycline) - Immunosuppression (steroids)	6 to 50 months
CNGM	Helal et al, 2016	35	Breast mass with or without skin ulceration, inflammation, or sinus formation	- Noncaseating granulomas on lobules - Cystic vacuoles in the center of the granuloma rimmed by neutrophils	- Unknown	Unknown

Table 2. Continued

Diagnosis	Authors, year	Number of cases	Clinical features	Histopathologic features	Treatment	Time from treatment to resolution
CNGM	Johnstone et al, 2017	15	Unilateral and bilateral breast mass	- Granulomatous inflammation centered on vacuolated spaces surrounded by neutrophils in a background of neutrophils, plasma cells, lymphocytes, and eosinophils - Gram-positive organisms within vacuolated spaces	- Surgery (lumpectomy, biopsy) - Antibiotics (β-lactams, flucloxacillin, doxycycline, clindamycin, rifampicin, clarithromycin, trimethoprim-sulfamethoxazole, isoniazid)	Unknown
CNGM	Shoyele et al, 2018	7	Tender breast mass, nipple discharge, ipsilateral axillary lymphadenopathy	- Non-necrotizing granulomatous inflammation with neutrophilic microabscesses surrounding clear cystic/vacuolated spaces, admixed with plasma cells, eosinophils, and lymphocytes - Gram-positive bacilli within clear cystic spaces surrounded by neutrophilic microabscesses, surrounded by epithelioid granulomas	- Surgery (incision and drainage, biopsy, excision) - Antibiotics (minocycline, cefuroxime, dalbavancin, daptomycin) - Immunosuppression (steroids, hydroxychloroquine, methotrexate) - Topical anti-inflammatory agent	6 to 11 months
CNGM	Wang et al, 2018	1	Tender breast mass	- Neutrophilic inflammatory infiltrate with lipogranulomas in a lobulocentric distribution - Cystic spaces lined by a cuff of neutrophils - Gram-positive cocci within and at the edge of cystic spaces	- Unknown	Unknown
CNGM	Patel et al, 2018	7	Palpable, painful mass, draining sinus	- Epithelioid histiocytes, multinucleated giant cells, and granulomas with cystic spaces	- Surgery (biopsy) - Antibiotics (unspecified)	Unknown
CNGM	Gautham et al, 2019	6	Painful palpable mass, cutaneous erythema, nipple discharge, abscess	- Large expanses of mononuclear inflammatory cells with histiocytes and focal well-formed granulomata - Neutrophil invested microcysts, with and without Gram-positive bacilli within	- Antibiotics (cephalexin, trimethoprim/sulfamethoxazole, doxycycline, daptomycin, dicloxacillin, vancomycin, piperacillin, tazobactam, ciprofloxacin, clindamycin) - Corticosteroids (high dose parenteral steroids and low-dose oral therapy)	2 to 13 months
CNGM	Maung et al, 2020	12	Painful breast mass, isolated breast pain, palpable breast mass	- Neutrophilic and granulomatous inflammation surrounding clear cystic spaces	- Surgery (biopsy, excision, lumpectomy, incision and drainage, mastectomy) - Antibiotics (doxycycline, vancomycin, penicillin V, cephalexin, clindamycin, cefazolin, amoxicillin/clavulanic acid)	Unknown

Table 2. Continued

Diagnosis	Authors, year	Number of cases	Clinical features	Histopathologic features	Treatment	Time from treatment to resolution
CNGM	Naik et al, 2020	24	Painful breast mass, retracted nipples, nipple discharge, multiple sinuses	- Lobular inflammation in solid lesions, with clear spaces rimmed by neutrophils surrounded by epithelioid cells, lymphocytes, plasma cells, histiocytes, and giant cells - Abscess cavities filled with sheets of neutrophils rimmed by granulomatous inflammation with cystic spaces	- Surgery (lumpectomy, bilateral mastectomy) - Antibiotics (amoxicillin/clavulanic acid, doxycycline, cefotaxime, amikacin)	1 to 6 months
CNGM	Sangoi, 2020	19	Mass, abscess	- Organizing epithelioid histiocytes with intimately admixed neutrophils rimming discrete cystic spaces - Gram-positive bacilli restricted to the cystic spaces	- Surgery (biopsy, excision) - Other treatments unknown	Unknown
CNGM	Patel and Hoda, 2020	1	Unilateral breast pain and central breast swelling	- Multiple suppurative lipogranulomata with round cysts lined by neutrophils with a cuff of epithelioid histiocytes admixed with lymphocytes, plasma cells, and multinucleated giant cells - Some vacuoles with rare Gram-positive bacilli	- Surgery (excision) - Antibiotics (tetracycline)	Unknown
CNGM	Chalmers et al, 2020	1	Unilateral breast pain, swelling, chills, night sweats, skin changes, mass	- Granulomatous inflammation of the lobules with well-formed granulomas and multinucleated giant cells - No bacterial organisms on Gram or Acid-Fast Bacilli stains	- Surgery (incision and drainage, biopsy - Antibiotics (trimethoprim-sulfamethoxazole, moxifloxacin) - Immunosuppression (methylprednisolone, prednisone)	Improved at 6 months but not resolved
CNGM	Tan et al, 2021	1	Unilateral, tender breast mass with edema	- Extensive mixed chronic inflammation centered around lobules - Neutrophils arranged around microcystic lipid spaces, some of which contained Gram-positive bacterial organisms	- Surgery (biopsy, aspiration) - Antibiotics (cephalexin)	Improved after 2 weeks but recurred
CNGM	Patel et al, 2021	1	Unilateral breast swelling, pain, fever, generalized malaise, decreased appetite	- Periductal and perilobular inflammation consisting of lymphocytes, plasma cells, polymorphs, foamy macrophages, histiocytes, Langhans' type of giant cells with acid-fast bacilli - Cystic spaces surrounded by neutrophilic aggregates	- Surgery (incision and drainage) - Antibiotics (anti-tubercular therapy, clarithromycin, amikacin)	6 months

Table 2. Continued

Diagnosis	Authors, year	Number of cases	Clinical features	Histopathologic features	Treatment	Time from treatment to resolution
CNGM	Li et al, 2021	31	Breast mass, pain, abscess, fistula, erythema, nipple retraction, swelling	- Cystic vacuoles encircled by varying numbers of neutrophils in the setting of granuloma and inflammation - Gram-positive bacilli within vacuoles	- Surgery (incision and drainage) - Antibiotics (targeting Corynebacterium kroppenstedtii) - Immunosuppression (corticosteroid)	Unknown
GM	Williams et al, 2021	36	Breast mass or lump, pain or tenderness, erythema	- Lobulocentric active granulomatous inflammation with or without chronic inflammation and no evidence of malignancy - Associated abscess, fat necrosis, stromal fibrosis - Diphtheroids (presumptive Corynebacterium species) commonly identified	- Surgery (incision and drainage, aspiration, excision) - Antibiotics (clarithromycin, macrolides) - Immunosuppression (prednisone)	8 months
CNGM	Tariq et al, 2021	38	Palpable painful breast mass, erythema of the skin overlying, nipple inversion and discharge	- Clear spaces surrounded by a rim of neutrophils, further surrounded by histiocyte-rich granulomatous inflammation - Rare Gram-positive bacteria exclusively inside cystic spaces	- Unknown	2 weeks to 1 year
CNGM	Wang et al, 2021	1	Painful palpable breast mass and worsening open lesions	- Lobulocentric granulomas with mixed inflammation and central cystic spaces lined by neutrophils containing Corynebacterium species	- Surgery (biopsy) - Antibiotics (β-lactams)	Unknown

CNGM: Cystic neutrophilic granulomatous mastitis

therapy in some reports (2, 13). The patient's symptoms recurred after a brief interruption of her adalimumab, then rapidly (one week) improved again with reintroduction of the drug, indicating that the adalimumab was controlling her symptoms, rather than representing a case of spontaneous resolution that happened to coincide with introduction of therapy. This robust response to adalimumab suggests that TNF-α inhibitors should be further explored as a potential non-steroidal, non-antimicrobial and non-surgical, well-tolerated treatment alternative for IGM and CNGM to alleviate symptoms until spontaneous resolution occurs.

The treatment of CNGM remains therapeutically challenging, given the absence of consistent response to surgical or medical treatment. Adalimumab or other TNF-α inhibitors may provide a novel therapeutic approach for refractory IGM or CNGM.

Informed Consent: It was obtained from the patient.

Peer-review: Externally peer-reviewed.

Authorship Contributions

Surgical and/or Medical Practices: L.C., K.G., P.V., E.A.; Concept: E.A.; Design: E.A.; Data Collection and/or Processing: L.C., K.G., P.V., E.A.; Analysis and/or Interpretation: L.C., E.A.; Literature Search: L.C., K.G., P.V., E.A.; Writing: L.C., K.G., P.V., E.A.

Conflict of Interest: No conflict of interest declared by the authors.

Financial Disclosure: The authors declare that this study received no financial disclosure.

References

1. Postolova A, Troxell ML, Wapnir IL, Genovese MC. Methotrexate in the treatment of idiopathic granulomatous mastitis. J Rheumatol 2020; 47: 924-927. (PMID: 31203215) [CrossRef]
2. Shoyele O, Vidhun R, Dodge J, Cheng Z, Margules R, Nee P, et al. Cystic neutrophilic granulomatous mastitis: a clinicopathologic study of a distinct entity with supporting evidence of a role for Corynebacterium-targeted therapy. Ann Diagn Pathol 2018; 37: 51-56. (PMID: 30248572) [CrossRef]
3. Troxell ML, Gordon NT, Doggett JS, Ballard M, Vetto JT, Pommier RF, et al. Cystic neutrophilic granulomatous mastitis: association with gram-positive bacilli and Corynebacterium. Am J Clin Pathol 2016; 145: 635-645. (PMID: 27247368) [CrossRef]
4. D'Alfonso TM, Moo TA, Arleo EK, Cheng E, Antonio LB, Hoda SA. Cystic neutrophilic granulomatous mastitis: further characterization of a distinctive histopathologic entity not always demonstrably attributable to Corynebacterium infection. Am J Surg Pathol 2015; 39: 1440-1447. (PMID: 26200100) [CrossRef]
5. Williams MS, McClintock AH, Bourassa L, Laya MB. Treatment of granulomatous mastitis: is there a role for antibiotics? Eur J Breast Heal 2021; 17: 239-246. (PMID: 34263151) [CrossRef]
6. Wang ST, Lin JC, Li CF, Lee YH. A successful case of etanercept used for idiopathic granulomatous mastitis. Breast J 2019; 25: 343-345. (PMID: 30790374) [CrossRef]
7. Koksal H, Vatansev H, Artac H, Kadoglou N. The clinical value of interleukins-8, -10, and -17 in idiopathic granulomatous mastitis. Clin Rheumatol 2020; 39: 1671-1677. (PMID: 31916110) [CrossRef]
8. Zaba LC, Suárez-Fariñas M, Fuentes-Duculan J, Nograles KE, Guttman-Yassky E, Cardinale I, et al. Effective treatment of psoriasis with etanercept is linked to suppression of IL-17 signaling, not immediate response TNF genes. J Allergy Clin Immunol 2009; 124: 1022-10.e1-395. (PMID: 19895991) [CrossRef]
9. Zhou F, Liu L, Liu L, Yu L, Wang F, Xiang Y, et al. Comparison of conservative versus surgical treatment protocols in treating idiopathic granulomatous mastitis: a meta-analysis. Breast Care 2020; 15: 415-420. (PMID: 32982653) [CrossRef]
10. Shin YD, Park SS, Song YJ, Son SM, Choi YJ. Is surgical excision necessary for the treatment of granulomatous lobular mastitis? BMC Womens Health 2017; 17: 49. (PMID: 28738795) [CrossRef]
11. Wu JM, Turashvili G. Cystic neutrophilic granulomatous mastitis: an update. J Clin Pathol 2020; 73: 445-453. (PMID: 32094275) [CrossRef]
12. Renshaw AA, Derhagopian RP, Gould EW. Cystic neutrophilic granulomatous mastitis: an underappreciated pattern strongly associated with gram-positive bacilli. Am J Clin Pathol 2011; 136: 424-427. (PMID: 21846918) [CrossRef]
13. Gautham I, Radford DM, Kovacs CS, Calhoun BC, Procop GW, Shepardson LB, et al. Cystic neutrophilic granulomatous mastitis: the Cleveland Clinic experience with diagnosis and management. Breast J 2019; 25: 80-85. (PMID: 30449049) [CrossRef]
14. Maung MH, Bethune GC, Patriquin G, Barnes PJ. Cystic neutrophilic granulomatous mastitis – a review of 12 consecutive cases. Histopathology 2020; 77: 781-787. (PMID: 32557756) [CrossRef]
15. Bouton ME, Jayaram L, O'Neill PJ, Hsu C-H, Komenaka IK. Management of idiopathic granulomatous mastitis with observation. Am J Surg 2015; 210: 258-262. (PMID: 25746911) [CrossRef]