



# Quadrivial Right Upper Lobe on Bronchoscopy for One Lung Ventilation

Chanchal Mangla , Akshata Kamath , Joel Yarmush 

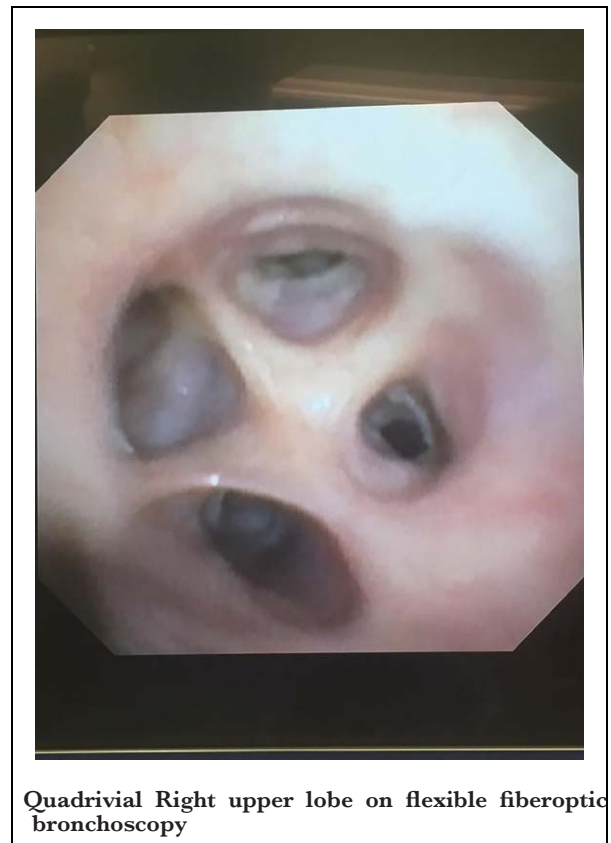
Department of Anesthesiology, New York Presbyterian Brooklyn Methodist Hospital, Brooklyn, NY, USA

**Cite this article as:** Mangla C, Kamath A, Yarmush J. Quadrivial Right Upper Lobe on Bronchoscopy for One Lung Ventilation. *Turk J Anaesth Reanim.* 2021;49(3):271-272.

We found the right upper lobe of the lung to be quadrivial on flexible fiberoptic bronchoscopy used for confirmation of the double lumen tube for two patients. Position of right upper lobe was normal.

It is very important for anaesthesiologists to have knowledge of the variations of tracheobronchial tree for successful placement of lung isolation devices. Fiberoptic bronchoscope guided confirmation is considered as gold standard for placement of double lumen tube.<sup>1</sup> Though if it is not available, intubation can be verified by clinical manoeuvres, but chances of misplacement and complications are high.<sup>1</sup> Right upper lobe is an important landmark on the fibre-optic bronchoscopic confirmation. Right upper lobe normally divides into three segmental bronchus. Variations in bronchial tree are mostly due to displacement of segmental or subsegmental bronchi.<sup>2</sup> Bronchial variations are more common on the right side.<sup>3</sup> Most common variation in the right upper lobe is the bifurcate pattern followed by quadrivial.<sup>1</sup> At times, when there is no fibre-optic bronchoscope available, unfortunately, these variations will be missed.

Bronchus to the right upper lobe is called as eparterial bronchus. The mode of branching of eparterial bronchus may vary, with most common being three divisions—apical, anterior and posterior segmental bronchi. According to Foster-Carter, in around 10% of cases, the fourth subdivision may arise from either anterior or posterior division, and it arises so close to the eparterial trunk that it appears as a separate branch supplying axillary segment of the right upper lobe.<sup>4</sup>



**Quadrivial Right upper lobe on flexible fiberoptic bronchoscopy**

## Main Points

- Quadrivial Right upper lobe is an uncommon variation of the Right upper lobe of the lung.
- Knowledge of the branching of bronchial tree is very important for an Anesthesiologist for correct placement of double lumen tube.
- We present an image of the quadrivial right upper lobe bronchus on fiberoptic bronchoscopy done on a patient for confirmation of double lumen tube placement.

**Ethics Committee Approval:** N/A

**Informed Consent:** Informed consent was obtained from the patient who participated in this study.

**Peer-review:** Externally peer-reviewed.

**Author Contributions:** Concept - C.M.; Design - C.M., A.K.; Materials - C.M., A.K.; Data Collection - C.M.; Analysis and Interpretation - C.M.; Literature Search - C.M.; Writing - C.M., A.K.; Critical Review - C.M., A.K., J.Y.

**Conflict of Interest:** The authors have no conflicts of interest to declare.

**Financial Disclosure:** The authors declared that this study has received no financial support.

## References

1. De Bellis M, Accardo R, Di Maio M, et al. Is flexible bronchoscopy necessary to confirm the position of double-lumen tubes before thoracic surgery? *Eur J Cardio-Thoracic Surg.* 2011;40(4):912-918. [\[CrossRef\]](#)
2. Gonlugur U, Efeoglu T, Kaptanoglu M, Akkurt I. Major anatomical variations of the tracheobronchial tree: Bronchoscopic observation. *Anat Sci Int.* 2005;80:111-115. [\[CrossRef\]](#)
3. Conci DI. Quadri-lobed pattern of division in the right upper lobe: The axillary bronchus. *J Bronchol Intervent Pulmonol.* 2014;21(2):182-183. [\[CrossRef\]](#)
4. Foster-Carter AF. The anatomy of the bronchial tree. *Br J Tuberc.* 1942;36(1):19-38. [\[CrossRef\]](#)