



Management of an Iatrogenic Foreign Body in a Neonate: Another Use of C-MAC® Video Laryngoscope!

Anju Gupta¹ , Nishkarsh Gupta² 

¹Department of Anaesthesiology and Intensive care, VMMC and Safdarjung Hospital, New Delhi, India

²Department of Onco-Anaesthesiology and Palliative Medicine, DRBRAIRCH, AIIMS, New Delhi, India

Cite this article as: Gupta A, Gupta N. Management of an Iatrogenic Foreign Body in a Neonate: Another Use of C-MAC® Video Laryngoscope! Turk J Anaesthesiol Reanim 2020; 48(2): 172-3.

Dear Editor,

A 1-day-old male baby weighing 2.3 kg was diagnosed with anorectal malformation with tracheoesophageal fistula (TEF) after clinical examination and imaging studies. Colostomy and TEF repair were scheduled after initial stabilisation. Systemic examination and investigation findings were unremarkable. The trachea was intubated using a 3.0-mm ID uncuffed polyvinyl chloride (PVC) endotracheal tube following anaesthesia induction with thiopentone and neuromuscular blockade with rocuronium. Initially, colostomy was performed in the supine position. The baby was then turned into the lateral decubitus position for the surgery, following which the surgeons inserted a 9-Fr red rubber catheter into the oesophageal pouch. However, during insertion, the catheter broke off, and its distal end was left inside the oesophageal pouch. The patient was turned supine and direct laryngoscopy with a Miller blade performed, but the broken piece could not be located despite a lot of effort. At this stage, a C-MAC® Miller blade, size 0, was inserted, and the distal catheter end was seen lying in the hypopharynx (Figure 1a-c). The larynx and pharynx were carefully examined to confirm any other retained piece. When the remaining catheter was observed, it was also found to be quite friable and easily broke down into multiple pieces.

Tracheoesophageal fistula is one of the most common congenital anomalies for which emergency surgical correction is required in a neonate. The surgical approach is through right thoracotomy in the lateral decubitus position. For intraoperative identification of the upper oesophageal pouch, a feeding tube (PVC/red rubber) is generally inserted orally into the pouch. In the present case, the red rubber catheter was purchased from outside, and it did not bear the name of the manufacturer and the expiry date. Presumably, a manufacturing defect, low-quality material used in catheter construction or an expired product led to this complication. On searching literature, we could not find any similar report. One previous report on a preterm infant undergoing TEF repair described iatrogenic pneumomediastinum during the passage of an orally inserted 8-Fr feeding tube through the blind upper pouch, as it had created false passage and pierced the hypopharynx (1). Iatrogenic foreign bodies reported in literature include fractured intravenous cannula (2), central ve-

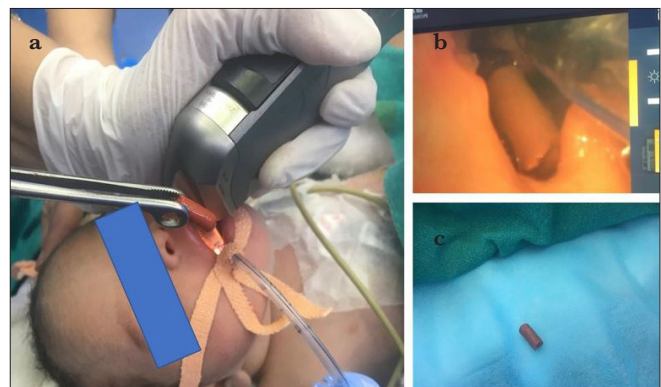


Figure 1. a-c. C-MAC® video laryngoscopy and use of Magill's forceps to remove the distal retained fragment (a). Video laryngoscopy view of the foreign body (b). The removed distal end of the red rubber catheter (c)

nous line, arterial line (3) and epidural catheter (4), generally resulting from a faulty technique or excessive pressure during removal. However, a broken catheter has not been reported previously. Such red rubber catheters are commonly used for oesophageal dilatation in children with oesophageal stenosis and, if broken, may result in unnecessary and potentially dangerous interventions on the child.

Video laryngoscopes provide a non-line-of-sight view, and the high-resolution view provided by CMAC video laryngoscope aided us in locating the iatrogenic foreign body and successfully retrieving it.

We, therefore, advocate early use of a video laryngoscope to manage scenarios where inspection of the upper airway and pharynx is required. Furthermore, prior to using a red rubber catheter, a tensile test should be performed to ensure its strength.

Informed Consent: Written informed consent was obtained from the parents of the patient who participated in this study.

Peer-review: Externally peer-reviewed.

Author Contributions: Concept – A.G., N.G.; Design – A.G., N.G.; Supervision – A.G.; Resources – A.G.; Materials – A.G.; Data

Collection and/or Processing – A.G.; Analysis and/or Interpretation – A.G., N.G.; Literature Search – A.G., N.G.; Writing Manuscript – A.G., N.G.; Critical Review – A.G., N.G.

Conflict of Interest: The authors have no conflicts of interest to declare.

Financial Disclosure: The authors declared that this study has received no financial support.

References

1. Dwivedi D, Makkar J, Sharma R, Jafra A. Pneumomediastinum following iatrogenic pharyngeal perforation during tracheoesophageal fistula repair. *Saudi J Anaesth* 2018; 12: 355-7. [\[CrossRef\]](#)
2. Deep S, Deshpande S, Howe P. Traumatic fracture of central venous catheter resulting in potential migration of distal fragment: a case report. *Cases J* 2008; 1: 394. [\[CrossRef\]](#)
3. Kale SB, Ramalingam S. Spontaneous arterial catheter fracture and embolisation: Unpredicted complication. *Indian J Anaesth* 2017; 61: 505-7. [\[CrossRef\]](#)
4. Lee YH, Hwang HY, Sim WS, Yang M, Lee CJ. Breakage of a thoracic epidural catheter during its removal: A case report. *Korean J Anesthesiol* 2010; 58: 569-72. [\[CrossRef\]](#)