



Multimodal Intraoperative Monitoring During Microsurgical Treatment of Spinal Dural Arteriovenous Fistula

Kadarapura Nanjundaiah Gopalakrishna¹ , Prashanth Menon¹ , Prashant Singh² , Nupur Pruthi² ,
Suparna Bharadwaj¹ 

¹Department of Neuroanaesthesia and Neurocritical Care, National Institute of Mental Health and Neuro Sciences, Bangalore, India

²Department of Neurosurgery, National Institute of Mental Health and Neuro Sciences, Bangalore, India

Cite this article as: Gopalakrishna KN, Menon P, Singh P, Pruthi N, Bharadwaj S. Multimodal Intraoperative Monitoring During Microsurgical Treatment of Spinal Dural Arteriovenous Fistula. *Turk J Anaesthesiol Reanim* 2020; 48(5): 423-6.

Abstract

We report here a case to illustrate the potential intraoperative multimodal monitoring options available for safe ligation of spinal dural arteriovenous fistula (DAVF). The success of microsurgical treatment depends on the correct identification of the arterial feeder and monitoring the functional integrity of the corticospinal tract.

Keywords: Dural arteriovenous fistulas, motor evoked potentials, multimodal monitoring, spinal surgery

Introduction

Spinal dural arteriovenous fistulas (DAVF) are the most common vascular malformations of the spinal cord, but they are still very rare. They are usually observed in elderly men, typically in the thoracolumbar region, and are the treatable causes of progressive paraplegia. The arteriovenous shunt is located inside the dura (relatively close to the spinal nerve root) where the arterial blood from a radicular artery enters a radicular vein. The increase in the spinal venous pressure may lead to decreased drainage of normal spinal veins, resulting in progressive myelopathy. Treatment can either be surgical or by a neuro-endovascular obliteration of the fistula and has a high success rate with a low risk of morbidity (1). Periprocedural neuromonitoring is extremely important for the correct identification of the arterial feeder and monitoring the functional integrity of the corticospinal pathways. We report a case to illustrate the potential intraoperative multimodal monitoring options available for safe ligation of spinal DAVF under general anesthesia (GA).

Case Presentation

A 46-year-old hypertensive male patient presented with bilateral lower limb numbness and weakness for 6 months. On examination, he had a bilateral sensory loss of 60% below L2 level and bilateral motor weakness (motor power at hip 3/5, knee 4/5, and ankle 2/5). Patient had difficulty in walking with restricted activity. Magnetic resonance imaging (MRI) of the dorsolumbar (DL) spine showed hyperintense signals at the dorsal aspects of the cord on T2 weighted images from D7 to L2 levels with prominent signal change at the D10 level. The spinal digital subtraction angiogram (DSA) showed DAVF being fed from the right D10 intercostal artery. Selective injection made through the microcatheter showed the artery of Adamkiewicz arising from the same intercostal vessel. Surgical treatment was preferred over endovascular embolization because it is a relatively safe, easy, and effective method to permanently obliterate the fistula micro-surgically. The D10 - D11 laminectomy and ligation of the spinal DAVF were planned under GA. The induction and maintenance of anesthesia was uneventful. To facilitate neurophysiological monitoring, total intravenous anesthesia with propofol (75-125 mcg kg⁻¹ min⁻¹), dexmedetomidine (0.5 mcg kg⁻¹ min⁻¹), and fentanyl (1 mcg kg⁻¹ hour⁻¹) were used for the maintenance of anesthesia without a muscle relaxant. Initially, we planned to monitor the somatosensory

evoked potentials (SSEP) and motor evoked potentials (MEP). Since SSEP response from the lower limbs yielded no reproducible response, we continued with MEP monitoring. MEP monitoring by transcranial electrical stimulation with a multi-pulse stimulator was done for eliciting the compound motor action potential (CMAP). Transcranial electrical stimulation for MEP was delivered through the corkscrew electrodes placed on the scalp at C1/C2 of the 10-20 international electroencephalogram (EEG) system (2). The stimulation parameters for MEP were trains of 7 square wave stimuli with a frequency of 2 Hz, pulse duration of 0.5 ms, inter-stimulus interval of 4 ms, and intensity of 400-600 V. CMAPs were recorded by placing the needle electrodes in the bilateral abductor hallucis (foot muscle), external oblique (abdominal muscle), and abductor pollicis brevis (hand muscle) muscles for comparison. A relative drop of more than 50% in CMAP amplitude was considered significant for immediate warning (3). In addition, free-running electromyography (EMG) monitoring was recorded from the same muscle groups for monitoring of nerve root irritation or compression. We did not monitor D wave because the lesion was from D7 - L2 level. Distal to L2 would be the cauda equina; the introduction of a D wave catheter, distal to the lesion would not have acquired valuable clinical information.

After durotomy, a cluster of vessels was seen at the D10 level. Single vessel emerging along the D10 nerve root (posterior nerve root) on the right side and supplying the nidus was identified using a temporary clip to the feeding vessel and was confirmed by examining the flow dynamics using an intraoperative doppler and indocyanine green (ICG) videoangiography. Temporary clip was applied over the feeding vessel and ICG/intraoperative doppler was used to show no flow. The clip was removed for a moment and the cluster of vessels was seen to refill with blood. Thus, the feeder vessel was identified and was clipped again for surgical resection of the fistula. Potential irritation or ischemia of the cord due to nerve root compression was monitored by looking for raw EMG. Basal MEP recording was performed before temporary clipping of the feeder vessel, and every 2 minutes for 20 minutes after clipping. Figure 1 shows the MEP response before and after the temporary clipping of the feeding vessel. After temporary clipping, there was a progressive increase in the CMAP amplitude of the foot muscle group till the end of 20 min, but no significant change was observed in that of the abdominal

muscle group (Figure 1). The neurosurgeon micro-surgically coagulated the proximal vessel to achieve the collapse of veins and obliteration of the arterialized vein. After dural closure, MEP signal in the lower limb muscle group improved. Postanesthesia recovery was uneventful. Postoperatively, the lower limb motor strength improved (motor power of 4/5 in the proximal and distal lower limb muscle group) and there was a 25% improvement in the sensory disturbance compared to that in the preoperative status. The functional status was calculated based on the Aminoff-Logue Disability (ALS) Scale (4) (Grade 1- leg weakness or abnormal gait with no restricted activity; Grade 2- leg weakness or abnormal gait with restricted activity; Grade 3- requiring 1 stick for walking; Grade 4- requiring 2 sticks for walking; Grade 5- Unable to stand, confined to bed). According to the ALS scale, there was an improvement in the gait from grade 2 to grade 1 after surgery. The patient was able to walk and was independent in doing daily routine activities in 3 months following treatment.

Discussion

This case scenario demonstrates the utility of multimodal monitoring when handling the complex spinal cord vasculature because of the spinal DAVF. The blood flow through the spinal DAVF causes arterial steal and venous congestion leading to relative spinal cord ischemia. In this scenario, the ischemic damage is incomplete and restoration of normal blood flow by obliteration of the spinal DAVF has a greater chance of recovery of the neurological function. In this case, the spinal angiogram showed the artery of Adamkiewicz arising from the same intercostal vessel supplying the spinal DAVF. The artery of Adamkiewicz supplies anterior two-thirds of the spinal cord. Because of this reason, microsurgical ligation of the fistula was planned with multimodal monitoring instead of endovascular embolization. The microsurgical resection of the spinal DAVF is safe, with a high success rate and relatively no risk of recurrence (5). The success of the surgical treatment under GA depends on the correct identification of the arterial feeder and monitoring the functional integrity of the corticospinal pathways tracked by MEP. Intraoperative identification of the feeder vessel of the spinal DAVF was based on the use of intraoperative doppler and ICG videoangiography, which permits the identification and safe ligation of the feeding artery (6). In addition, intraoperative micro-doppler monitoring can be used to confirm the complete obliteration of the spinal DAVF. The absence of residual flow in the draining vessel confirmed successful treatment (7).

In this case report, there was an improvement in the MEP response of the bilateral lower limbs following the obliteration of the spinal DAVF. In a retrospective study by Ghadirpour et al. (8), patients with improvement in the MEP parameters after temporary and permanent occlusion of the spinal DAVF, had higher chances of postsurgical motor improvement. This demonstrates

Main Points:

- The management of complex spinal cord vasculature due to spinal dural arteriovenous fistulas (DAVF) is challenging.
- The success of microsurgical treatment of spinal DAVF depends on the correct identification of the arterial feeder.
- Multimodal intraoperative monitoring is important for the safe ligation of spinal DAVF.

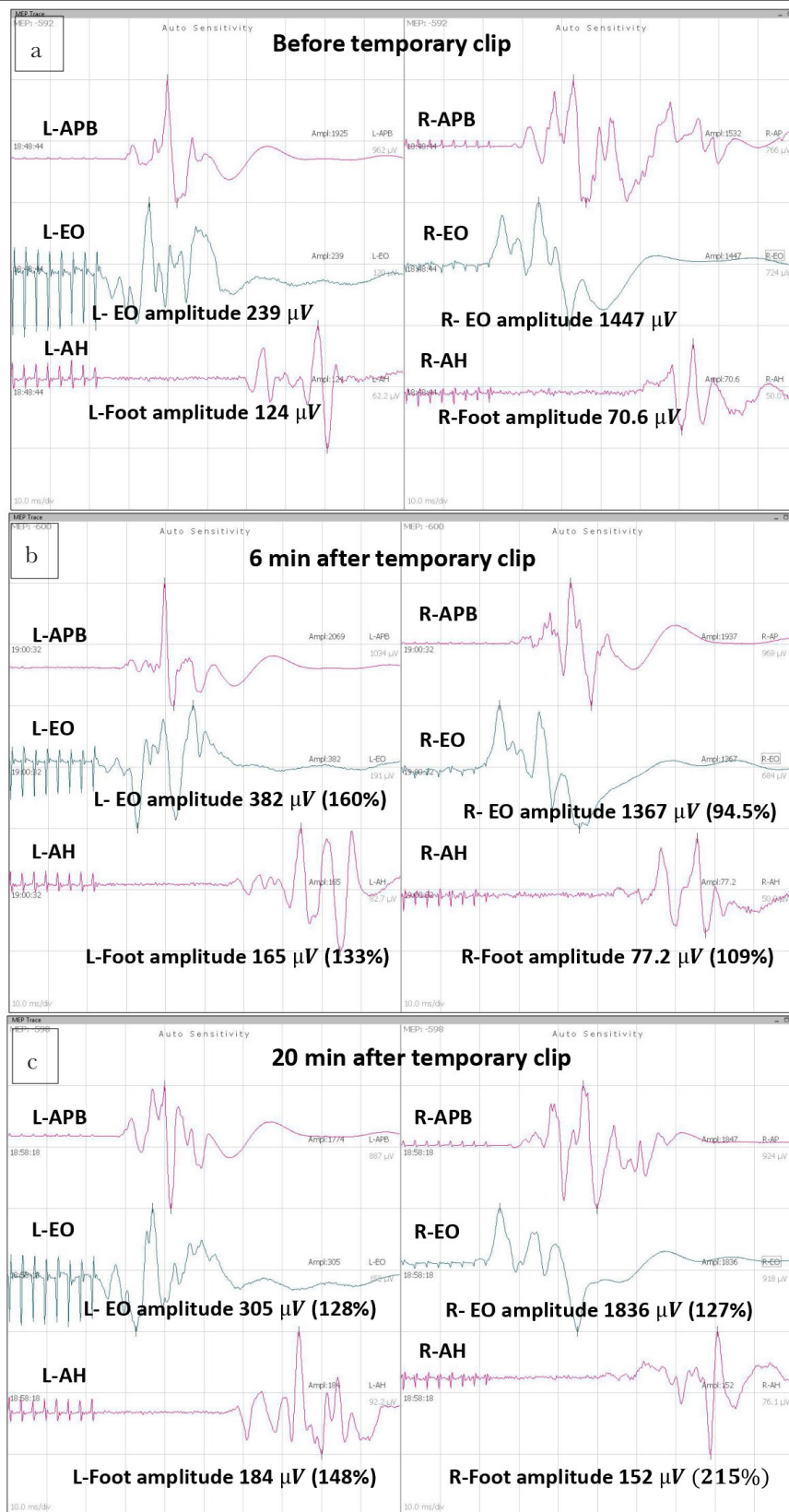


Figure 1. a-c. Muscle motor evoked potential (MEP) recordings before and after temporary clipping (6 min and 20 min after clipping) of feeding vessel to the spinal dural arteriovenous fistulas (DAVF). Amplitude is expressed in microvolts (μV), the percentage change in amplitude from baseline is expressed in the bracket APB: abductor pollicis brevis (hand muscle); EO: external oblique (abdominal muscle); AH: abductor hallucis (foot muscle); L: left; R: right

the importance of monitoring the functional integrity of the corticospinal pathway and the value of MEP as a predictor of motor recovery. The intraoperative neurophysiological monitoring (IONM) provides a potential opportunity to evaluate the hemodynamic patterns in the spinal cord and further changes in the spinal vascular flow caused by temporary and final occlusion of the spinal DAVF (9). Thus, IONM is an important technique to predict the neurological outcome. The prognostic role of MEP is well documented in the spinal cord surgery and a similar correlation may be accepted for the spinal DAVF (10, 11).

Conclusion

This case report emphasizes the role of multimodal monitoring for the spinal DAVF surgery to guide the surgeon both in terms of the surgical approach and in predicting the neurological functional outcome.

Informed Consent: Informed consent was obtained from the patient's next of kin for publication.

Peer-review: Externally peer-reviewed.

Author Contributions: Concept – K.N.G.; Design – K.N.G.; Supervision – K.N.G., S.B., N.P.; Resources – K.N.G.; Materials – K.N.G., N.P.; Data Collection and/or Processing – P.M., K.N.G.; Analysis and/or Interpretation – K.N.G., S.B.; Literature Search – K.N.G., S.B.; Writing Manuscript – K.N.G., S.B., N.P.; Critical Review – P.S., K.N.G.

Conflict of Interest: The authors have no conflicts of interest to declare.

Financial Disclosure: The authors declared that this study has received no financial support.

References

1. Fugate JE, Lanzino G, Rabinstein AA. Clinical presentation and prognostic factors of spinal dural arteriovenous fistulas: an overview. *Neurosurg Focus* 2012; 32: E17. [\[Crossref\]](#)
2. American Electroencephalographic Society guidelines for standard electrode position nomenclature. *J Clin Neurophysiol* 1991; 8: 200-2. [\[Crossref\]](#)
3. Morota N, Deletis V, Constantini S, Kofler M, Cohen H, Epstein FJ. The role of motor evoked potentials during surgery for intramedullary spinal cord tumors. *Neurosurgery* 1997; 41: 1327-36. [\[Crossref\]](#)
4. Aminoff MJ, Barnard RO, Logue V. The pathophysiology of spinal vascular malformations. *Neurol Sci* 1974; 23: 255-63. [\[Crossref\]](#)
5. Tacconi L, Lopez Izquierdo BC, Symon L. Outcome and prognostic factors in the surgical treatment of spinal dural arteriovenous fistulas. A long-term study. *British J Neurosurg* 1997; 11: 298-305. [\[Crossref\]](#)
6. Paolini S, Severino R, Cardarelli G, Missori P, Bartolo M, Esposito V. Indocyanine Green Videoangiography in the Surgical Treatment of Spinal Dural Arteriovenous Fistula: A Useful Application. *World Neurosurg* 2019; 122: 508-11. [\[Crossref\]](#)
7. Iacopino DG, Conti A, Giusa M, Cardali S, Tomasello F. Assistance of intraoperative microvascular Doppler in the surgical obliteration of spinal dural arteriovenous fistula: cases description and technical considerations. *Acta Neurochir (Wien)* 2003; 145: 133-7. [\[Crossref\]](#)
8. Ghadirpour R, Nasi D, Iaccarino C, Romano A, Motti L, Farneti M, et al. Intraoperative Neurophysiological Monitoring in Surgical Treatment of Spinal Dural Arteriovenous Fistulas: Technique and Results. *Asian J Neurosurg* 2018; 13: 595-606.
9. Sala F, Beltramello A, Gerosa M. Neuroprotective role of neurophysiological monitoring during endovascular procedures in the brain and spinal cord. *Neurophysiol Clin* 2007; 37: 415-21. [\[Crossref\]](#)
10. Ghadirpour R, Nasi D, Iaccarino C, Sabadini R, Motti L, Sala F, et al. Intraoperative neurophysiological monitoring for intradural extramedullary tumors: why not? *Clin Neurol Neurosurg* 2015; 130: 140-9. [\[Crossref\]](#)
11. Sala F, Palandri G, Basso E, Lanteri P, Deletis V, Faccicoli F, et al. Motor evoked potential monitoring improves outcome after surgery for intramedullary spinal cord tumors: a historical control study. *Neurosurgery* 2006; 58: 1129-43. [\[Crossref\]](#)