



# An Unusual Cause of Electrocardiographic Artefact: A Patient's Warming Blanket

Elektrokardiyografik Artefaktın Sıra Dışı Bir Nedeni: Isıtıcı Battaniye

Gaurav Misra <sup>1</sup>, Sanjay Dhiraaj <sup>2</sup>, Aditya Kapoor <sup>3</sup>, Puneet Goyal <sup>4</sup>  
*Sanjay Gandhi Post Graduate Institute of Medical Sciences, Lucknow, India*

**Cite this article as:** Misra G, Dhiraaj S, Kapoor A, Goyal P. An Unusual Cause of Electrocardiographic Artefact: A Patient's Warming Blanket. *Türk J Anaesthesiol Reanim* 2018; 46: 161-3.

**ORCID IDs of the authors:** G.M. 0000-0003-2989-5875; S.D. 0000-0001-7591-3013; A.K. 0000-0002-2539-2675; P.G. 0000-0003-0015-618X.

In electrocardiography, an electrocardiographic (ECG) artefact is used to indicate a misleading or confusing alteration in data or observation not arising from the heart. Although technological advancements have produced monitors that may provide accurate data and reliable heart rate alarms, interferences of the displayed electrocardiogram such as (but not limited to) electrical interference by outside sources, electrical noise from elsewhere in the body, poor contact and machine malfunction continue to occur. Artefacts are extremely common, and knowledge regarding them is necessary to prevent misinterpretation of a heart's rhythm, which can often lead to unnecessary and unwarranted diagnostic and interventional procedures. Here we report a case of ECG artefacts that occur owing to a patient's warming blanket and its consequences.

**Keywords:** ECG artefact, patient warming blanket, mobile messaging apps

Elektrokardiyografide, bir elektrokardiyografik artefakt genellikle kalpten kaynaklanmayan verilerdeki ya da gözlemlerdeki yanlış ya da yanıltıcı değişikliklerden kaynaklanır. Teknolojik gelişmelerle doğru veriler ve güvenilir kalp atım hızı uyarıları sağlayan monitörler üretilmelerine rağmen, dış kaynaklardan elektriksel müdahale, vücutun başka yerlerindeki elektriksel gürültü, zayıf temas ve makine arızası gibi (ancak sadece bunlarla sınırlı olmayan) elektrokardiyogram ile etkileşimi halen görülmektedir. Artefaktlar oldukça yaygındır ve kalp ritminin yanlış yorumlanmasının önlenmesi ve gereksiz ve sonuçsuz tanı ve girişimlerden kaçınmak için bunlarla ilgili yeterli bilgiye sahip olmak gerekmektedir. Burada bir hastanın ısıtıcı battaniden kaynaklanan EKG artefaktları ve bunların sonuçları ile ilgili bir vaka sunulmaktadır.

**Anahtar Sözcükler:** EKG artefakt, ısıtıcı battaniye, mobil mesajlaşma uygulamaları

## Introduction

The objective of electrocardiographic (ECG) monitoring is to observe and assess the electrical activity of the heart. Continuous ECG monitoring is currently a basic standard of care in both the operating room and intensive care unit. In both these environments, there have been increases in the number of electrical devices used for patient care, with a consequent increase in the risk for interference. The electrocardiogram should be of high quality and free from distortion and artefacts for its accurate interpretation.

Here we describe a rare case of a patient who developed unexplained ECG changes after inducing anaesthesia, which was later determined to occur because of electrical interference from the patient's warming blanket (Geratherm UniqueTemp Medical Warming System, Geratherm Medical AG, Geschwenda, Germany).

## Case Presentation

A 20-year-old male with a preoperative diagnosis of exstrophy–epispadias complex was posted for surgery (Mitrofanoff procedure and neobladder creation) under epidural and general anaesthesia. After inserting an epidural catheter, anaesthesia was induced using 1-2 µg kg<sup>-1</sup> fentanyl, 0.05 mg kg<sup>-1</sup> midazolam and 2.5 mg kg<sup>-1</sup> propofol, and endotracheal intubation was facilitated using 0.12 mg kg<sup>-1</sup> vecuronium. Immediately after connecting the endotracheal tube to the anaesthesia machine (Dräger Fabius GS Premium, Dräger Medical GmbH, Germany), nonspecific ECG changes were observed on the monitor (Figure 1). The patient was haemodynamically stable, with a blood pressure of 98/54 mmHg. Immediate investigation for the cause was initiated. At a first glance, the monitor strip revealed broad QR complexes (yellow arrows), suggesting a

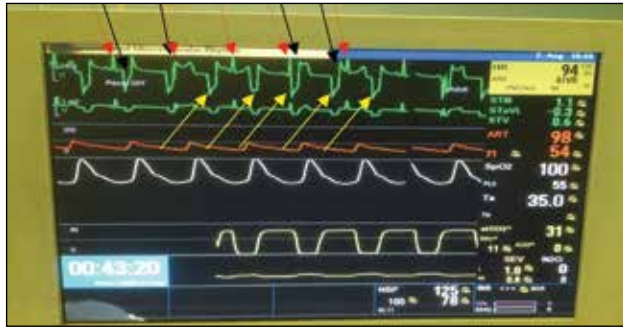


Figure 1. Monitor showing electrocardiographic artefacts



Figure 2. Patient's warming apparatus (Geratherm®)

ventricular bigeminal rhythm (1). However, a careful analysis revealed these complexes to be artefacts, which was suggested based on the following observations.

1. Clear presence of normal sinus rhythm, with narrow QRS complexes in both monitor strips (marked by red arrows in Figure 1).
2. The ventricular myocardium has a refractory period (approximately 250 ms) wherein after an action potential, the tissue remains refractory for any ensuing cardiac impulse. Thus before or after sinus beat (marked by red arrows), it would be physiologically impossible for the myocardium to be rapidly depolarised to produce a second QRS complex (marked by black arrows).
3. The QRS complexes marked by yellow arrows were confirmed to be artefacts because they appeared in too rapid succession following or preceding a normal sinus complex, which would be physiologically impossible with a normal AV conduction (Figure 1).

A diagnosis of ECG artefacts was made, and thus, we initiated investigating the possible reason for the artefacts. Meanwhile, we deepened the plane of anaesthesia, and an urgent arterial blood gas analysis was initiated to rule out any electrolyte abnormalities. The blood gas analysis results revealed normal parameters (pH, 7.364; pO<sub>2</sub>, 186.8 mmHg; pCO<sub>2</sub>, 38.0 mmHg; Na<sup>+</sup>, 138.6 mEq L<sup>-1</sup>; K<sup>+</sup>, 3.9 mEq L<sup>-1</sup>). The ECG leads were checked for any disconnections and breach, and the ECG electrodes were reapplied after proper skin cleaning (2). Even after checking and rechecking the ECG electrodes and leads, ECG on the monitor remained the same. Considering that there must be some fault with the monitor itself, a new monitor was used but the artefacts persisted. Then, 12-lead ECG was performed to verify whether the artefacts persisted in all the leads; this revealed the same rhythm as observed on the monitor for all the leads. The operation table and anaesthesia machine were checked for proper grounding, which was also found to be good (3). All other monitoring connections (e.g. invasive blood pressure line, temperature probe) that originated from the anaesthesia machine and were attached to the patients were disconnected and checked; all electronic equipment, including cell phones, were switched off to identify the cause of the ECG artefacts, but none was found (4). While we were checking, a cardiologist opinion was also sought, and a snapshot of ECG was send via WhatsApp. The communication via phone was received within minutes, and in their opinion, these were artefacts and were produced from some device that interfered with the ECG rhythm.

During this intensive search for the cause of ECG changes, when the patient's warmer (Geratherm®) (Figure 2) was turned off, the ECG reverted back to sinus rhythm, concluding that the warmer was causing the artefacts.

We encountered a similar incidence of ECG artefacts in a 7-year-old boy who was to undergo laparotomy under general anaesthesia. ECG artefacts were similar to those described above (Figure 3). We immediately diagnosed that the arte-

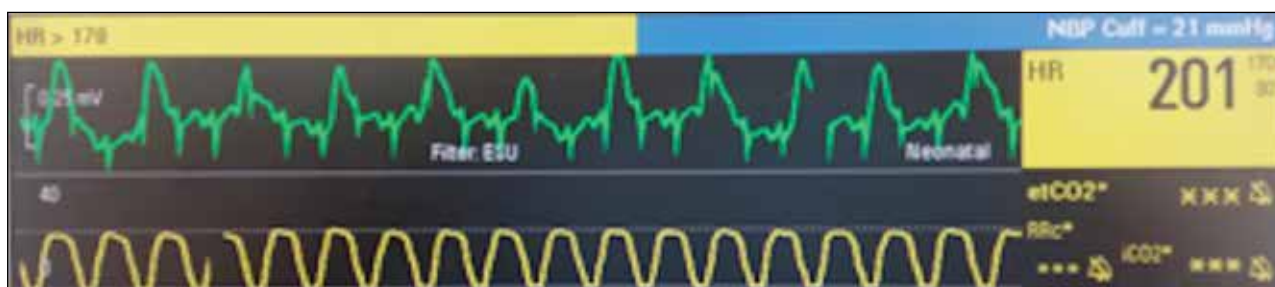


Figure 3. Monitor showing electrocardiographic artefacts

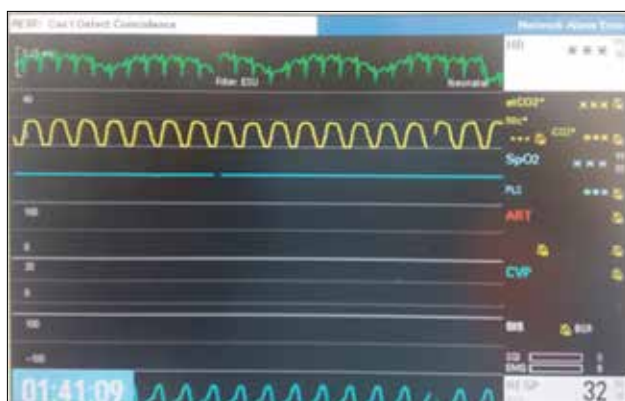


Figure 4. Monitor displaying normal sinus rhythm after switching off the warmer

facts occurred because of the warmer, and after switching off the warmer, ECG returned to sinus rhythm (Figure 4).

## Discussion

Misdiagnosis due to ECG artefacts may subject patients to unnecessary diagnostic and therapeutic interventions for arrhythmia (5). Intraoperative ECG changes need the same degree of vigilance as that in the diagnosis of a disease, which if overlooked can have serious adverse effects on patient care. However, a thorough knowledge of, patient's history, and appropriate investigation of surrounding equipment/monitors enables swift determination of the cause and appropriate action for resolving the problem.

Another point of care is the use of mobile messaging application services for quick and clear results where figures, pictures and photos play an important part in making a diagnosis. Here we were able to send the ECG snapshot via WhatsApp to a cardiologist to reach a diagnosis and confirm it without delay.

## Conclusion

Through this correspondence, we emphasize that although ECG changes require quick treatment, they may subject patients to unnecessary diagnostic and therapeutic interventions for arrhythmias if they are later identified to be artefacts. Having complete knowledge of monitoring devices attached to them can prevent this misdiagnosis. We would also like to highlight that mobile messaging services reduce time to arrive at a diagnosis and thus may be used more often for patients' benefit.

**Informed Consent:** Written informed consent was obtained from the parents of the 7 year old child and from the adult patient who participated in this case report.

**Peer-review:** Externally peer-reviewed.

**Author Contributions:** Concept – S.D., G.M.; Design – S.D., G.M.; Supervision – S.D., A.K.; Resources – S.D., G.M., P.G., A.K.; Materials – G.M., S.D., P.G., A.K.; Data Collection and/or Processing – S.D., G.M., A.K., P.G.; Analysis and/or Interpretation – S.D., A.K., P.G.; Literature Search – G.M., A.K.; Writing Manuscript – G.M., S.D., P.G., A.K.; Critical Review – S.D., P.G., A.K.

**Conflict of Interest:** No conflict of interest was declared by the authors.

**Financial Disclosure:** The authors declared that this study has received no financial support.

**Hasta Onamı:** Yazılı hasta onamı 7 yaşındaki çocuğun ebeveynlerinden ve bu olgu sunumuna katılan yetişkin hastadan alındı.

**Hakem Değerlendirmesi:** Dış bağımsız.

**Yazar Katkıları:** Fikir – S.D., G.M.; Tasarım – S.D., G.M.; Denetleme – S.D., A.K.; Kaynaklar – S.D., G.M., P.G., A.K.; Malzemeler – G.M., S.D., P.G., A.K.; Veri Toplanması ve/veya İşlenmesi – S.D., G.M., A.K., P.G.; Analiz ve/veya Yorum – S.D., A.K., P.G.; Literatür Taraması – G.M., A.K.; Yazıyı Yazan – G.M., S.D., P.G., A.K.; Eleştirel İnceleme – S.D., P.G., A.K.

**Çıkar Çatışması:** Yazarlar çıkar çatışması bildirmemişlerdir.

**Finansal Destek:** Yazarlar bu çalışma için finansal destek almadıklarını beyan etmişlerdir.

## References

1. Patel SI, Souter MJ. Equipment-related electrocardiographic artifacts causes, characteristics, consequences, and correction. *Anesthesiology* 2008; 108: 138-48. [CrossRef]
2. Takla G, Petre JH, Doyle DJ, Horibe M, Gopakumaran B. The problem of artifacts in patient monitor data during surgery: a clinical and methodological review. *Anesth Analg* 2006; 103: 1196-204. [CrossRef]
3. Gibby GL, Lizdas DE, Lampotang S. Electrical Power and Safety in the Operating Room. 2013: University of Florida, Department of Anesthesiology. Available from: <https://vam.anest.ufl.edu/simulations/orelectric.php>
4. Brande FV, Martens P. A false positive arrhythmia on electrocardiogram induced by a cell phone. *Eur J Emerg Med* 2003; 10: 357-60. [CrossRef]
5. Knight BP, Pelosi F, Michaud GF, Strickberger SA, Morady F. Clinical consequences of electrocardiographic artifact mimicking ventricular tachycardia. *N Engl J Med* 1999; 341: 1270-4. [CrossRef]